

VOIDING CYSTOURETHROGRAPHY IN FOLLOW UP OF PATIENTS WITH VUR AFTER URETERIC REIMPLANTATION IN PEDIATRICS.

Dr. Tammouz Mezhi Mohsen , Dr. Muhand Sabah Jasim and Dr. Abdul Ridha Mohammed Ali Jawad

Al-Sadiq teaching hospital, Babil Health Directorate, Hilla, Iraq. (F.I.C.M.S).

Email: tammouzurosurgery2@gmail.com

Abstract:

Background : Ureteric reimplantation is a common pediatric urological procedure . The standard procedure (politano-leadbetter) had excellent success rate. Two to six months after surgery most surgeons routinely do a voiding cystourethrogram and renal sonography to confirm the results of surgical correction of reflux and to evaluate the outcomes of operation. In our study we assess the necessity for and efficacy of voiding cystourethrogram after uncomplicated ureteral reimplantation performed for primary VUR in children.

Objectives: to evaluate the patients in our practice to determine whether post-operative voiding cystourethrogram was useful in monitoring the outcome after ureteric reimplantation.

Surgical repair of VUR is the treatment of choice after failure of medical therapy, also in high grade reflux. Radiographic evaluation by ultrasonography or VCUG is commonly used post operatively to evaluate for urinary tract obstruction or persistent reflux. However, imaging modalities are not without cost, both in monitoring term and in term of radiation exposure and trauma to the child.

Patients and method: Twenty –five patient with 35 refluxing renal unit {primary idiopathic VUR} with their age between 8 month to 12 years (mean age 4.7 y), 5 female (20%), 20 male (80%), with high grade VUR grade 4, 5 patients (20%), grade 5 reflux 20 patient (80%), all patients with primary reflux excluding secondary reflux.

These patients treated by open intravesical (politano-leadbetter) reimplantation from 2018 to 2020 in urology department at hilla teaching hospital at Babylon and followed for a minimum 1 year by VCUG and ultrasonography. VUR was unilateral in 15 patient (60%), and bilateral in 10 patients (40%).

Results: The success rate of our prospective study about (72%) of patients show no reflux (18 patients), 4 patients showed grade 1 reflux (16%), 3 patients showed ureteric obstruction (12%) during the initial post-operative follow up (first 3 months) by VCUG .

Thenduring follow up for 1 year , the success rate increase to (88%) that 22 patient showed resolution of reflux. Grade 1 reflux only in 1 patients(4%) and ureteric obstruction only 2 patients(8%),that confirmed later by IVU.

Conclusions : since the success rate of ureteric reimplantation was high when done by experience urologist ,so the role of VCUG can be omitted to only complicated cases. So that cost saving and decrease trauma to the child and risk of radiation.

Introduction:

Vesicoureteral reflux (VUR) is the retrograde flow of urine from the bladder into the upper urinary tract, vesicoureteral reflux is the most common abnormality of the urinary tract in children, affecting 1% of all children [1].

Prevalence :

It's estimated to be approximately 30% for children with UTI and 17% without infection [2]. In asymptomatic infants followed up for antenatal hydronephrosis, the prevalence of reflux ranges from 15% in infants with absent or mild hydronephrosis on postnatal ultrasound [3], to 38% in a group of neonates with various postnatal upper tract sonographic anomalies including hydronephrosis, and renal agenesis [4].

Siblings of children with VUR had a 27.4% risk of also having VUR, whereas the offspring of parents with VUR had a higher incidence reaching 35.7% [5].

Gender :

Urinary tract infections are more common in girls than boys due to anatomical differences, however, among all children with UTIs, boys are more likely to have VUR than girls (29% vs. 14%).

Boys also tend to have higher grades of VUR diagnosed at younger ages, although their VUR is more likely to resolve [6].

Boys appear to harbor postnatal reflux more commonly, a 6: 1 male-to- female ratio was reported [7].

Age:

Because the natural history of reflux involves spontaneous resolution over time, it is evident that less primary reflux would be prevalent in older children compared with infants.

Even in the presence of infection or asymptomatic bacteriuria, reflux is more common in younger patients [8].

Etiology of Vesicoureteral Reflux

In general, reflux is considered primary if the main reason for it, is a fundamental deficiency in the function of the ureterovesical junction (UVJ) antireflux mechanism, while remaining factors (bladder and ureters) remain normal or relatively noncontributory. Secondary reflux, then, implies reflux caused by overwhelming the normal function of the UVJ, bladder dysfunction of a congenital, acquired, or behavioral nature is often the main cause of secondary reflux [9].

In male, the most common anatomic obstruction of the bladder is posterior urethral valves (PUVs). Reflux is present in 48% to 70% of PUV patients [10].

In females, anatomic bladder obstruction is rare, the most common structural obstruction is from an ureterocele, which prolapses into the bladder neck [11].

Clinical Correlates:

Bladder-bowel dysfunction (BBD): Bladder-bowel dysfunction can manifest as any combination of enuresis, constipation, urinary frequency and urgency, dysuria, infrequent voiding or even encopresis.

Its presence has been seen to delay and/or decrease the rate of primary VUR resolution, incite secondary VUR and increase the rate of breakthrough UTIs [5].

Recent studies have documented BBD in more than 40% of patients with VUR [12].

Grading of Reflux:

In 1981 the International Reflux Study Committee proposed a system of five grades of reflux that remains in current use today, as shown in figure 1 and table1[1].

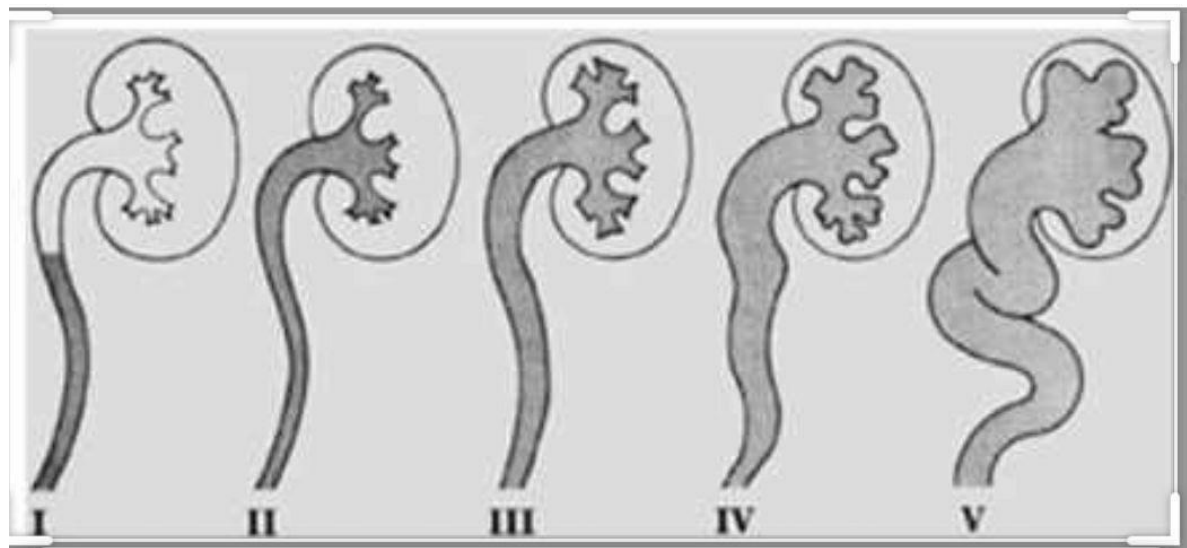


Figure 1 : International classification of vesicoureteral reflux.

Table I : International Classification of Vesicoureteral Reflux.[13]

GRADE	GRADE DESCRIPTION ACCORDING TO VCUG FINDINGS
I	Into a no dilated ureter.
II	Into the pelvis and calyces without dilatation.
III	Mild to moderate dilatation of the ureter, renal pelvis, and calyces with minimal blunting of the fornices.
IV	Moderate ureteral tortuosity and dilatation of the pelvis and calyces.

V	Gross dilatation of the ureter, pelvis, and calyces; loss of papillary impressions; and ureteral tortuosity.
---	--

Associated Anomalies and Conditions:

1. Ureteropelvic Junction Obstruction (UPJO) :

The incidence of VUR associated with UPJO ranges from 9% to 18%, conversely, the incidence of UPJO in patients with reflux ranges from 0.75% to 3.6% [26].

2. Ureteral Duplication Vesicoureteral reflux :

Is the most common abnormality associated with complete ureteral duplications. The embryologic origin of the duplicated ureter supports the observation that reflux occurs most commonly into the lower pole [27].

3. Bladder Diverticula :

Reflux associated with paraureteral diverticula resolves at rates similar to primary reflux and should be managed according to the prevailing indications for the reflux itself, irrespective of the diverticulum [28].

4. Renal Anomalies:

The cardinal renal anomalies associated with reflux are multicystic dysplastic kidney and renal agenesis, and the presence of either condition mandates a VCUG [28].

5. Megacystis- Megaureter Association:

It's more frequent in males, and the differentiation from posterior valves is crucial [29].

6. Other Anomalies These include; the VACTERL association (Vertebral, Anal, Cardiac, Tracheo- Esophageal, Renal and Limb anomalies), CHARGE syndrome, Coloboma, Heart disease, Atresia choanae, Retarded development, Genital hypoplasia, Ear anomalies and imperforate anus [30].

Diagnosis and Evaluation of VUR

Because preventable reflux nephropathy is predicated on the combined effects of UTI and reflux, confirming and documenting true UTI is paramount in the appropriate management of the patient with reflux. Although fevers are common in infants, UTI comprises only 5% of children presenting with fever [14].

Numerous factors support a search for reflux in the patient with UTI, the probability of finding VUR in children with a UTI is 29% to 50% [15].

Radiographic investigations for VUR have generally been directed to :-[16]

1. Children younger than 5 years old.
2. All children with a febrile UTI.

3. Any male with a UTI regardless of age or fever, unless sexually active.

Renal ultrasound (U/S)

The mainstay of renal imaging in VUR management is U/S. As a non-ionizing, noninvasive imaging technique, coupled with its ability to assess renal vasculature.

It is ideally suited to serial follow-up of renal growth and development. U/S has supplanted routine excretory urography as the imaging modality of choice to monitor renal status over time [17].

Cystographic Imaging

The voiding cystourethrogram (VCUG) and radionuclide cystogram (RNC) are the two common forms of direct cystography and constitute the present-day gold standard approaches to reflux detection.

More recently, to eliminate the need for ionizing radiation, some studies have demonstrated a growing interest in sonographic detection of reflux using either color Doppler imaging [18], or echo-enhancing contrast agents [19].

Direct imaging of reflux is affected by several parameters, these include [16]:

1. Bladder contraction during voiding.
2. The fluid volume instilled into the bladder.
3. Presence of infection and therefore inflammation of the UVJ mucosa.

More importantly, even during voiding, reflux may not be demonstrated on a single filling-voiding cycle.

Several studies have demonstrated a roughly 12% to 20% greater detection rate for VUR if a cyclic study is performed [20]. A cyclic VCUG involves a second or third cycle of bladder filling and emptying under fluoroscopic observation. A similar cyclic strategy is commonly employed for the RNC as well [21].

Renal Scintigraphy

The gold standard for imaging functioning renal parenchyma is scintigraphy using ^{99m}Tc-labeled DMSA. The radiotracer is taken up only by functioning proximal tubular tissue mass, where it binds for several hours.

The uptake of DMSA provides a good proportional representation of glomerular filtration [2].

Cystoscopy and the Positioning of the Installation of Contrast (PIC) Cystogram

Modern management of reflux does not include routine cystoscopy.

It's rare for cystoscopy to add any information that will alter management of a patient with reflux, either at the time of initial diagnosis or during follow-up [23].

A recently developed, although still controversial [24], cystoscopic modality termed the PIC technique (Positioning of the Instillation of Contrast at the ureteric orifices)

purports to detect occult reflux under general anesthesia in patients with a history of febrile UTIs but a normal VCUG[25].

Management

The spontaneous resolution of VUR is dependent on age at presentation, sex, grade, laterality, mode of clinical presentation, and anatomy; faster resolution of VUR is more likely in children who are aged <1 yr.

at presentation, have a lower grade of reflux (grade I–III), and have an asymptomatic presentation with prenatal hydronephrosis or sibling reflux[31]. Spontaneous resolution is nearly 80% in VUR grade I–II and 30–50% in VUR grade III–V within 4–5 yr of follow-up [32].

Surgical treatment (open or endoscopic) can be considered in the presence of breakthrough urinary infections or non-compliance while on antibiotic prophylaxis, presence or development of new renal scars or persistent reflux after several years of follow up , or based on parents preference[33].

A.Conservative therapy

Includes: watchful waiting, continuous antibiotic prophylaxis (CAP), and bladder rehabilitation in patients with LUTD [34]. Circumcision during early infancy may be considered part of the conservative approach because the procedure has been shown to be effective in reducing the risk of infection in normal children [35].

The most frequently used agents for CAP are single low doses (one-third of the treatment dose) of amoxicillin and trimethoprim (patients aged <2 mo) or trimethoprim-sulfamethoxazole or nitrofurantoin (for older infants), preferably taken at bedtime [36].

B. Surgical Management Include

endoscopic injection therapy, ureteral reimplantation (open or laparoscopic).

Endoscopic Treatment of VUR

Matouschek (1981) first described the injection of polytetrafluoroethylene (PTFE) paste at the ureteral orifice to correct VUR [37].

O'Donnell and puri (1986)popularized the technique when they published their initial report on the successful endoscopic correction of primary VUR with a success rate of 75% after one injection [38].

The overall success rates which were reported by the different groups ranged between 68–92%, depending mainly on the VUR grade [39-41].

Materials Used for Endoscopic Correction of Reflux:

A. Non- autologous materials:

1. Polytetrafluoroethylene Paste (Teflon Paste)

The numerous reports of PTFE migration to remote areas such as the brain and lungs following injection in the urethra and bladder neck sealed the fate of PTFE therapy

[42, 43]. In addition to the risk of migration, there was concern over the development of granulomatous reaction around the PTFE, leading to possible calcification and making subsequent reimplant surgery difficult [44].

2. Polydimethylsiloxane (Macroplastique)

Was a very effective agent when used with the STING procedure, correcting reflux in over 80% of ureters, with little morbidity. Unfortunately, silicone can cause a local foreign body reaction, and on the basis of the variable size of its particulates (35–540 μm), has a theoretical potential for migration risk. Also the difficulty in injecting the viscous solution made the procedure less desirable. Finally, Macroplastique came to light at a time of great concern over systemic collagen disorders arising from silicone implants, and the material never achieved popular use [45].

3. Cross-Linked Bovine Collagen

Apart from concerns regarding allergy to bovine collagen in 3% of the population, this material is otherwise safe and causes minimal local inflammatory changes [46]. Despite the odd report of sustained effect [47], the inconsistency, and questionable durability of cross-linked collagen [48], most centers have abandoned its use for correction of reflux .

4. Coaptite

Calcium hydroxyl apatite is synthetic bone material. The particles have a uniform spherical shape and range in size from 75 to 125 μm . Reflux resolved in 67% of the patients with this material. There are no published reports at this point, and the FDA is currently evaluating the clinical trials [49].

5. Dextranomer/Hyaluronic acid copolymer (Deflux)

Dextranomer/Hyaluronic acid copolymer (Dx/HA) is formed of cross-linked dextranomer microspheres (80 to 250 μm in diameter) suspended in a carrier gel of stabilized sodium hyaluronate.

Dx/HA is biodegradable, the carrier gel is reabsorbed, and the dextranomer microspheres capsulated by fibroblast migration and collagen ingrowth, Dx/HA loses about 23% of its volume beyond 3 months of follow-up, it was first introduced by the Swedish group of Stenberg and Lackgren (1995), and received FDA approval in 2001[50].

Since then there have been several clinical reports from Europe and the United States documenting success rates ranging from 68% to 89% [39, 40, 51].

One vial of Dx/HA (1 ml) contains 50 mg dextranomer microspheres and 17 mg hyaluronic acid.

6. Polyacrylate polyalcohol copolymer (Vantris)

Non-biodegradable agents of synthetic origin lead to the formation of a fibrotic capsule, giving stability and permanence, it belongs to the family of acrylics: particles of polyacrylate polyalcohol copolymer immersed in a glycerol and physiological solution carrier. The average particle size is 320 μm . Once implanted, particles are covered by a fibrotic capsule of up to 70 microns [52].

B. Autologous materials

Fat, collagen, muscle, and chondrocytes have all been evaluated as bulking agents. The key advantage of these agents is that they are not foreign materials, but the obvious disadvantage is the observed volume loss up to 100% in the case of fat [53]

Follow-Up

The child is maintained on antibiotics for 3 months when a follow-up ultrasound and VCUG are obtained. If reflux is persistent, a repeat injection can be considered 6 months after the initial injection.

If there is still no resolution, then open surgery is recommended.

Most reports to date have not indicated any additional difficulty with open surgery following endoscopic correction using Dx/HA [51].

Recurrence of Vesicoureteral Reflux Following Endoscopic Correction

A 5% recurrence rate using Teflon paste with follow-up up to 17 years [41].

A 13% recurrence rate with Dx/HA is reported 2 to 5 years after an initial negative VCUG [51].

Ureteral reimplantation

A. Open reimplantation:

All open techniques share the basic principle of lengthening the intramural part of the ureter by submucosal embedding of the ureter.

All the techniques have been shown to be safe, with a low rate of complications and excellent success rates (92–98%) [54].

The most popular and reliable open procedure is the Cohen cross-trigonal reimplantation, the main concern with this procedure is the difficulty of accessing the ureters endoscopically if needed when the child is older. Alternatives are suprahiatal reimplantation (Politano-Leadbetter technique) and infrahiatal reimplantation (Glenn-Anderson technique). If an extravesical procedure (Lich-Gregoir technique) is planned, cystoscopy should be performed preoperatively to assess the bladder mucosa and the position and configuration of the ureteral orifices.

In patients with bilateral reflux, an intravesical antireflux procedure may be considered, because simultaneous bilateral extravesical reflux repair carries an increased risk of temporary postoperative urine retention [55]

Postoperative Evaluation after open reimplantation

Most agree that an ultrasound is necessary at 6 to 12 weeks postoperatively, it may be reasonable not to perform a postoperative VCUG study unless the child has a dysfunctional bladder or develops postoperative hydronephrosis or UTIs [56].

B. Laparoscopic reimplantation:

Laparoscopic approaches are more invasive than endoscopic correction, and the advantages over open surgery are still debated.

Therefore, at present, a laparoscopic approach cannot be recommended as a routine procedure.

It can be offered to parents as an alternative in centers with sufficient experience [57]

PATIENTS AND METHODS

Since January 2018 to January 2020 a total number of children with primary high grade VUR were enrolled in this prospective cohort study and surgically treated by open intravesical {lead-better-politano} reimplantation in urological department at Hilla teaching hospital at Babylon city, their age between {8month-12years} and their data analysed on sex reflux grade and laterality.

All patients were confirmed by history with having had at least one confirmed febrile urinary tract infections with culture and sensitivity, then ultrasonography to assess the degree of dilatation of ureters and pelvicalyceal system and corticomedullary differentiation of the kidneys, then the diagnosis was confirmed by VCUG after treatment of urinary tract infection. Treatment of UTI was started according to culture and sensitivity.

The radiological grading of VUR was done according to the international system introduced by international reflux study committee in 1981 (13).

Most of the patient underwent excretory urography especially if the VCUG not informative (bad technique) and for patient who not underwent radioisotope study to assess the relative function of the kidney, otherwise some of them we do radioisotope study (but we did not mention it statically because not done for all because was not available or because it costly).

Inclusions criteria:-

- 1) pediatric below 12 years old.
- 2) all patients with primary idiopathic VUR.
- 3) high grade reflux (grade 4&5).

Exclusions criteria:-

- 1) secondary causes of VUR like (posterior urethral valve, neuropathic bladder, refluxing mega ureter)
- 2) low grade reflux (1&2&3).

The indications of surgery were break through febrile UTI while on antibiotics, decline in renal function, parents preference after explanations of all treatment options.

*Essential Steps of intravesical (politano-leadbetter) ureteric reimplantation:-

Fill the bladder through a urethral catheter.

Expose the bladder through a small transverse abdominal incision, sweep the peritoneum superiorly and do release of the ureter extaperitoneally and ureterolysis to release any kinking in the ureter, then make a vertical anterior cystotomy.

Position a self-retaining retractor to facilitate exposure of the ureteral orifices.

Pass a 5 Fr infant feeding tube into the ureter and secure it at the ureteral orifice with a purse-string suture.

Circumscribe the ureteral orifice and adequately mobilize it preserving the vascular ureteral adventitia.

Make a new hiatus approximately 2.5 cm cephalad and medial to the native ureteral orifice, and close the bladder muscle behind the original hiatus.

Create a submucosal tunnel from the neoureteral hiatus to the native ureteral orifice and carefully pull the ureter through this, without tension. The ratio of tunnel length to ureteral width should be 5 : 1.

Confirm that the ureter lies appropriately within the newly created submucosal tunnel and check for ureteral obstruction or kinking.

Create a spatulated ureterovesical anastomosis with absorbable interrupted sutures and insert double j stent in the ureter

10) Close the proximal mucosal incision, avoiding injury to the underlying ureter.

11) Close the bladder in two layers.

12) Place a drain in the pelvis.

Optical magnification, using surgical loupes, can be used to enhance visualization.

Care must be taken not to injure the bowel, vas deferens, vagina during the procedure.

Operative technique

The patient was brought onto the operating room table, positioned supine, with the hips abducted, and secured with a safety strap.

All pressure points were carefully padded.

After the administration of intravenous antibiotics and general anesthesia, the lower abdomen and external genitalia were prepped and draped in the standard sterile manner. A time-out was completed, verifying the correct patient, procedure, site, and positioning, prior to beginning the procedure.

Urethral catheter was inserted into the bladder, filled with sterile normal saline and clamped. [Note: Bladder volume in children (cc) = (age + 2) × 30].

A small semilunar transverse incision was made along Langer's lines one fingerbreadth above the symphysis pubis and carried down to the rectus abdominis aponeurosis. This was incised in a semilunar arc using electrocautery, avoiding the inguinal canals. The rectus abdominis muscles were separated at the midline and retracted laterally, taking care not to injure the underlying inferior epigastric vessels. The

anterior bladder wall and vesical neck were exposed and the peritoneum was swept cephalad. A self-retaining retractor was appropriately positioned to optimize exposure.

The urethral catheter was removed.

An additional figure-of-eight 3-0 chromic suture was placed at the apex to avoid caudal extension of the incision. Identify the ureteral orifices, The right/left ureteral orifice was identified and easily cannulated with a 5 Fr infant feeding tube, which was secured to the adjacent ureteral wall with a purse-string 4-0 polyglactin (Vicryl) traction suture.

Using gentle traction on the infant feeding tube, the ureteral orifice was elevated and circumscribed with a hooked blade/electrocautery. Tenotomy scissors were used to sharply dissect the inferior aspect of the ureter and completely liberate it from the detrusor in a circumferential fashion.

The peritoneum was swept from the posterior bladder wall under direct vision using a fine gauze dissector. Throughout the dissection, care was taken to preserve the ureteral adventitia and to avoid any injury to the ureter. A blunt right-angle clamp was passed posteriorly through the hiatus tenting an area of bladder muscle and mucosa approximately 2.5 cm cephalad and medial to the native ureteral orifice. The tented area was sharply incised over the points of the right-angle clamp. A second right-angle clamp was passed inside-out of the neoureteral hiatus to grasp the ureteral traction suture and bring it into the bladder. A 2–3 mm incision was made in the inferior aspect of the neoureteral hiatus to eliminate any ureteral angulation. The bladder muscle behind the original hiatus was closed with 4-0 interrupted Vicryl sutures.

A submucosal tunnel was created from the new to the native ureteral orifice using sharp and blunt dissection. The ureteral infant feeding tube was removed and the ureter was pulled, via its traction suture, through the submucosal tunnel and positioned without tension comfortably within the tunnel. The ureter was spatulated ventrally and the edges trimmed to ensure an intact blood supply. Dorsally, the ureter was anchored to the trigone muscle and vesical mucosa using interrupted 5-0 Vicryl sutures. The ureterovesical anastomosis was completed with similar sutures placed at the 9, 12, and 3 o'clock positions as shown in figure 1.

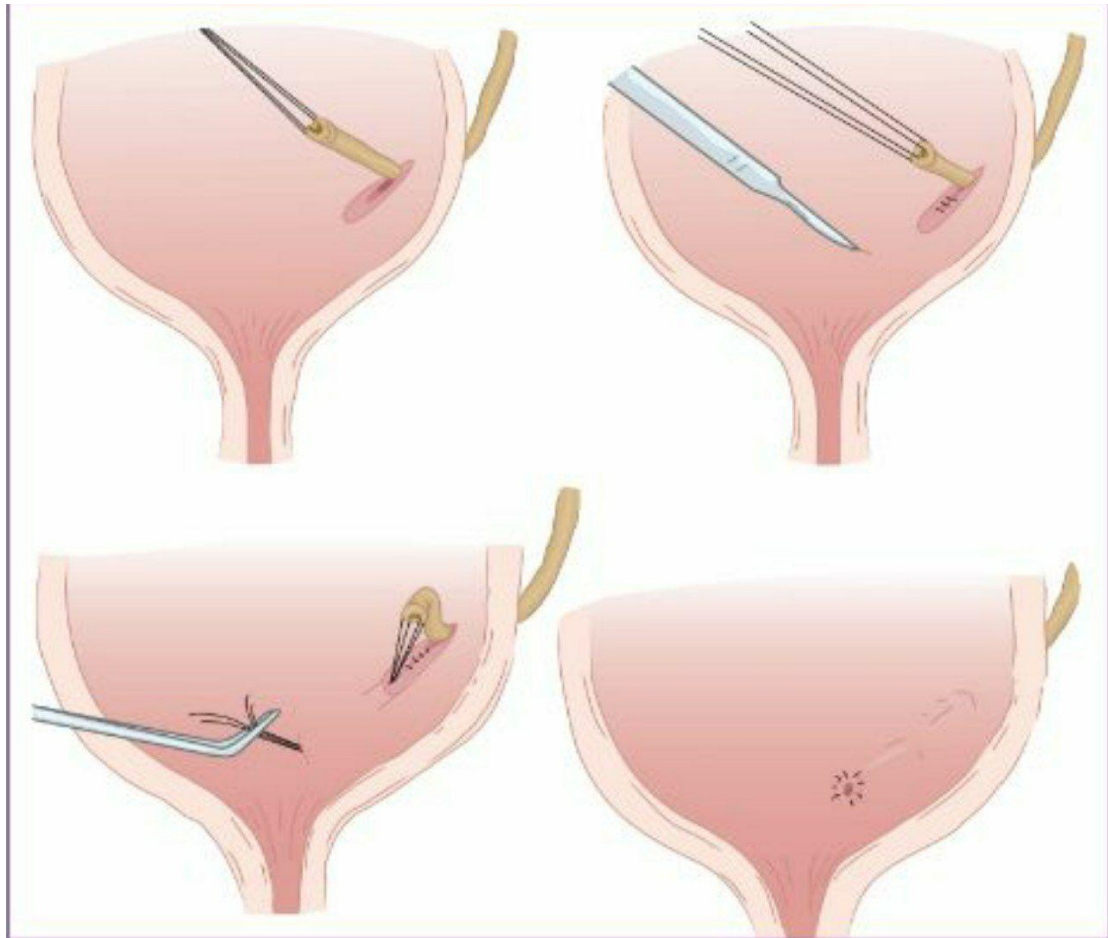
Urinary efflux was observed from the neoureteral orifice, which was then intubated with the double j stent confirming the absence of ureteral obstruction or kinking, and the feeding tube was removed.

The proximal bladder mucosal incision was closed with interrupted 4-0 Vicryl suture avoiding the underlying ureter. Meticulous hemostasis was achieved throughout the procedure with electrocautery.

For bilateral ureteral reimplantation:

The identical procedure was performed on the contralateral side. Upon completion of the reconstructive urethral catheter was placed into the bladder and connected to a drainage bag. The midline cystotomy was closed in two layers using a running 4-0 chromic and interrupted 4-0 Vicryl sutures for the mucosal and muscularis layers, respectively. A watertight bladder closure was confirmed by irrigating the urethral catheter with sterile normal saline.

A surgical drain was placed in the space of Retzius away from the cystotomy. The drain was brought out through a separate cutaneous incision and secured at the skin with a 3-0 silk suture. The self-retaining ring retractor was removed and the pelvis irrigated with sterile normal saline. The abdominal incision was closed using a running 3-0 chromic suture to approximate the rectus muscles and 3-0 polydioxanone (PDS) suture for the rectus aponeurosis. 3-0 chromic sutures were used on Scarpa's fascia and the skin approximated with a subcuticular 5-0 (vicryl) suture. A sterile dressing was applied. (58)



Figure(1)politano-leadbetter.An example of an intravesical ureteral reimplantation, which restores the normal anatomic vesicoureteral junction and antireflux valve mechanism

FOLLOW UP

An abdominal ultrasound was performed six weeks after surgery and then at third, sixth and twelfth month post operatively to assess the degree of hydronephrosis.

all patient underwent VCUG after 3month post operatively [we remove JJ stent after 6 to 8 weeks after surgery then VCUG done three month after surgery] in order to assess the success of operation.the.second VCUG was done after six months from the initial VCUG and if the patient develops recurrent febrile infection.all patients has been followed for a minimum of 12 months.

Results:

Prospective cohort study of 25 children their age range from [8month-12 years] mean age (4.7year), distribution according to gender are females[5 patients] 20% while males 80% of samples as show in fig 1.

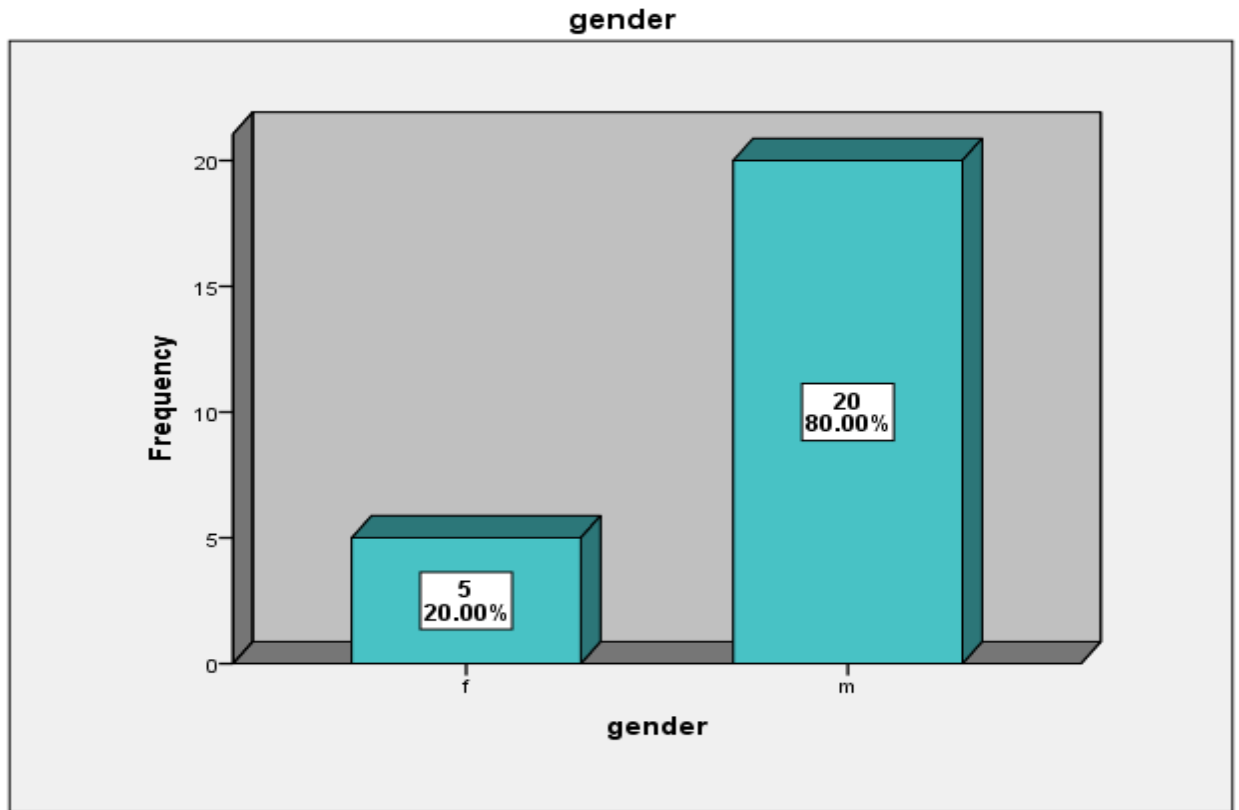


Fig (1): Distribution According To Gender.

In current study, the distribution according to laterality of reflux are: 10 patients[40%] of children with bilateral VUR,9 patients 36% of them with unilateral left ureter reflux and 6 patients 24% of patient with unilateral right ureter reflux as show in fig (2).

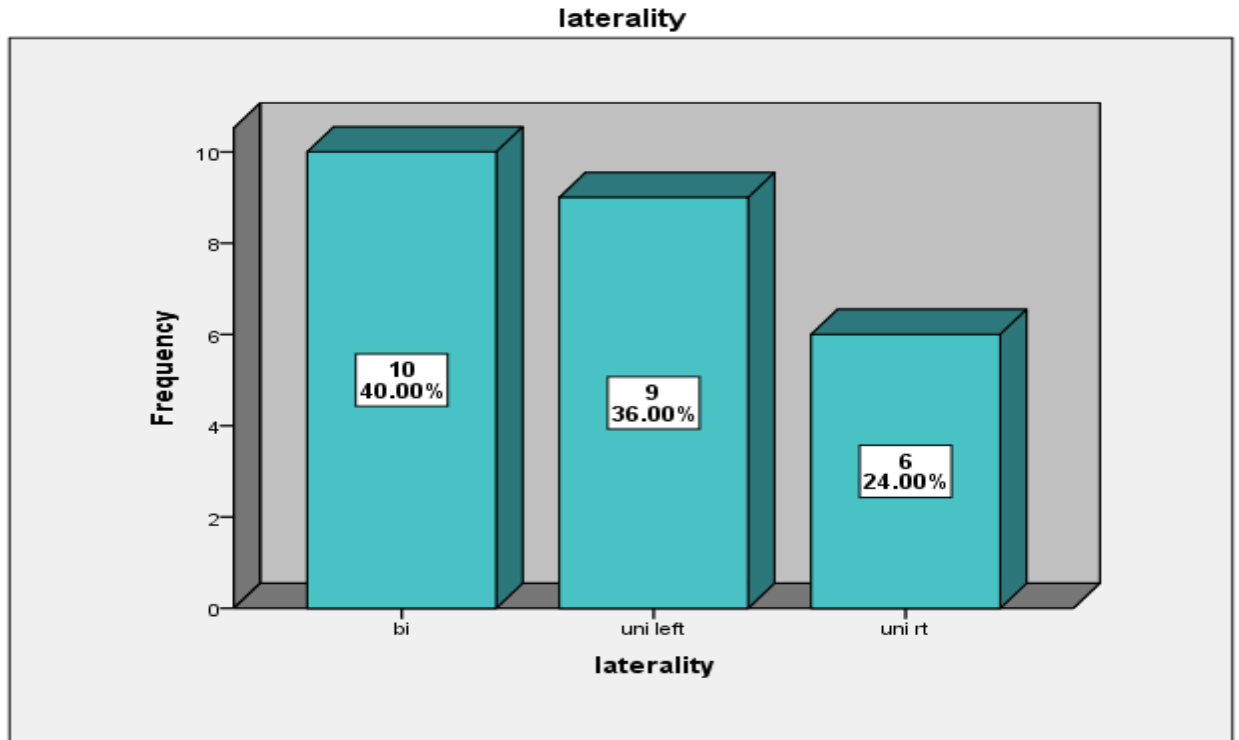


Fig (2): Distribution According To Laterality Of Reflux.

In our study, after all patients undergo surgery the complications that appear are: 4 patients 16% grade one reflex, 3 patients 12% have ureteric obstruction. However, from results of current study show that 72% of patients showed resolution of reflux without any complication as in fig (3).

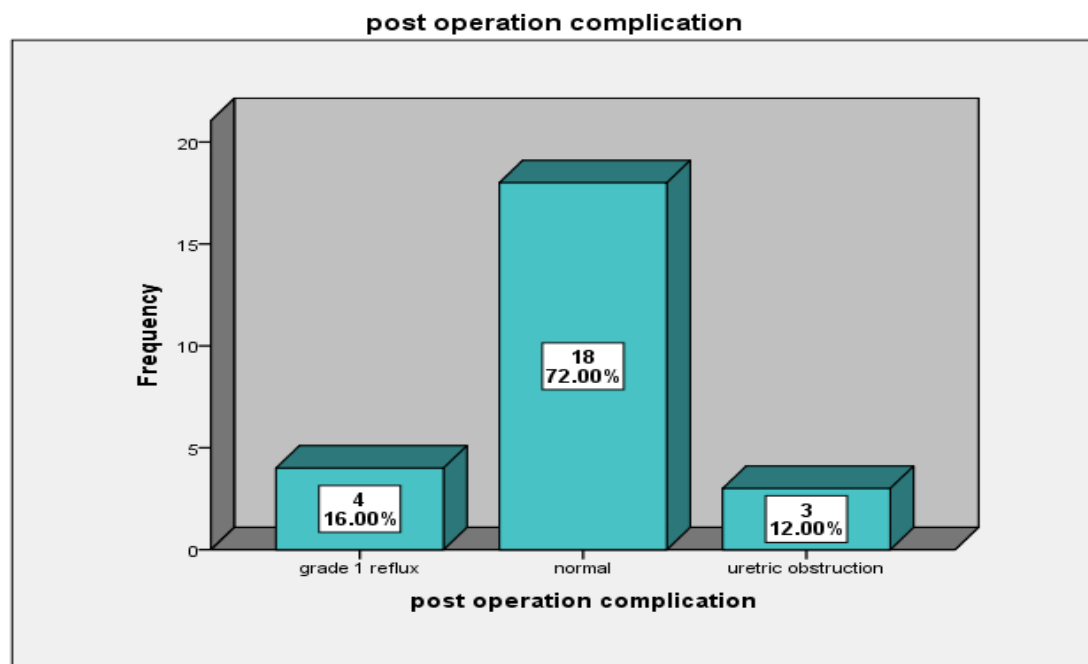


Fig (3): Distribution Of Complications After Surgery

According to fig (4): the distribute of grades of VUR are 80% of babies with grade 5 and 20% of them grade 4 .

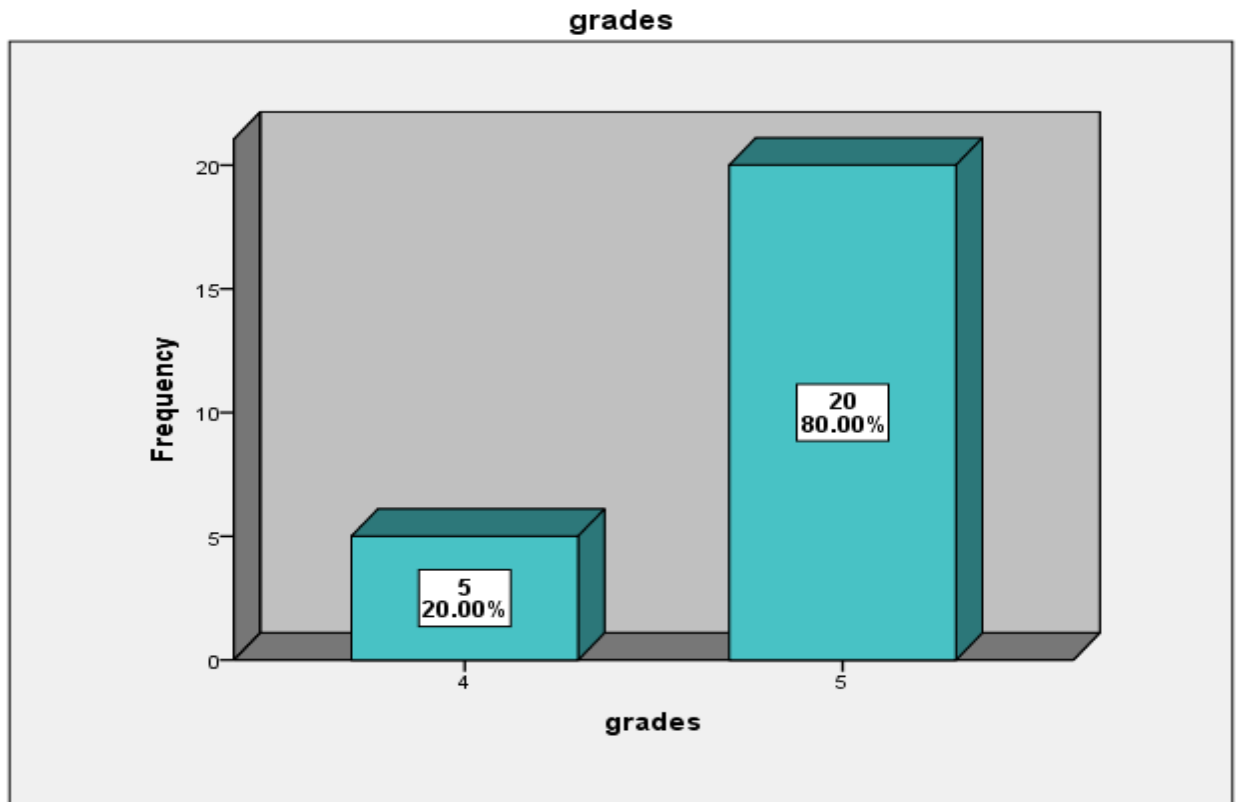


Fig (4): The Distribute Of Grades Of Vur.

According to table (1), the successes rate after operation according to grade of VUR as the following; 100% of patients with grade 4 show no reflux without any complication after operation. While 65% of patients with grade 5 show no reflux without any complication after operation. So overall Successes rate 72% of all patients in both grades of VUR that show resolution of reflux after operation. While 20% of patients in grade 5 complicated by grade 1 reflux and 15% of patients in grade 5 complicated by ureteric obstruction after operation.

Table 1: the successes rate after operation according to grade of VUR.

		post operation complication			
		grade 1 reflux	No reflux	ureteric obstruction	
grades	4	Count	0	5	0
		%	0.0%	100.0%	0.0%
	5	Count	4	13	3
		%	20.0%	65.0%	15.0%
Total		Count	4	18	3
		%	16.0%	72.0%	12.0%

According to table (2), the successes rate after operation according to laterality as the following; 80% of patients with bilateral ureteric reflux show no reflux without any complication after operation. In addition, 78% of babies with unilateral left ureter reflux show no reflux without any complication after operation. While 50% of babies with unilateral right ureteric reflux show no reflux without any complication after operation. So overall Successes rate 72% of all patients in all laterality types show no reflux after operation.

Table (2): the successes rate after operation according to laterality.

			post operation complication		
			grade 1 reflux	No reflux	ureteric obstruction
laterality	bilateral	Count	2	8	0
		%	20.0%	80.0%	0.0%
	Unilateral left	Count	1	7	1
		%	11.1%	77.8%	11.1%
	Unilateral right	Count	1	3	2
		%	16.7%	50.0%	33.3%
Total		Count	4	18	3
		%	16.0%	72.0%	12.0%

According to table (3), the successes rate after operation according to gender of babies as the following; 100% of female patients show no reflux without any complication after operation. In addition, 65% of males patients show no reflux without any complication after operation. While 20% of males complicated by grade 1 reflux 15% of male complicated by uretric obstruction. So overall Successes rate 72% of all patients in both gender show no reflux after operation.

Table (3): the successes rate after operation according to gender of patient.

			post operation complication		
			grade 1 reflux	No reflux	ureteric obstruction
gender	fema le	Count	0	5	0
		%	0.0%	100.0%	0.0%
	male	Count	4	13	3
		%	20.0%	65.0%	15.0%
Total		Count	4	18	3
		%	16.0%	72.0%	12.0%

The result of our study after period of follow up about 1 year showed that increase the success rate to(88%), with patients with grade 1 refux only (4%),and those with ureteric obstruction only (8%).as mentioned in tabe(4)

TABLE (4) Final results after follow up

	Frequenc y	Valid Percent
No.of Grade 1 reflux	1	4.0

	No.of uretric obstruction	2	8.0
	No reflux	22	88.0
	Total	25	100.0

DISCUSSION :

VUR is a common entity and many treatment options are exist,the main goal of treatment of VUR is to prevent febrile UTI and preserve renal function. Although spontaneuos resolution in primary reflux is common,surgical interventionmay be needed in patients with persistent reflux ,breakthrough UTI or renal scarring(1).

Previously,long term administration of antibiotics as prophylaxis for UTI has been advocated as preferred treatment option forVUR in children(59).

Schwab and colleagues determinedthe resolution rateof patients with VURon observation therapy,they found that reflux grade 1-3 resolved at rate of 13% yearly during the subsequent 5 years of follow up,reflux grade 4 and 5 resolved at rate of 5% yearly,bilateral reflux resolved more slowly than unilateral reflux,and it resolved more rapidly in boys than in girls(60).

Inour study 25 patients with high grade VUR (4 and 5) ,35 refluxing renal units underwent open intravesical uretric reimplantaion(politano-leadbetter)and the success was defined as resolution of VUR on post operative ultrasonography and VCUG performed 3 months after operation.

The number of patients enrolled in this research showed success rate about(72%) initially. during the period of follow up fora minimum of one year we founded that the success rate of our operation increase to(88%) when performing

asecond VCUG.

We compare the success rate of our study with different series of study, we founded that our success rate was comparable to different series of research that used the same or different surgical procedures of ureteric reimplantaion.

Recent meta-analysis about 245 patients with high grade VUR enrolled in this study the percentage of male was (27.2%) and female (72.8%),regarding the grade of VUR in this study grade 3 reflux about (38.7%) and grade 4 reflux about(45.5%)and grade 5 reflux about (15.8%) regarding the laterality about (70%) of them had unilateral reflux and (30%) had bilateral reflux.

All these patients underwent ureteric reimplantaion(politano-leadbetter) and the success rate of operation initially without any complications about(90%).

Ureteric obstruction 3 patients and persistent of reflux in 4 patients some of them required reoperation and and some resolved spontaneously durinthe period of follow up in this study the author recommended that post operative VCUG performed only in complicated cases without need for doing routine post operative VCUG.(61).

Another study performed for 119 patient with high grade primary VUR with total number of male(23) and female(96) aged from 2 months to 15 years, bilateral reflux in(88) patients and unilateral reflux in (31) patients, all of them high grade reflux (4 and 5).after doing Cohen ureteric reimplantation ,VCUG and ultrasound done 2-3 month post operatively. The success rate founded in 115 patients(96%) without any complications,in 2 of 88 patients who underwent bilateral reimplantation persistent reflux of low grade 1 unilateral and 1 bilateral,on subsequent voiding cystourethrography reflux in these patients resolved spontaneously by 2 years after surgery.

So the author in this study recommended that the need for VCUG after operation only in complicated cases and in circumstances such as excess parental anxiety,incompletely controlled voiding dysfunction or intraoperative finding of unexpectedly thick walled bladder cause us to perform a post operative VCUG even when reimplantation was otherwise uncomplicated.(62).

Different study performed for children with VUR about 438 patients 326 girls and 112 boys (mean age at surgery 6 years). All patients underwent non refluxing extravesical reimplantation . The procedure done unilaterally in 153 and bilaterally in 258 cases(total 723 refluxing renal units). Reflux was low grade (1 -3)in 509 ureters and high grade(4 and 5). Overall success rate at 3 and 12 month postoperatively was 93% and 96% respectively.

At 3 month postoperatively perform VCUG,there was 49 ureters still had persistent reflux.

At 12 months postoperatively reflux resolved in 28 ureters and persisting in 28 patients mainly in those with high grade reflux preoperatively,but downgrading of reflux was founded.

Ureteric obstruction at 3 month postoperatively in 6 ureters with persistent hydronephrosis but low grade and transient that resolved near totally at 12 month. So, they concluded that success rate of uncomplicated ureteral reimplantation very high and therefore,the yield of postoperative VCUG was exceedingly low.

Limiting these study could help reduce patient discomfort and have substantial economic benefit.(63).

So when compare our study with different series of study that we founded comparable success rate but we use smaller number of patients and with limited duration of follow up

Conclusions:

Since the success rate of uncomplicated open ureteric reimplantation performed by experienced urologist was very high we suggest that no need to test routinely for post operative reflux by voiding cystourethrography .

considerable cost saving would result by omitting the post operative VCUG many children would be satisfied with 1 less invasive test , also decrease risk of radiation exposure and child anxiety especially for those with normal ultrasound.

if pyelonephritis develops after surgery voiding cysturethrography should be performed to exclude persistent reflux.

Recommendations:

We recommending to prolong the duration of follow up after urteric reimplantation because resolution of reflux increase with time after surgery,also recommending to not routinely use voiding cystourthrography after surgery as cost benefit and less radiation exposure and less child tauma.the role of VCUG only in complicated cases with recurrent febrile urinary tract infection that suggest persistent reflux.

REFERENCES

1. Jacobson SH, Hansson S, Jakobsson B. Vesico-ureteric reflux: occurrence and long-term risks. *Acta Paediatr.* 1999;88(suppl):22–30.
2. Baker R, Maxted W, Maylath J: Relation of age, sex, and infection to reflux: data indicating high spontaneous cure rate in pediatric patients. *J Urol.* 95:27 1966 PMID: [21275189](#).
3. Phan V, Traubici J, Hershenfield B, et al.: Vesicoureteral reflux in infants with isolated antenatal hydronephrosis (see comment). *Pediatr Nephrol.* 18:1224-1228 2003 PMID: [14586679](#).
4. Zerlin JM, Ritchey ML, Chang AC: Incidental vesicoureteral reflux in neonates with antenatally detected hydronephrosis and other renal abnormalities. *Radiology.*187:157-160 1993 PMID: [8451404](#).
5. Skoog SJ, Peters CA, Arant BS Jr, et al. Pediatric Vesicoureteral Reflux Guidelines.Panel Summary Report: Clinical Practice Guidelines for Screening Siblings of Children With Vesicoureteral Reflux and Neonates/Infants With Prenatal Hydronephrosis. *J Urol* 2010 Sep;184(3):1145-51.<http://www.ncbi.nlm.nih.gov/pubmed/20650494>.
6. Alsaywid BS, Saleh H, Deshpande A, et al. High grade primary vesicoureteral reflux in boys: longterm results of a prospective cohort study. *J Urol* 2010 Oct;184(4 Suppl):1598-603.
7. Marra G, Barbieri G, Dell’Agnola CA, et al.: Congenital renal damage associated with primary vesicoureteral reflux detected prenatally in male infants. *J Pediatr.* 124:726-730 1994.

8. Smellie JM: Reflections on 30 years of treating children with urinary tract infections. *J Urol.* 146:665-668 1991.
9. Antoine E. khoury, Darius J. Bagli; Vesicoureteral Reflux; In, Campbell-Walsh Urology; 10th edition ; Alan J. Wein, Louis R. Kavoussi, Andrew C. Novick, Alan W. Partin, Craig A. Peters (eds); chapter 122; pp3271; Philadelphia, Saunders; 2012.
10. Priti K, Rao KLN, Menon P, et al.: Posterior urethral valves: incidence and progress of vesicoureteric reflux after primary fulguration. *Pediatr Surg Int.* 20:136-139 2004.
11. Merlini E, Lelli Chiesa P: Obstructive ureterocele: an ongoing challenge. *World J Urol.* 22:107-114 2004.
12. Ural Z, Ulman I and Avanoğlu A: Bladder dynamics and vesicoureteral reflux: factors associated with idiopathic lower urinary tract dysfunction in children. *J Urol* 2008; 179: 1564.
13. Lebowitz RL, Olbing H, Parkkulainen KV, et al.: International system of radiographic grading of vesicoureteric reflux. International Reflux Study in Children. *Pediatr Radiol.* 15:105-109 1985.
14. Hoberman A, Wald E: Urinary tract infections in young febrile children. *Pediatr Infect Dis J.* 16:11-17 1997.
15. Anonymous: Medical versus surgical treatment of primary vesicoureteral reflux: a prospective international reflux study in children. *J Urol.* 125:277-283 1981.
16. Antoine E. khoury, Darius J. Bagli; Vesicoureteral Reflux; In, Campbell-Walsh Urology; 10th edition ; Alan J. Wein, Louis R. Kavoussi, Andrew C. Novick, Alan W. Partin, Craig A. Peters (eds); chapter 122; pp3275; Philadelphia, Saunders; 2012.
17. Antoine E. khoury, Darius J. Bagli; Vesicoureteral Reflux; In, Campbell-Walsh Urology; 10th edition ; Alan J. Wein, Louis R. Kavoussi, Andrew C. Novick, Alan W. Partin, Craig A. Peters (eds); chapter 122; pp3278; Philadelphia, Saunders; 2012.
18. Galia M, Midiri M, Pennisi F, et al.: Vesicoureteral reflux in young patients: comparison of voiding color Doppler US with echo enhancement versus voiding cystourethrography for diagnosis or exclusion. *Abdom Imaging.* 29:303-308 2004.

19. Darge K, Moeller RT, Trusen A, et al.: Diagnosis of vesicoureteric reflux with low-dose contrast-enhanced harmonic ultrasound imaging. *Pediatr Radiol.*35:73-78 2005.
20. Novljan G, Kenig A, Rus R, et al.: Cyclic voiding urosonography in detecting vesicoureteral reflux in children. *Pediatr Nephrol.* 18:992-995 2003.
21. Fettich JJ, Kenda RB: Cyclic direct radionuclide voiding cystography: increasing reliability in detecting vesicoureteral reflux in children. *Pediatr Radiol.*22:337-338 1992.
22. Taylor A Jr: Quantitation of renal function with static imaging agents. *Semin Nucl Med.* 12:330-344 1982.
23. Antoine E. khoury, Darius J. Bagli; Vesicoureteral Reflux; In, Campbell-Walsh Urology; 10th edition ; Alan J. Wein, Louis R. Kavoussi, Andrew C. Novick, Alan W. Partin, Craig A. Peters (eds); chapter 122; pp3277; Philadelphia, Saunders; 2012.
24. Elder JS: Imaging for vesicoureteral reflux—is there a better way?. *J Urol.* 174:7-8 2005.
25. Edmondson JD, Maizels M, Alpert SA, et al.: Multi-institutional experience with PIC cystography—incidence of occult vesicoureteral reflux in children with febrile urinary tract infections. *Urology.* 67:608-611 2006 PMID [16527587](#).
26. Bomalaski MD, Hirschl RB, Bloom DA: Vesicoureteral reflux and ureteropelvic junction obstruction: association, treatment options and outcome. *J Urol.*157:969-974 1997.
27. Meyer R: Normal and abnormal development of the ureter in the human embryo—a mechanistic consideration. *Anat Rec.* 96:355 1946.
28. Antoine E. khoury, Darius J. Bagli; Vesicoureteral Reflux; In, Campbell-Walsh Urology; 10th edition ; Alan J. Wein, Louis R. Kavoussi, Andrew C. Novick, Alan W. Partin, Craig A. Peters (eds); chapter 122; pp3286; Philadelphia, Saunders; 2012.
29. Kaefer M, Peters CA, Retik AB, Benaceraff BB: Increased renal echogenicity: a sonographic sign for differentiating between obstructive and nonobstructive etiologies of in utero bladder distention. *J Urol.* 157:1026-1029 1997.

30. Antoine E. khoury, Darius J. Bagli; Vesicoureteral Reflux; In, Campbell-Walsh Urology; 10th edition; Alan J. Wein, Louis R. Kavoussi, Andrew C. Novick, Alan W. Partin, Craig A. Peters (eds); chapter 122; pp 3287; Philadelphia, Saunders; 2012.
31. Estrada Jr CR, Passerotti CC, Graham DA, et al. Nomograms for predicting annual resolution rate of primary vesicoureteral reflux: results from 2,462 children. *J Urol* 2009;182:1535–41.
32. Elder JS, Peters CA, Arant Jr BS, et al. Pediatric Vesicoureteral Reflux Guidelines Panel summary report on the management of primary vesicoureteral reflux in children. *J Urol* 1997;157:1846–51.
33. Ferrer FA, McKenna PH, Hochman HI et al; results of a vesicoureteral reflux practice pattern survey among American Academy of pediatrics, section on pediatric urology members, *J Urol* 1998;160:1031.
34. Dias CS, Silva JM, Diniz JS, et al. Risk factors for recurrent urinary tract infections in a cohort of patients with primary vesicoureteral reflux. *Pediatr Infect Dis J* 2010;29:139–44.
35. Singh-Grewal D, Macdessi J, Craig J. Circumcision for the prevention of urinary tract infection in boys: a systematic review of randomized trials and observational studies. *Arch Dis Child* 2005;90:853–8.
36. Greenfield SP. Antibiotic prophylaxis in pediatric urology: an update. *Curr Urol Rep* 2011;12:126–31.
37. Matouschek E: Treatment of vesicorenal reflux by transurethral teflon-injection (author's transl). *Urologe A*. 20:263-264 1981.
38. O'Donnell B, Puri P: Endoscopic correction of primary vesicoureteric reflux. *Br J Urol*. 58:601-604 1986
39. Kirsch A. J., Perez M. -Brayfield, E. A. Smith, and H. C. Scherz, "The modified sting procedure to correct vesicoureteral reflux: improved results with submucosal implantation within the intramural ureter," *Journal of Urology*, vol. 171, no. 6, part 1, pp. 2413–2416, 2004.
40. P. Puri, B. Chertin, M. Velayudham, L. Dass, E. Colhoun, and H. Snyder,

- “Treatment of vesicoureteral reflux by endoscopic injection of dextranomer/hyaluronic acid copolymer: preliminary results,” *Journal of Urology*, vol. 170, no. 4, pp. 1541–1544, 2003.
41. B. Chertin, E. Colhoun, M. Velayudham, and P. Puri, “Endoscopic treatment of vesicoureteral reflux: 11 to 17 years of followup,” *Journal of Urology*, vol. 167, no. 3, pp. 1443–1445, 2002.
42. B. Chertin and S. Kocherov, “Long-term results of endoscopic treatment of vesicoureteric reflux with different tissue augmenting substances,” *Journal of Pediatric Urology*, vol. 6, no. 3, pp. 251–256, 2010.
43. Aaronson, I.A., Rames, R.A., Greene, W.B., Walsh, L.G., Hasal, U.A., Garen, P.D.
Endoscopic treatment of reflux: migration of Teflon to the lungs and brain. *Eur Urol* 1993;23:394–399.
44. Burns, M.W., Mitchell, M.E. Why we’ve abandoned polytef injection for VUR. *Contemp Urol* 1991;3:40–43.
45. Keating, M.A. Role of periureteral injections in children with vesicoureteral reflux. *Curr Opin Urol* 2005;15:369–373.
46. Leonard MP, Canning DA, Epstein JI, et al.: Local tissue reaction to the subureteral injection of glutaraldehyde cross-linked bovine collagen in humans. *J Urol*. 143:1209-1212 1990.
47. Reunanen M: Correction of vesicoureteral reflux in children by endoscopic collagen injection: a prospective study. *J Urol*. 154:2156-2158 1995.
48. Haferkamp A, Mohring K, Staehler G, et al.: Long-term efficacy of subureteral collagen injection for endoscopic treatment of vesicoureteral reflux in neurogenic bladder cases. *J Urol*. 163:274-277 2000.
49. Antoine E. Khoury, Darius J. Bagli; Vesicoureteral Reflux; In, Campbell-Walsh Urology; 10th edition ; Alan J. Wein, Louis R. Kavoussi, Andrew C. Novick, Alan W. Partin, Craig A. Peters (eds); chapter 122; pp3306; Philadelphia, Saunders; 2012.
50. Stenberg A, Lackgren G: A new bioimplant for the endoscopic treatment of vesicoureteral reflux: experimental and short-term clinical results. *J Urol*. 154:800-

803 1995.

51. Lackgren G, Wahlin N, Skoldenberg E, et al.: Long-term followup of children treated with dextranomer/hyaluronic acid copolymer for vesicoureteral reflux. *J Urol*. 166:1887-1892 2001.

Urol. 166:1887-1892 2001.

52. Ormaechea M, Paladini M, Sambuelli R, Lopez S, Rossetti V, deBadiola F, et al. VANTRIS, a biocompatible, synthetic, nonbiodegradable, bulking substance, easy to inject. Evaluation of local tissular reaction, localized migration and longdistance migration. *Arch Esp Urol* 2008;61:263e8.

53. Matthews RD, Christensen JP, Canning DA: Persistence of autologous free fat transplant in bladder submucosa of rats. *J Urol*. 152:819-821 1994.

54. Duckett JW, Walker RD, Weiss R. Surgical results: International Reflux Study in Children—United States branch. *J Urol* 1992;148: 1674–5.

55. Lipski BA, Mitchell ME, Burns MW. Voiding dysfunction after bilateral extravesical ureteral reimplantation. *J Urol* 1998;159:1019–21.

56. Antoine E. khoury, Darius J. Bagli; Vesicoureteral Reflux; In, Campbell-Walsh Urology; 10th edition; Alan J. Wein, Louis R. Kavoussi, Andrew C. Novick, Alan W. Partin, Craig A. Peters (eds); chapter 122; pp3302; Philadelphia, Saunders; 2012.

57. Marchini GS, Hong YK, Minnillo BJ, et al. Robotic assisted laparoscopic ureteral reimplantation in children: case matched comparative study with open surgical approach. *J Urol* 2011;185:1870–5.

58. Noel A. Armenaks, John A. Fracchia, Ron Golan. in operative dictaion in urologic surgery 2019 chapter 124. 489-492.

59. Chung Ph, Lan Lc, Wong KK, et al. deflux injection for the treatment of vesicoureteric reflux in children- a single centre experience. *Asian J Surg* 2009;32:163-6.

60. Schwab C, Jr, Wu HY, Selman H, Snyder HM, 3rd, Canning DA. spontaneous resolution of reflux; A 15 –year prespective. *J Urol*. 2002;168:25949.

61. Tunk ozdemir, Ali Sayan, Gokhan Koyluoglu et al.. modified Leadbetter-politano ureteroneocystostomy: A safer porocdure. 2018. Izmir Turkey

62. Geoffrey Bisignani, Ross M. Decter et al, voiding cystourethrography after uncomplicated ureteral reimplantaion in children is it necessary. pennsylvania state. 1997.

63.Diego Barrieras,Steven Lapointe,Pramond P Reddy,Pierre Williot,Gordon A.McLore.Darius Bagly,Antoine E.Khouryand Paul A.Merguerian et.al. . Are post operative study justified after uretric reimplantation.jor.of urology.2000.