

Maxillomandibular Changes following Extraction and Non-extraction Orthodontic Treatment -A CEPHALOMETRIC STUDY-

Dr. Evan. A. Clement (M.D.S)¹, Dr. Xavier Dhayananth (M.D.S)², Dr. Shahul Hameed Faizee (M.D.S)³,
Dr. Navaneetha Nambi (M.D.S)⁴, Dr. Priyadarshini (B.D.S)⁵

¹Assistant Professor, Department of Orthodontics, Sathyabama Dental College & Hospital, Chennai, India

²Associate Professor, Department of Orthodontics, Sathyabama Dental College & Hospital, Chennai, India

³Head of the Department, Department of Orthodontics, Sathyabama Dental College & Hospital, Chennai, India

⁴Associate professor, Department of Orthodontics, Sathyabama Dental College & Hospital, Chennai, India

⁵ CRRI (House Surgeon), Sathyabama Dental College & Hospital, Chennai, India

ABSTRACT

Objectives:-The objective of this retrospective study is to evaluate the skeletal maxillomandibular changes after orthodontic treatment through Steiner's cephalometric analysis. **Materials & Methods:-**Pre and post treatment cephalometric radiographs of 50 orthodontic patients were used for this retrospective study, where they have been divided into two groups (25 Extraction and 25 Non extraction cases). Evaluation of Steiners - SNA, SNB and ANB angles in both the Pre and Post treatment cephalogram were done. **Statistics:**The data was tabulated and computed using SPSS software version 21.0. The Pre and Post cephalometric parameter were analysed through paired sample T tests, by calculating the mean difference, Standard deviation and Standard error and paired differences. **Results:-**ANB angle showed a decrease of 1.12° among the patients treated with extraction procedures, and the ANB angle showed increase of 0.2° among patients treated with non extraction procedures.

Conclusion:- The result of the above study suggested that the ANB reduced in patients who underwent extraction orthodontic therapy and the patients treated as non extraction did not show much significant difference.

Keywords:- ANB angle, Extraction, Steiners analysis, Non-Extraction.

Introduction

Cephalometry is a measurement of the head from shadows of bony and soft tissue landmarks on the roentgenographic image. It was spawned by the classic work of **Broadbent** in United states and **Hofrath** in Germany,^{1,2} cephalometrics was first introduced as a tool to study craniofacial growth and development. Later on, it was used to study about the facial forms and it defined the objective of treatment in orthodontics by extending its arena with cephalometric norms. The introduction of **cephalometer** then started avenues for creation of cephalometric analysis guiding in clinical diagnosis and treatment planning. Soon, **cephalogram** became an indispensable weapon for the same and helped to attain correct diagnosis, prognostic evaluation and comparative studies,^{3,4,5}

Cecil.C.Steiner developed a form of cephalometric analysis with parameters which he considered to be the most meaningful and would provide the maximum clinical information with least number of measurements.^{6,7,8} In his analysis he took into account that, it may not be possible to reach ideal proportion and relationship in all cases, but there are ways to maximize the esthetics. Steiner proposed appraisal of various parts of the skull separately namely the **skeletal, dental and soft**

tissues. The skeletal analysis entails relating the upper and lower jaws to the skull and to each other. Whereas, dental analysis relates upper and lower incisor teeth to their respective jaws and to each other. Finally, the soft tissue analysis provide a mean of assessing the balance and harmony of the lower facial profile.^{9,10,11}

In cephalometric analysis, the anteroposterior relationship of the maxilla to the mandible is an important diagnostic criterion. Both angular and linear measurements have been proposed in the assessment of sagittal jaw relationship.¹² The steiners ANB is the most commonly used measurement and statistically validated angle in evaluating the sagittal jaw discrepancy. The SNA angle defines the anteroposterior position of the maxilla, the SNB angle determines the anteroposterior position of the mandible relative to the cranial base and cranial structures. The ANB angle represents the difference between the SNA and SNB angles.

The angle ANB signifies the anteroposterior relationship (sagittal) of maxillary skeletal base to the mandibular skeletal base. This angle has a mean value of $2^{\circ} \pm 2$ which represents an orthognathic profile (Class I Skeletal pattern). If this mean value increases more than 4° it signifies class II skeletal pattern, this disharmony in the value could be due to the discrepancy of forward placement of the maxillary skeletal base or due to the backward placement of the manbibular skeletal base. If the mean value of ANB decreases less than 0° it signifies Class III skeletal pattern, this disharmony in the value could be due to the discrepancy of forward placement of mandibular skeletal base from the normal or due to backward placement of maxillary skeletal base from normal.

Orthodontic treatment brings about post treatment changes in the skeletal, dental and soft tissue. Majority of these orthodontic corrections pertaining to the dental and soft tissue corrections are clinically appreciated, but the changes in the skeletal aspect are evaluated through cephalometry. It is well documented that differences exist in the both the extraction and non extraction treatment protocol when it comes to changes in the soft tissue profile, incisor angulations, vertical facial height, and mandibular plane angle, among other differences.^{13,14,15} But literature towards the Skeletal base relationship (maxillomandibular difference) is scares in literature. So the present study focuses on evaluating the skeletal maxillomandibular changes after orthodontic treatment through cephalometric analysis.

Null hypothesis

Following is the *null hypothesis* of this study:

- (i) There is no change in-between the Pre and Post treatment ANB angle among patient treated with extraction orthodontic therapy.
- (ii) There is no change in-between the Pre and Post treatment ANB angle among patient treated with non extraction orthodontic therapy.
- (iii) There is no difference in the ANB angle between the patients of the extraction and the non extraction group.

Materials & method

In this Retrospective Study, Pre and post treatment cephalometric radiographs of 50 orthodontic patients were analyzed, the samples were divided into two groups (25 Extraction and 25 Non-extraction). The cephalometric radiographs were selected from the Department of Orthodontics of

Sathyabama dental college & Hospital. The lateral cephalograms were selected according to the eligibility criteria stated below.

Sample selection criteria:

- 1) Lateral cephalogram of treated Orthodontic patients above the age of 18 years
- 2) Pre treatment lateral cephalogram of patients with class I or class II Skeletal pattern.
- 3) Dental malocclusion of either class I or class II relationship.
- 4) Extraction cases- cephalogram of patients treated with extraction of all four premolars or only upper premolars.
- 5) Non-Extraction cases- cephalogram of patients treated with fixed Orthodontic therapy without orthopaedic intervention.
- 6) Pre & Post radiographs with good hard or soft tissue outline & lip resting in normal natural posture.

Landmarks

All the cephalograms underwent basic landmark tracing (figure 1), and we analysed Steiners - SNA, SNB and ANB angles in both the Pre and Post treatment cephalogram.(figure 2).

Figure 1 Basic cephalometric landmark tracing

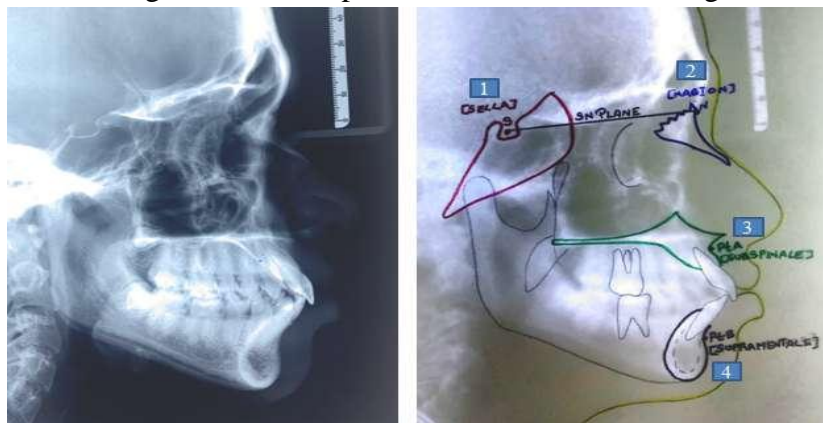
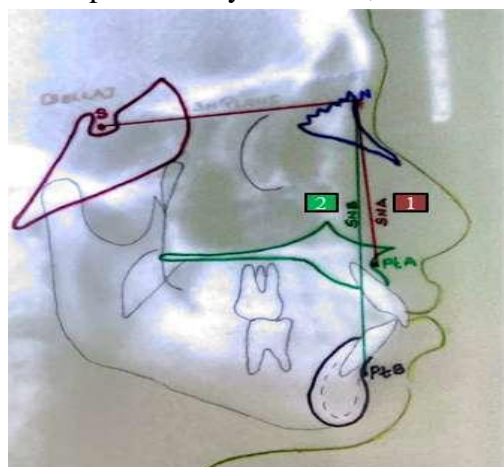


Figure 2 Steiners composite analysis - SNA, SNB and ANB difference



Basic landmarks-

SELLA (S) -Geometric center of the pituitary fossa located by visual inspection, **NASION (N)**- Located on the most anterior aspect of the frontonasal suture, **POINT A-** (subspinale) Represents a stable reference point in maxilla were it is located in the most posterior midline in the concavity between the anterior nasal spine and the prosthion (the most inferior point on the alveolar bone overlying the maxillary incisors) and **POINT B-**(supramentale) represents a stable reference point in mandible were it is located in the most posterior midline in the concavity of the mandible between the most superior point of the alveolar bone overlying the lower incisors (infra dentale) and pogonion.

Reference plane used:

S-N Plane:-refers to the anterior cranial base (sella to nasion), the line of reference to which the jaws are related.

Angles

SNA-The angle which determines whether the maxilla is placed anteriorly or posteriorly to the cranial base. (Mean SNA is $82^{\circ}\pm 2$), SNB- The angle which determines whether the mandible is placed anteriorly or posteriorly to the cranial base. (Mean SNB is $80^{\circ}\pm 2$) and ANB- The angle which determines the maxillomandibular relationships is obtained by the difference of SNA and SNB (Mean is $2^{\circ}\pm 2$).

Statistics:

The data was tabulated and computed using SPSS software version 21.0.The Pre & Post cephalometric parameter were analysed through paired sample T tests, by calculating the mean difference, Standard deviation & Standard error and paired differences.

Results:

In the above study we analyzed 50 patients out of which we divided the samples into two groups 25 extraction and 25 non extraction cases.

Non-Extraction group

The 25 patients in the non extraction group showed a mean Pre-treatment SNA value of 83.52° , SNB of 80.04° and ANB of 3.48° and the Post treatment values of SNA, SNB and ANB of these 25 patients were 83.2° , 79.84° and 3.68° respectively (Table 1)

(Table 1) Comparison of mean, Standard deviation & Standard error for non extraction cases

Parameters	No. of samples	Pre mean	Post mean	Std.dev pre	Std.dev post	Std.error pre	Std.error post
SNA	25	83.52	83.2	4.302	4.406	0.860	0.881
SNB	25	80.04	79.84	3.335	3.375	0.667	0.675
ANB	25	3.48	3.68	1.917	1.973	0.383	0.395

We also identified and divided the patients based on their skeletal base pattern, out of 25 non extraction cases 13 patients were of class I skeletal pattern and 12 patients of class II skeletal

pattern. The 13 class I patients who were treated with non extraction protocol had a mean Pre treatment ANB value of 2.35 °and Post ANB value of 2.59°,Whereas the 12 class II treated patients showed a Pre treatment ANB value of 5.88°and Post ANB value of 6.00°.(Table II)

(Table 2) Comparison of mean, Standard deviation & Standard error for non extraction cases based on skeletal pattern

Parameters		No. of samples	Pre mean	Post mean	Std.dev pre	Std.dev post	Std.error pre	Std.error post
SNA	Class I	13	81.53	81.18	3.393	3.557	.823	.863
	ClassII	12	84.75	85.50	2.659	2.563	.940	.906
SNB	Class I	13	79.18	79.06	3.432	3.561	.832	.864
	ClassII	12	83.88	83.50	2.357	2.330	.833	.824
ANB	Class I	13	2.35	2.59	1.057	1.176	.256	.285
	ClassII	12	5.88	6.00	.641	1.609	.227	.378

Extraction group

The 25 patients in the extraction group showed a mean Pre-treatment SNA value of 82.16°, SNB of 77.84° and ANB of 77.84°and the Post treatment values of SNA, SNB and ANB of these 25 patients were 80.64°,77.28°and 3.20° respectively(Table III)

(Table 3) Comparison of mean, Standard deviation & Standard error for extraction cases

Parameters	No. of samples	Pre mean	Post mean	Std.dev pre	Std.dev post	Std.error pre	Std.error post
SNA	25	82.16	80.64	4.007	3.999	0.801	0.800
SNB	25	77.84	77.28	3.837	3.646	0.767	0.729
ANB	25	4.32	3.20	2.121	2.121	0.502	0.424

Based on patients skeletal pattern, out of 25 extraction cases 14 patients were of class I skeletal pattern and 11 patients had class II skeletal pattern. The 14 class I patients who were treated with non extraction protocol had a mean Pre treatment ANB value of 2.50 °and Post ANB value of 1.64°,Whereas the 12 class II treated patients showed a Pre treatment ANB value of 6.64°and Post ANB value of 5.18°.(Table IV)

(Table 4) Comparison of mean, Standard deviation & Standard error for extraction cases based on skeletal pattern

Parameters		No. of samples	Pre mean	Post mean	Std.dev pre	Std.dev post	Std.error pre	Std.error post
SNA	Class I	14	80.93	79.43	3.540	3.368	.946	.900
	class II	11	83.73	82.18	4.174	4.355	1.258	1.313

SNB	class I	14	78.43	77.50	3.524	3.299	.942	.882
	class II	11	77.09	77.00	4.253	4.195	1.282	1.265
ANB	class I	14	2.50	1.64	.855	.633	.228	.169
	class II	11	6.64	5.18	1.912	1.601	.576	.483

Non-Extraction group versus Extraction group

Mean difference, standard deviation & standard error between the ANB of extraction and non extraction cases was calculated through a paired difference tests. The ANB angle showed a decrease of 1.12° among the patients treated with extraction therapy, and among the non extraction group the ANB angle showed increase of 0.2°(Table V)

(Table 5) Comparison of mean, Standard deviation & Standard error differences for ANB extraction& non extraction cases

Parameters	Mean.diff	Std.dev diff	Std.error diff	95% confidence interval of diff		T	df	sig. 2 tailed
				UPPER	LOWER			
ANB (Extraction)	1.12	0.833	0.167	1.464	0.776	6.725	24	0.000
				0.262	0.662			
ANB (Non Extraction)	0.20	1.118	0.224			0.894	24	0.380

Discussion

Each Orthodontic patient's treatment (extraction or non-extraction) is based on their specific diagnostic criteria. Orthodontic treatment brings about post treatment changes in the skeletal, dental and soft tissue. Majority of orthodontic corrections pertaining to the dental and soft tissue are clinically appreciated. But the changes in the skeletal aspect are evaluated through cephalometry.

In a study conducted on orthodontic diagnosis and treatment procedures among orthodontists in USA showed that, the most commonly used analysis for diagnosis purpose was the Steiner analysis. The ANB of Steiner analysis is an angle that signifies the anteroposterior relationship (sagittal) of maxillary skeletal base to the mandibular skeletal base. ^{16,17}

There are various studies assessing the alterations caused on dentoskeletal components due to the extraction protocol during orthodontic treatment, findings reported by Scott Conleya ¹⁸ were he suggests that the ANB reduced by 2° in class II patients who underwent upper first premolar extraction. In another similar study done by Marisana Piano Seben ¹⁹ suggested that extraction of two maxillary premolars in Class II division 1 malocclusion promotes dentoskeletal and tissue alterations that contribute to an improvement of the relation between the skeletal bases and the soft tissue profile

and from his findings he reported a reduction of 1.27° in ANB among class II patients who underwent upper first premolar extraction

In a study done by Jagan Nath Sharma²⁰ where he evaluated the skeletal and soft tissue points A and B with anterior teeth retraction among bimaxillary protrusion cases who underwent all first premolar extraction. The result of his study showed that the SNA, SNB and ANB showed a reduction of 2.36 , 1.9 and 0.38° respectively in bimaxillary patients whom underwent all first premolar extraction. A systematic review by Guilherme Janson²¹ in which he evaluated changes in apical base sagittal relationship in class II malocclusion treatment with and without premolar extractions. The result revealed that in treated class II non extraction patients treated with both Growth modification and fixed appliance therapy showed an average reduction of 1.56° in the ANB angle. Whereas in the class II malocclusions treated with two maxillary premolar extractions and four premolar extractions produced estimated mean reductions in ANB of 1.88° and 2.55° .

The above study also showed similar findings, we found that the mean difference in ANB angle of the extraction group showed a greater amount of reduction in the angulation when compared to the non extraction group.

We evaluated the mean ANB values according to its skeletal base in both the groups (extraction and non extraction). In the extraction group 14 class I patients had a mean pre treatment ANB value of 2.50° and Post ANB value of 1.64° . The 11 class II patients treated in this group had a mean Pre treatment ANB value of 6.64° and Post ANB value of 5.18° . Among the non extraction cases, 13 class I patients had a mean Pre treatment ANB value of 2.35° and post ANB value of 2.59° , the 12 class II patients treated in the non extraction group had a mean pre treatment ANB value of 5.88° and post ANB value of 6.0° .

The non extraction group of the above study showed an increase of 0.2° in ANB angulations, whereas the extraction group showed a mean reduction of 1.12° . This difference in result, with other studies was due to the fact that the extraction group cases of the above study consisted of patients of both class I and class II skeletal base treated for the correction of crowding and protrusion, and the non extraction group patient did not undergo any growth modification therapy. Patients of both the group were only subjected to fixed appliance therapy.

The results of the above study reject the null hypothesis that (i) there is no change in-between the Pre and Post treatment ANB angle among patient treated with extraction orthodontic therapy, the ANB angle among patient treated with extraction showed a mean reduction of 1.12° . (ii) There is no change in-between the pre and post treatment ANB angle among patient treated with non extraction orthodontic therapy, but the ANB angle among patient treated with non-extraction showed a mean increase of 0.2° . (iii) The result of the study states that there is a difference in the ANB angle between the patients of the extraction and the non extraction group.

Conclusion

From the results of the above sample we suggest that the ANB angle among patient treated with extraction showed a significant reduction of 1.12° between pre and post treatment cephalograms. The

ANB angle of patient treated with non-extraction showed a mean increase of 0.2° which was not statistically significant. The results of this study states that there is a difference in the ANB angle between the patients of the extraction and the non extraction group.

REFERENCES

- 1) Hofrath H. Bedeutung der Roöntgenfern und Abstands Aufnahme für die Diagnostik der Kieferanomalien. Fortschr Orthod 1931;1:231–58.
- 2) Downs WB. Variation in facial relationships: their significance in treatment and prognosis. Am J Orthod 1948;34:812–40.
- 3) Dr. Nabanita Baruah, BDS, Dr. Mitali Bora, MDS, FICD(U.S.A). Cephalometric evaluation based on Steiners analysis on young adults of Assam. JIOS Journal.
- 4) Pacini AJ. Roentgen ray anthropometry of the skull. J Radiol 1922;3:322–31. 2.
- 5) Broadbent BH. A new X-ray technique and its application to orthodontia. Angle Orthod 1931;1:45–66.
- 6) Alexander Jacobson, DMD, MS, MDS, PhD. Radiographic cephalometry. Edition 1995.
- 7) Servoss JM. Derivation of acceptable arrangements in the Steiner analysis. Angle Orthod 1971;41:146–9
- 8) Servoss JM. The acceptability of Steiner's acceptable compromises. Am J Orthod 1973;63:161–5.
- 9) Steiner CC. Cephalometrics for you and me. AM J Orthod 1953;39:79.
- 10) Steiner CC. Cephalometrics in clinical practice. Angle orthod 1959;29:8.
- 11) Steiner CC. The use of cephalometrics as an aid to planning and assessing orthodontic treatment. Am J Orthod 1960;46:721.
- 12) Broadbent BH. A new X-ray technique and its application to orthodontia. Angle Orthod 1931;1:45–66
- 13) Bravo LA. Soft tissue facial profile changes after orthodontic treatment with four premolars extracted. Angle Orthod. 1994;64:31–42.
- 14) Ismail SF, Moss JP, Hennessy R. Three-dimensional assessment of the effects of extraction and nonextraction orthodontic treatment on the face. Am J Orthod Dentofacial Orthop. 2002;121:244–256.
- 15) Kocadereli I. Changes in soft tissue profile after orthodontic treatment with and without extractions. Am J Orthod Dentofacial Orthop. 2002;122:67–72.
- 16) Keim RG, Gottlieb EL, Nelson AH, Vogels DS. 2002 JCO Study of orthodontic diagnosis and treatment procedures. Part 2 Breakdowns of selected variables. J Clin Orthod 2002;36:627–36.
- 17) Ongkosuwito EM, Katsaros C, Bodegom JC, Kuijpers-Jagtman AM. Digitale cephalometrie [Digital cephalometrics]. Ned Tijdschr Tandheelkd 2004;111:266–70.
- 18) R. Scott Conley Christopher Jernigan Soft Tissue Changes after Upper Premolar Extraction in Class II Camouflage Therapy Angle Orthod 2006;76:59–65.
- 19) Marisana Piano Seben, Fabricio Pinelli Valarelli, Karina Maria Salvatore de Freitas Rodrigo Hermont Cançado, Aristeu Correa Bittencourt Neto Cephalometric changes in Class II division 1 patients treated with two maxillary premolars extraction Dental Press J Orthod. 2013 July-Aug;18(4):61-9

- 20) Jagan Nath Sharma Skeletal and Soft Tissue Point A and B Changes Following Orthodontic Treatment of Nepalese Class I Bimaxillary Protrusive Patients (Angle Orthod 2010;80:91–96.)
- 21) Guilherme Janson; Aron Aliaga-Del Castillo; Ana Niederberger Changes in apical base sagittal relationship in Class II malocclusion treatment with and without premolar extractions: A systematic review and meta-analysis (Angle Orthod. 2017;87:338–355)