

# Assessment of efficacy of ultrasonography and computed tomography in the assessment of retroperitoneal masses

Dr. Manish R Shah<sup>1</sup>, Dr. Shoeb Katrawala<sup>2</sup>, Dr Gurudatt Thakkar<sup>3</sup>, Dr Nirali Dhruv Patel<sup>4</sup>

<sup>1</sup>Assistant Professor, Department of Radiology, Dr N D Desai Faculty of Medical Science and Research, Nadiad, Gujarat, Email: shahmanish924@gmail.com

<sup>2</sup>Associate Professor, Department of Radiology, Zydus Medical College & Hospital, Dahod, Gujarat, India

<sup>3</sup>Professor, Department of Radiology, Nootan Medical College and Research center, Visnagar, Gujarat, Email: gurudattthakkar@gmail.com

<sup>4</sup>Assistant Professor, Department of Radiology, Nootan Medical College and Research center, Visnagar, Gujarat, Email: ndp2311@gmail.com

## Correspondence:

Dr Nirali Dhruv Patel, Assistant Professor, Department of Radiology, Nootan Medical College and Research center, Visnagar, Gujarat, Email: ndp2311@gmail.com

## ABSTRACT

**Background:** Pancreatic lesions are a difficult diagnostic and therapeutic challenge owing to the deep-seated location of pancreas. The present study was conducted to compare ultrasonography and computed tomography in the assessment of retroperitoneal masses.

**Materials & Methods:** 84 patients with signs and symptoms of retroperitoneal masses of both genders were enrolled. All underwent USG and MDCT. Data such as name, age, gender etc. was recorded. All underwent USG and MDCT. Ultrasound was performed with Logiq P9 ultrasound machine. MDCT was performed with Siemens Somatom go 32 slice CT machine.

Characteristics like size, appearance, echotexture, vascularity and other findings were studied.

**Results:** Out of 84 patients, males were 34 and females were 50. Clinical features were lump in abdomen in 5, pain in abdomen in 32, fullness of abdomen in 10, weight loss in 14, loss of appetite in 22 and trauma in 1 case. Renal abscess was detected correctly by USG in 18 and MDCT in 20 cases, renal hematoma in 4 and 8, RCC in 7 and 7, complex renal cyst in 13 and 13, pancreatic carcinoma in 7 and 10, adrenal adenoma in 8 and 10, aortic aneurysm in 7 and 9 and pheochromocytoma in 7 and 7 by USG and MDCT respectively. The difference was non-significant ( $P > 0.05$ ).

**Conclusion:** USG can be recommended as a primary screening tool for evaluating retroperitoneal lesions and CT can be used as a confirmatory tool for the further evaluation of the complete extent of lesion.

**Key words:** Retroperitoneal lesions, Renal abscess, MRI, USG

## Introduction

Pancreatic lesions are a difficult diagnostic and therapeutic challenge owing to the deep-seated location of pancreas.<sup>1</sup> Acute or chronic pancreatitis may be associated with pancreatic calcification, pseudocysts, extrapancreatic phlegmons, hemorrhage and pancreatic necrosis/abscess formation which can help the radiologist make an accurate diagnosis.<sup>2</sup>

Several diagnostic modalities can be used for the evaluation of retroperitoneal lesions which include conventional methods (plain radiography, intravenous urography, retroperitoneal lymphography and angiography), Ultrasonography (USG), CT and Magnetic Resonance Imaging (MRI).<sup>3</sup> USG is the initial imaging modality since it is inexpensive, easily available and easy to perform with lack of ionising radiation but the evaluation remains incomplete

because of the large size of tumours which does not allow to precisely define the epicenter and relations with adjacent organs.<sup>4</sup> Ultrasonography (USG) is a good modality because of its low cost, real-time interactions, lack of bioeffects and wide availability.<sup>5</sup> It can provide information about size, site and characteristics of pancreas, pancreatic lesion, diameter of the biliary and pancreatic ducts and site of obstruction. MRI has the drawbacks of high cost, longer scan time and limited availability.<sup>6</sup> MDCT has been used widely as an important pre-operative examination in patients due to its spatial and temporal resolution and a wide anatomic coverage.<sup>7</sup> The present study was conducted to compare ultrasonography and computed tomography in the assessment of retroperitoneal masses.

### Materials & Methods

The present study comprised of 84 patients with signs and symptoms of retroperitoneal masses of both genders. The consent was obtained from all enrolled patients.

Data such as name, age, gender etc. was recorded. All underwent USG and MDCT. Ultrasound was performed with Logiq P9 ultrasound machine. MDCT was performed with Siemens Somatom go 32 slice CT machine. Characteristics like size, appearance, echotexture, vascularity and other findings were studied. The findings were then compared with the findings of MDCT. Data thus obtained were subjected to statistical analysis. P value < 0.05 was considered significant.

### Results

**Table I Distribution of patients**

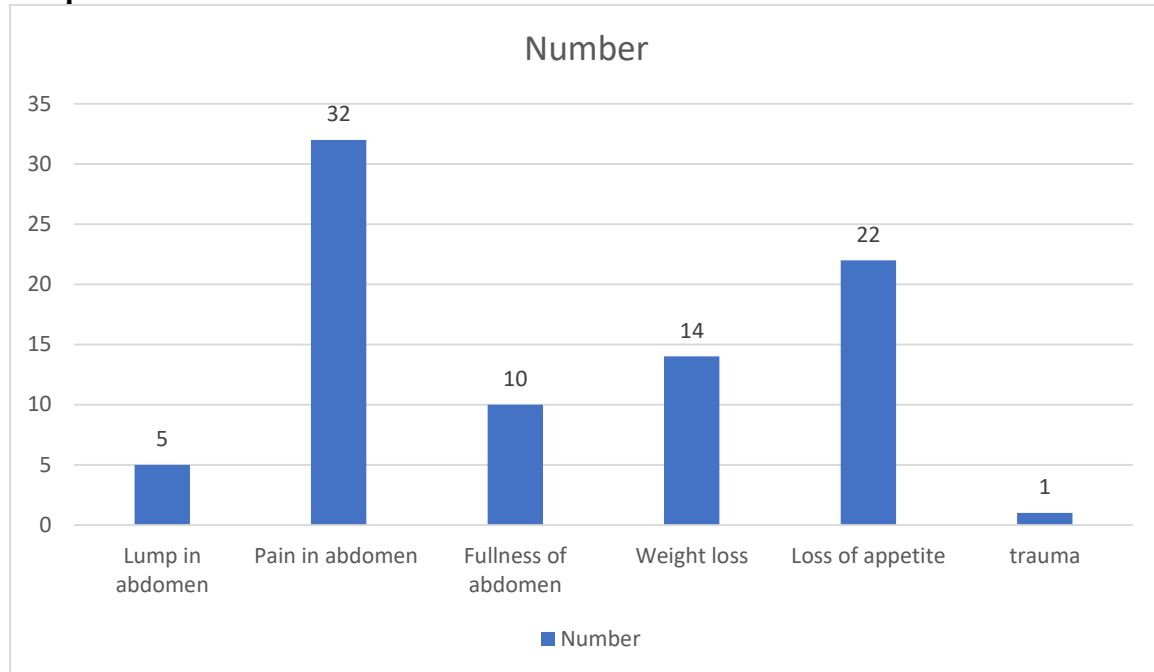
| Total- 84 |       |         |
|-----------|-------|---------|
| Gender    | Males | Females |
| Number    | 34    | 50      |

Table I shows that out of 84 patients, males were 34 and females were 50.

**Table II Distribution of cases**

| Clinical features   | Number | P value |
|---------------------|--------|---------|
| Lump in abdomen     | 5      | 0.01    |
| Pain in abdomen     | 32     |         |
| Fullness of abdomen | 10     |         |
| Weight loss         | 14     |         |
| Loss of appetite    | 22     |         |
| trauma              | 1      |         |

Table II, graph I shows that clinical features were lump in abdomen in 5, pain in abdomen in 32, fullness of abdomen in 10, weight loss in 14, loss of appetite in 22 and trauma in 1 case. The difference was significant (P < 0.05).

**Graph I Distribution of cases****Table III Comparison of diagnosis of retroperitoneal masses by USG and MDCT**

| Diagnosis            | Number | USG | MDCT | P value |
|----------------------|--------|-----|------|---------|
| Renal abscess        | 20     | 18  | 20   | 0.92    |
| Renal hematoma       | 8      | 4   | 8    |         |
| RCC                  | 7      | 7   | 7    |         |
| Complex renal cyst   | 13     | 13  | 13   |         |
| Pancreatic carcinoma | 10     | 7   | 10   |         |
| Adrenal adenoma      | 10     | 8   | 10   |         |
| Aortic aneurysm      | 9      | 7   | 9    |         |
| pheochromocytoma     | 7      | 7   | 7    |         |

Table III shows that renal abscess was detected correctly by USG in 18 and MDCT in 20 cases, renal hematoma in 4 and 8, RCC in 7 and 7, complex renal cyst in 13 and 13, pancreatic carcinoma in 7 and 10, adrenal adenoma in 8 and 10, aortic aneurysm in 7 and 9 and pheochromocytoma in 7 and 7 by USG and MDCT respectively. The difference was non-significant ( $P > 0.05$ ).

### Discussion

Computed tomography plays an important role in the characterisation of retroperitoneal lesions by determining its location, origin, extent, composition (fat, calcification, and necrosis), enhancement pattern, effect on adjacent structures and distant metastases.<sup>8</sup> The characteristic imaging findings can help narrow down the differential diagnosis and therefore aid in treatment planning.<sup>9</sup> The present study was conducted to compare ultrasonography and computed tomography in the assessment of retroperitoneal masses.

We found that out of 84 patients, males were 34 and females were 50. Basvaraj et al<sup>10</sup> evaluated various CT imaging findings of retroperitoneal tumours and to associate it with histopathological findings. The study included 30 patients. Each patient was subjected to plain and contrast enhanced CT to characterise the retroperitoneal tumour. Out of 30 patients, 17 (56.6%) were males and 13 (43.3%) were females. Most commonly affected age group

was seventh decade, followed by sixth decade. Histopathology confirmed the radiologic diagnosis in 26 cases. A total of 80% of the lesions were malignant and 20% were benign. Primary retroperitoneal tumours were the most common tumours (11 cases) accounting for 36.6% of cases. Among primary retroperitoneal tumours, lymphoma (four cases) was the most common tumour followed by lymph nodal metastases (three cases). Other four tumours were liposarcoma, extra-adrenal neuroblastoma, paraganglioma and lymphangioma. Majority of the tumours were solid (29 cases) and only one case was cystic. Heterogeneous enhancement was the most common pattern of enhancement which was seen in 23 cases. Infiltration of adjacent organ was seen in five cases, vascular encasement in seven cases and distant metastasis in six cases.

We observed that clinical features were lump in abdomen in 5, pain in abdomen in 32, fullness of abdomen in 10, weight loss in 14, loss of appetite in 22 and trauma in 1 case. Manoj et al<sup>11</sup> evaluated the utility of USG and MDCT to identify and categorize retroperitoneal masses and to correlate the USG findings with that of MDCT. Seventy-two patients with signs and symptoms of retroperitoneal masses were evaluated by both USG and MDCT. Ultrasound characteristics like size, appearance, echotexture, vascularity and other findings were studied. The findings were then compared with the findings of MDCT. Subjects were evaluated for study variables from USG and CT which were presented as percentages. Based on percentages, the accuracy was calculated. Of the 72 patients included in the study, USG had accuracy of 76.4% in the identification and characterization of the retroperitoneal masses as compared to that of MDCT.

We found that renal abscess was detected correctly by USG in 18 and MDCT in 20 cases, renal hematoma in 4 and 8, RCC in 7 and 7, complex renal cyst in 13 and 13, pancreatic carcinoma in 7 and 10, adrenal adenoma in 8 and 10, aortic aneurysm in 7 and 9 and pheochromocytoma in 7 and 7 by USG and MDCT respectively. Gupta et al<sup>12</sup> studied thirty patients presenting with signs and symptoms of suspected pancreatic lesions. On USG, inflammatory lesions were diagnosed in 15 cases (50%), and on CT scan, the diagnosis was made in 18 patients (60%). Combining the USG & CT findings of inflammatory lesions, the provisional radiological diagnosis of focal pancreatitis was made in 1 case but it was proven to be adenocarcinoma on FNAC. Provisional diagnosis of adenocarcinoma was made in 8 cases, lymphoma in 2 cases, macrocystic adenoma in 1 case and cystadenocarcinoma in 1 case on both USG and CT scan. However, on FNAC, adenocarcinoma was proved in 10 patients, lymphoma was found in one case. Thus, the provisional radiological diagnosis was correct in 28 patients (93.7%).

## Conclusion

Authors found that USG can be recommended as a primary screening tool for evaluating retroperitoneal lesions and CT can be used as a confirmatory tool for the further evaluation of the complete extent of lesion.

## References

1. Connor OJ, McWilliams S, Maher MM. Imaging of Acute Pancreatitis. *AJR*. 2011;197:221–25.
2. KBek S, Kulig J, Popiela T, KoBodziejczyk P, SzybiDski P, Popiela TJ, et al. The value of modern ultrasonographic techniques and computed tomography in detecting and staging of pancreatic carcinoma. *ActaChir Belg*. 2004;104(6):659-67.
3. Dalal U, Singal R, Dalal AK, Kumar Y, Gupta S, Mendiratta P, et al. Enucleation of the solitary epithelial cyst of pancreatic head in an adult: a case report and review of the literature. *Niger J ClinPract*. 2012;15(2):228-30.

4. Kulig J, Popiela T, Zajac A, KBek S, KoBodziejczyk P. The value of imaging techniques in the staging of pancreatic cancer. *SurgEndosc*. 2005;19(3):361-5.
5. Robert J Lesniak, Mark D Howen Walter, Andrew J Taylor. Spectrum of causes of pancreatic calcifications. *AJR*. 2002;178:79-86.
6. Upadhyaya V, Upadhyaya DN, Ansari MA, Shukla VK. Comparative assessment of imaging modalities in biliary obstruction. *Indian J Radiol Imaging*. 2006;16:577-82.
7. Wong JC, Lu DS. Staging of pancreatic adenocarcinoma by imaging studies. *ClinGastroenterolHepatol*. 2008;6(12):1301-8.
8. Takamitsu I, Shigeki M, Kazuo S, Yoshiteru K, Kenya C, Masato F. Spontaneously Ruptured Giant Splenic Cyst with Elevated Serum Levels of CA 19-9, CA 125 and Carcinoembryonic Antigen. *Case Rep Gastroenterol*. 2010;4(2):191-97.
9. Berman L, Mitchell KA, Israel G, Salem RR. Serous Cystadenoma in Communication with the Pancreatic Duct: An Unusual Radiologic and Pathologic Entity. *Journal of Clinical Gastroenterology*. 2010;44(6):133-35.
10. Basavaraju UK, Rajendrakumar NL, Sanjay P, Puttaraj NC, PShivadas P, Seetharam M, Nagaraju RK, Moorthy S. Diagnosis of Retroperitoneal Tumours using Computed Tomography-A Cross-sectional Study. *International Journal of Anatomy, Radiology and Surgery*. 2021 Jan, Vol-10(1): RO32-RO37.
11. Manoj MC, Prabhu CS, Lokesh T. A comparative evaluation of ultrasonography versus computed tomography in the assessment of retroperitoneal masses. *International Journal of Radiology and Diagnostic Imaging* 2021; 4(4): 55-59.
12. Gupta S, Mittal A, Arion RK, Singal R. Comparative evaluation of ultrasonography and computed tomography in pancreatic lesions. *Journal of Medicine*. 2016 Oct 23;17(2):66-78.