

**A PROSPECTIVE STUDY OF JOSHI EXTERNAL STABILIZATION SYSTEM(JESS) IN
MANAGEMENT OF INTERCONDYLAR HUMERUS FRACTURES IN A TERTIARY CARE CENTER.**

DR. GADWAL AZHARUDDIN

Post graduate in department of orthopaedics
Narayana medical college and hospital, Chinthareddy palem
Nellore -pin code 524003, Andhra Pradesh , India
E mail id: azhargadwal555@gmail.com

CORRESPONDING AUTHOR – DR. KONDAREDDY HARIKRISHNA REDDY

Professor in department of orthopedics
Narayana medical college and hospital, Chinthareddy palem
Nellore -pin code 524003, Andhra Pradesh, India
E mail id: dr.harikrishnareddy.k@gmail.com

ABSTRACT

INTRODUCTION:

Intercondylar fracture of distal humerus is one of the difficult fracture involving the humerus in adults. Intercondylar fracture distal humerus in adults are difficult to manage due to complex anatomy of elbow. We present a method of surgical treatment of intercondylar humerus fracture in adults by open reduction with JESS fixator and to evaluate functional outcome and associated complication with application of JESS fixator. **MATERIALS & METHODS:** It is Institutional based, prospective study carried out from June 2021 to May 2022. Twenty cases of intercondylar distal humerus fracture were reduced and fixed with K-wire and finally JESS was applied. Patient were follow up at 1week, 4weeks, 6weeks & 12weeks and clinically evaluated with Mayo's elbow performance score. **RESULTS:** According to AO classification 4 cases had C1 fractures, 14 cases had C2 fractures and 2 cases had C3 fractures. 3 cases had open injury among which two were of C2 and 1 were C3 type. All cases were operated using paratricipital approach and average duration of JESS application was 7 week and mean follow up duration was 9 months. Irrespective of injury pattern 9(45%) cases showed excellent results, 7(35%) showed good results, 3(15%) cases showed fair results and 1(5%) case showed poor results. **DISCUSSION:** The goal of intercondylar fracture management by JESS technique is to achieve early range of motion of anatomically align joint. **CONCLUSION:** This study shows comparatively good results using JESS fixator. This procedure is viable alternative option to ORIF due to its simplicity, cost-effectiveness and easy implant removal on day care basis.

KEYWORDS:

Intercondylar fracture, Humerus, JESS(joshi external stabilization system)

INTRODUCTION

Intercondylar fractures of humerus is relatively uncommon injury in upper extremity. It comprises only one third of all humerus fracture and intercondylar fracture is second most common distal humerus fracture after the extra-articular distal humerus fracture . Distal humerus fracture constitutes only 2% of all fractures, among which 40% constitute extra-articular and 37% constitute intercondylar fracture . Distal humerus fracture carry a bimodal age distribution with peak incidence between 12 to 19 years in men and 80 years in older women . Motor vehicle accidents are the major cause of distal humerus fractures in young population whereas simple accidental falls are the cause in elderly population. These fractures are often multi-fragmentary in elders with osteoporotic bones. Despite advances in techniques and implant, the treatment of intercondylar fracture humerus offers some challenges to surgeons due to complex anatomy of distal humerus, and neurovascular structures in vicinity.

Conservative method for treatment includes bag of bones technique in which a short duration of immobilization in either a cast or a collar and cuff followed by mobilization as tolerated in low demand elderly patients but it often associated with elbow stiffness and delayed or non union because mostly medial and lateral epicondyle separate in either T or Y fashion and forearm musculature attached to these condyle produces rotational re-displacement even after successful close reduction.

The management of severely comminuted intercondylar fractures of the elbow has been a subject of controversy and recommendations for treatment have ranged widely from essentially no treatment to operative reduction and extensive internal fixation. So, many of these fractures particularly those with intra articular comminution, anatomical restoration of the articular surface cannot be adequately achieved or maintained through manipulative reduction alone. Many orthopaedic surgeons stress on preserving the architecture of any joint for its normal restoration of function. The recent trend has been immediate open reduction, stable and rigid internal fixation and early post-operative mobilization.

The anatomic complexity of distal humerus makes surgical reconstruction difficult . Open reduction and internal fixation with dual anatomical plating is considered gold standard treatment as it offers better anatomical reduction and early range of motion physiotherapy. But this technique has also some pitfall like it cannot be performed immediately in open fractures as well as it accompanies the inherent demerits of more periosteal stripping , soft tissue dissection , hardware prominence and complexity in hardware removal (if required). Intra-articular fractures are generally more challenging, because it may require an olecranon osteotomy and extensive dissection for proper visualisation of articular surface.

Difficulties exist in managing distal humerus fracture because of challenges in obtaining anatomical reduction, related ulnar nerve issues, heterotopic ossification, comminution, osteopenia, non-union and the complex decision making regarding its management. Success frequently depends on various factors including quality of reduction, fracture pattern, patient compliance, with physiotherapy and lifting restrictions.

Joshi External Stabilization System (JESS) invented by Dr. Brij Bhusan Joshi, a light weighted biplaner construct appears to be an alternative in treatment of intercondylar humerus fracture because of its simplicity of procedure and shorter learning curve for surgeons. This procedure is cost effective, it offers shorter learning curve and technically less demanding as well as biplaner construct imparts rigidity to fracture fixation, early post operative mobilisation and day care implant removal. With this background the aim of our study is to analyse the functional outcome of comminuted distal intercondylar fracture of distal humerus treated with JESS fixator in Narayana Medical College and Hospital, Nellore.

MATERIALS AND METHODS

It is institutional based, prospective study. This prospective study analyses the functional outcome of JESS fixator application in treatment of intercondylar fracture distal humerus depending on their type and to find out their prognosis. The aim of our study is to analyse the functional outcome of comminuted intercondylar fracture of humerus treated by JESS fixator in Narayana medical college and hospital, Nellore over a period of 12 months duration from June 2021 to may 2022.

Following were the objectives of our study

1. To evaluate the clinical and radiological outcomes of JESS external fixator in management of comminuted intercondylar fracture distal humerus.

2. To evaluate associated complication (if any) with application of JESS external fixator.
3. To note difficulties encountered in operative procedure Inclusion criteria of our study were cases of both sex and age group of more than 18 years and less than 60 years, diagnosed with open and closed intercondylar fracture distal humerus were included and patients who agree for regular follow up.

We excluded cases with associated other injuries or concomitant limb injury, patient with serious medical or surgical illness and those with distal neurovascular deficit and patients not ready to give written informed consent.

Clinical evaluation of the patients were done after stabilising hemodynamically and injured elbow joint was examined. Through history was taken to evaluate mechanism of injury including high energy or low energy mechanism, elbow position during time of injury. Information was also collected regarding the various co-morbid condition associated with the patients as these factors may alter the outcome of treatment.

On examination external wounds, swelling, tenderness, deformity, abnormal mobility, crepitus and loss of transmitted movement which are signs of fracture was noted. A combination of tenderness, swelling, or echymoses over the bone, ligament, joint line suggest an injury. Examination of soft tissue condition is very important in managing these type of injuries. Any open wound, soft tissue contusion, blister around elbow was noted.

Thorough neurovascular examination was carried out. Periodic monitoring of capillary refill time of extremity was assessed. Radiological evaluation was done by X-ray of elbow joint AP and Lateral view.

SURGICAL TECHNIQUE OF THE STUDY

The patients were given a general anaesthesia or regional anaesthesia and were positioned in the lateral position, with the involved limb supported on bolster in OT table. A high arm tourniquet was used with pressure 250 mm Hg for maximum allowable duration was 90 minutes. A midline skin incision was made on posterior aspect of distal arm, curving medially around the tip of olecranon and extending to subcutaneous border of proximal ulna. Subcutaneous dissection was done and ulnar nerve identified proximally and tagged with pen rose drain.

Along the medial side of triceps, the interval between triceps muscle and intermuscular septum was developed and the triceps is elevated off the posterior surface of humerus. Laterally, the triceps is elevated off the lateral intermuscular septum and the posterior humerus in conjunction with anconeus muscle. With the help of retractor triceps was lifted off from distal humerus surface and allows visualisation of medial and lateral column, olecranon fossa, and posterior aspect of trochlea.

In severe comminuted fractures distal fibres of triceps were splitted longitudinally to gain more exposure to intra-articular segment. Thorough debridement with excision of devitalized soft tissue was carried out in open fracture cases to ensure decontamination of the wound. Reduction of the intercondylar region was achieved primarily after satisfactory exposure and careful isolation of ulnar nerve were obtained. As the k-wires need minimal purchase area, care was taken not to denude soft tissue attachment of bone fragments.

The intercondylar fragments were reduced through a bone clamp and fixed with a K-wire from medial to the lateral side. Subsequently, the intercondylar fragment consisting of the lateral and medial condyle was reduced to the metaphysis. Two crossed K-wires were passed obliquely upward, one from each condyle crossing the fracture site, taking purchase in the opposite cortices just above to the

fracture. Once fixation was secured, the elbow was checked for range of motion (ROM) and stability of the reduced fracture fragments.

Finally, 2 K-wires were introduced proximal to the fracture site in the distal humerus, perpendicular to the shaft of the humerus by carefully entering the skin, after blunt soft tissue dissection under direct vision, to avoid radial nerve injury. The wires were then advanced through the medial soft tissues, without injuring the dissected ulnar nerve. These K-wires were kept proud of the skin on either side.

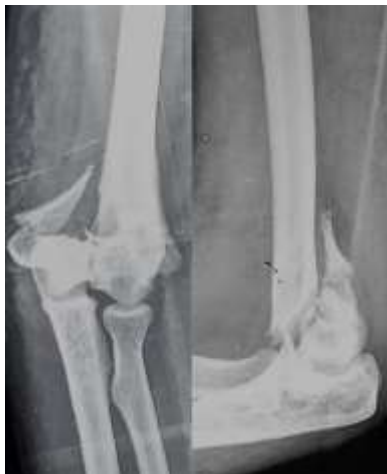All wires inserted through the skin, and special attention was paid to relax the skin every time a K-wire was passed to prevent tension during wound closure. Oblique K-wires, were bent just outside the skin surface to make them parallel to the rest of the wires. All K-wires were cut outside the skin surface at the optimum length (3-4) cm. so that they could be attached to the connecting rod (2 on either side) with the help of link joints.

Thus, a bilateral uniplanar external fixator assembly was created, after thorough wash wound was closed in layers over the drain and pin tract dressing was applied. Post-operative protocol, Limb was kept elevated in immediate post-operative period.

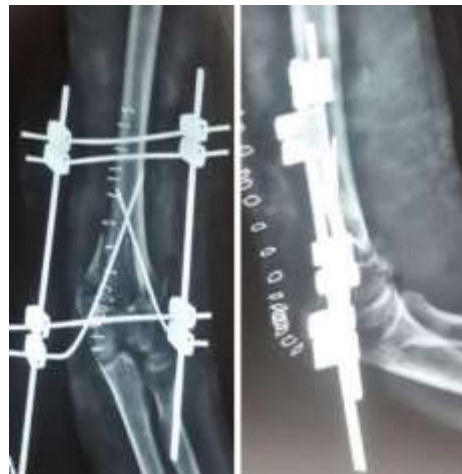Distal neurovascular status was checked and Intra-venous antibiotics given for 48 hours following this drain was removed in 24 hours. Pin tract dressing was done twice in a day. Active and passive elbow physiotherapy started on day 2 to 5 as tolerated and stitch removal was done on 14th post-operative day.

Patient discharged only after suture removal on 14th post-operative day. Follow up clinical and radiological examination done at 2, 4, 8, 12, 16 week then at 6 month and 12 month. JESS fixator was removed after achieving radiological union and all cases were assessed using the mayo elbow performance score and cassebaum's classification for elbow range of movement.

PRE OPERATIVE X RAYS



POST OPERATIVE X RAYS



INTRA OPERATIVE IMAGES

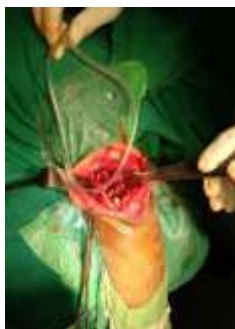

Fig : Identification of ulnar nerve & exposure of fracture site

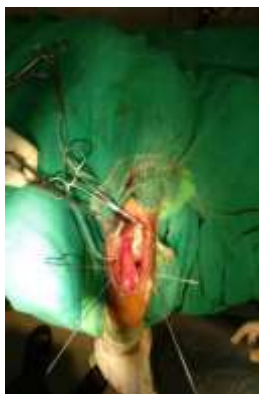

Fig : Fixation of fracture with k-wires

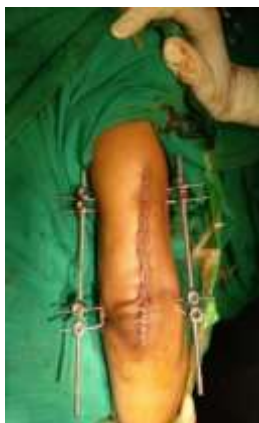

Fig : Final construct of JESS

RESULTS AND OBSERVATIONS

The following observations were made in our study of 20 patients among which 4 cases were compound, there was a minimum follow up of 4 months and maximum 12 months with an average of 9 months. In our study, the youngest patient was 18 years old and the oldest patient was 66 years. The mean age was 42 years. The different age groups were organized into 15-30, 31-45, 46-60, and >60 years. Of the 20 cases, 12 were males and 8 females, males constituted 60% while 40% were females. Falls from height constituted 50% of the cause for fracture etiology, while Road Traffic Accidents (RTA) constituted 30% and domestic falls 20%. In our study, high energy mechanisms attribute to most of the cases (80%) which include both falls from height and Road Traffic Accidents. In our study, the right side was more involved (70%) compared to the left side (30%).

According to AO classification, in our study 14 patients of C2 ,4 patients of C2 and 2 patients of C3 were and all cases operated by using paratricipital approach.

Minimum duration of surgery was 60 minutes while maximum duration was 84 minutes. Out of 20 patients included in our study, 18 of them achieved radiological union, 2 went for delayed union of lateral column. The mean duration of union was 14 to 22 weeks with a mean of 17.27 weeks. Surgical complication seen, among 20 patients 3 developed elbow stiffness, 2 develop minor pin tract infection and 1 patient develop delayed union of medial column although intercondylar region united well.

Mayo elbow performance score (MEPS) shows, among 20 patients 9 showed excellent result(1st quarter), 7 showed good result(2nd quarter), 3 showed fair result(3rd quarter) and 1 showed poor result(4th quarter).

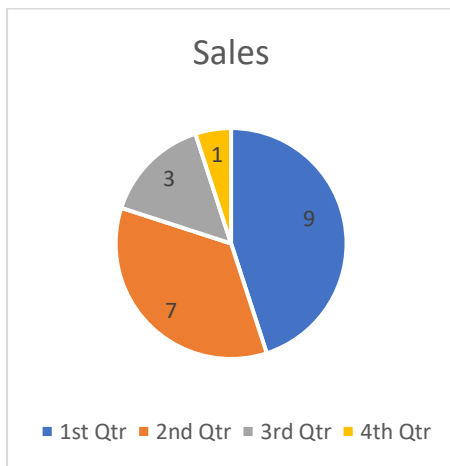
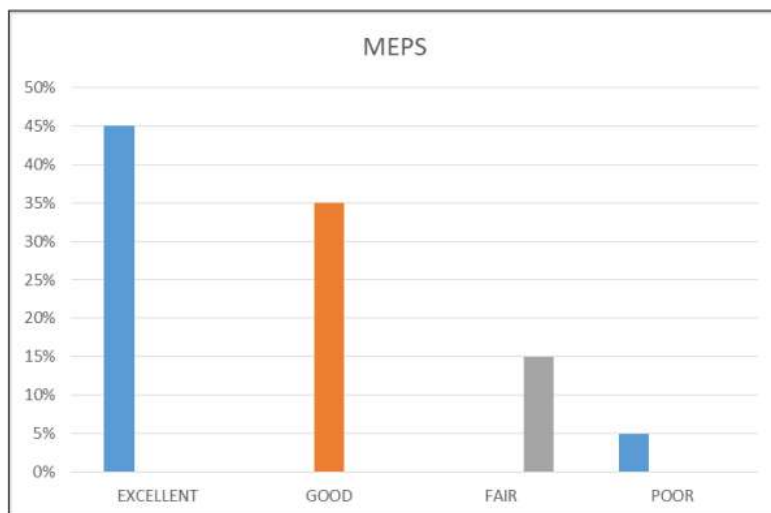


Table 1: Showing duration of union

RANGE	No. OF CASES
12-15 WEEKS	5
16-19 WEEKS	10
20-22 WEEKS	3
DELAYED UNION	2



Graph showing Mayo's Elbow Performance Score (MEPS)

DISCUSSION

Although ORIF is gold standard in distal humerus fractures, in elderly with osteoporotic bone poses a treatment challenge due to poor bone quality. And ORIF cannot be done in cases of compound fracture immediately while JESS fixator can be used as single staged definitive procedure in close or compound intercondylar humerus fracture as early as possible. Conservative treatment is based on “bag of bone” principal. Two common methods include olecranon pin traction and collar and cuff. In olecranon pin traction method, traction should continues until the fractures are sufficiently “sticky” and then convert to a functional cast, cast brace, or hinged brace and controlled motion is encouraged. In collar and cuff method, the affected upper limb is suspended in a collar and cuff in as much flexion as possible. The principal is ligamentotaxis effect by gravity.

The cuff is removed after 6-7 weeks, and the elbow is then mobilized. Good results have been reported using this method in the osteoporotic setting . It often results either in a malunion or non-union of fracture with joint stiffness and poor function. In the presence of open fracture, the “bag of bone principal” is of no value. Conservative management is reserved for low demand patient and patients with severe co-morbidities. JESS-external fixator offers the advantage of component removal in any clinic, without the use of anesthesia, in distinction to the possible necessity of hardware removal with ORIF, which requires an anesthetic and extensive dissection and may lead to additional problems associated with a second surgical procedure. JESS fixation technique is a segmental fixation with a simple construct, thus technically less demanding with a shorter learning curve and can be mastered by a relatively junior consultant.

Lerner et al [8] (2000) treated 7 adult with peri and intraarticular elbow fracture by hybrid ring tubular fixation frames. All fracture united at mean time of 180 days, no deep infection developed, functional score were excellent in two, good in one, and fair in four.

Safoury YA [9] (2011) treated eight patients for post infection nonunion of the supracondylar area of the humerus with the Ilizarov method and followed up for 3 years. All the patients had undergone at least 2 previous failed operations.

The patients were evaluated clinically and radiologically with an outcome survey using the Disabilities of the Arm, Shoulder and Hand (DASH) score. Solid union was achieved in all patients. None had recurrence of infection. Ilizarov treatment for post-infection non-union of the supracondylar humerus was shown to be effective, reliable, and tolerated by the patients.

Ilizarov method is cumbersome and unacceptable to some of the patients. It may be kept as a last resort for chronic, unyielding fractures or infected cases, rather than for primary management of open intercondylar fractures of the distal humerus. The JESS-external fixator frame in the form of a bilateral uniplanar construct with thick K-wires, as used in our patients, appears to be good construct.

Giannoudis, p.v., et al [10] (2005) harvested a cortical bone graft from ileum to reconstruct a severely comminuted open intra-articular distal humerus fracture in an adult patient. The patient demonstrated a satisfactory functional and radiologic outcome despite loss of the lateral trochlear lip. When the lateral portion of the fractured trochlea cannot be repaired, excision of the fragments and insertion of an autogenous cortico-cancellous bone graft from the iliac crest can restore satisfactory function.

Babhulkar S et al [11] . in 2011 operated one hundred and eighty four patients of intra-articular distal humerus fracture by transolecranon approach, first Chevron intra-articular osteotomy was done, followed by olecranon osteotomy was performed. Both column were fixed by orthogonal methods, in

severe comminution with bone loss, parallel plating were done for stabilization and osteotomy was fixed by tension band wiring.

The result were evaluated by Caja staging system at a minimum follow-up of 2 years. Seventy eight patient showed excellent to good results.

LIMITATIONS OF THE STUDY

We acknowledge that with the more number of cases in our study the results and observation would have been more accurate and statistically significant. Long term follow-up is also required to see the full functional outcome and long term complications. This was not possible in our study as the study duration was only for twelve months.

CONCLUSION

From our study application of JESS fixator is simple, safe and effective in treatment of intercondylar fracture humerus. JESS application is a simpler and cost effective as well as require short duration of surgery as compare to ORIF which is technically more demanding. But being an external implant and require proper care of pin tract and hamper daily activity as compare to ORIF. JESS can be alternative to ORIF in selected patient. JESS is effective in treatment of both open as well as closed intercondylar fracture.

REFERENCES

1. Egol KA, Koval KJ, Zuckerman JD. Handbook of fractures. Lippincott Williams & Wilkins, 2010.
2. Heckman JD, McQueen MM, Ricci WM, Tornetta P, McKee MD. Rockwood and Green's fractures in adults. Wolters Kluwer Health, 2015.
3. Koduru Satya Kumar D, Rao CH, Padala VR. Management of lower humeral intercondylar fractures in adults with different implants. International Journal of Orthopaedics. 2018; 4(1):183-9.
4. Helfet DL, Schmeling GJ. Bicondylar intraarticular fractures of the distal humerus in adults. Clinical orthopaedics and related research. 1993; (292):26-36.
5. Henley MB. Intra-articular distal humeral fractures in adults. The Orthopedic clinics of North America. 1987; 18(1):11-23.
6. Holdsworth BJ, Mossad MM. Fractures of the adult distal humerus. Elbow function after internal fixation. The Journal of bone and joint surgery. British volume. 1990; 72(3):362-5.
7. Dupuytren G. Lectures on Clinical Surgery: Delivered in the Hôtel-Dieu of Paris. Stereotyped and published by Duff Green, 1835.
8. Lerner A, Stahl S, Stein H. Hybrid external fixation in high-energy elbow fractures: a modular system with a promising future. Journal of Trauma and Acute Care Surgery. 2000; 49(6):1017-22.
9. Safoury YA, Atteya MR. Treatment of post-infection nonunion of the supracondylar humerus with Ilizarov external fixator. Journal of shoulder and elbow surgery. 2011; 20(6):873-9.
10. Giannoudis PV, Al-Lami MK, Tzioupis C, Zavras D, Grotz MR. Tricortical bone graft for primary reconstruction of comminuted distal humerus fractures. Journal of orthopaedic trauma. 2005; 19(10):741-3.