

# Management of Dislocated Total Hip Replacement overview guidelines.

Mustafa Mohamed Mustafa Eljiru<sup>1</sup>, Yousef Mohamed Mohamed Khaira<sup>2</sup>, Reda Hussein Elkady<sup>3</sup>, and Mohamed Ismael Abdelrhman Kotb<sup>4</sup>

<sup>1</sup>M.B; B.Ch.; Faculty of Medicine, Azzawia University, Libya.

<sup>2</sup>Professor of Orthopedic Surgery, Faculty of Medicine Zagazig University.

<sup>3</sup>Assistant Professor of Orthopedic Surgery, Faculty of Medicine Zagazig University.

<sup>4</sup>Lecturer of Orthopedic Surgery, Faculty of Medicine Zagazig University.

**Corresponding author: Mustafa Mohamed Mustafa Eljiru**

**Email: meljeiro@gmail.com**

## Abstract

**Background:** The hip joint is multi-axial, and synovial ball and socket variety, in general, it can be said that; in all joints, stability and range of movement are in inverse proportion to each other; the hip joint provides a remarkable example of a high degree of both. Its stability is largely the result of the adaptation of the articulating surfaces of acetabulum and femoral head to each other and its great range of mobility results from the femur having a neck that is much narrower than the equatorial diameter of the head. Total Hip Replacement (THA) dislocation is defined as the complete loss of articulation contact between two artificial joint components. Postoperative dislocation is still the most common early complication after THA and one of the most common causes of early revision of primary THA. THA dislocation can be caused by 3 mechanisms or a combination of 2 mechanisms. Depending on the mechanical cause 3 dislocation directions can be observed, even though dislocation direction and component positioning are not necessarily related, the direction of dislocation of THR is usually posterior (77%), while anterior (23%) whereas superior or lateral dislocation has also been described.

**Keywords:** Total Hip Replacement (THA),

## 1. Relevant Anatomy of Hip Joint

### 1.1 Bony Structures of the Hip:

#### The acetabulum

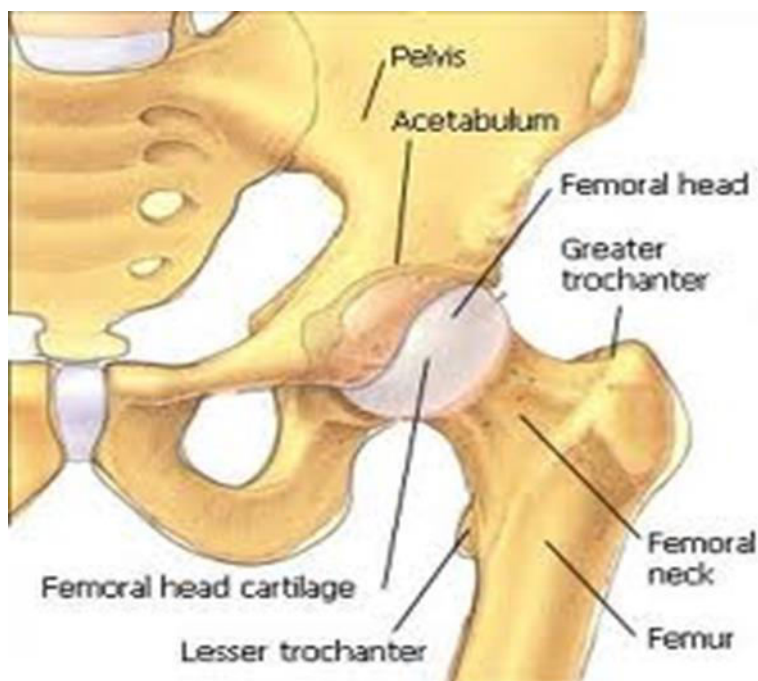
Fusion of the ischium, ilium and pubic bones creates the acetabulum that provides functional columns for bony support of the femoral head in the hip joint articulation. The acetabulum is an approximately hemispherical cavity on the lateral aspect of the hip bone about its center, and directed laterally, downwards and forward (Fig. 1)

(1).

The acetabular surface is orientated approximately 45° caudally and 15° anteriorly. The normal bony acetabular angle of about 55° is reduced to 45° by the presence of the acetabular labrum (2).

If the cup is anteverted 15° or more, then the chances of posterior dislocation are reduced, and the anterior lip of the cup does not contact the patient's femoral neck in flexion and adduction. The cup anteversion, however must not be so great to allow femoral neck contact with the cup in extension and external rotation without impingement because this can lead to anterior dislocation

(2).



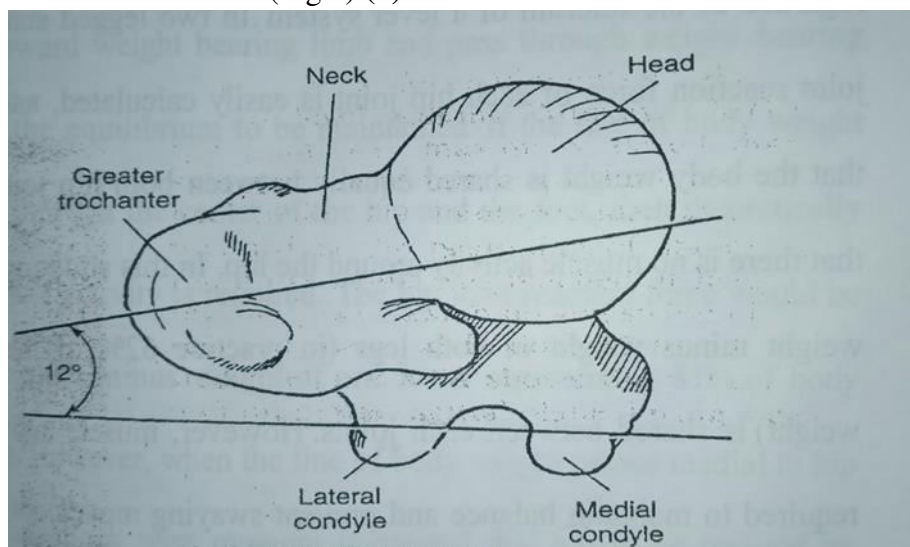
**Figure (1): Anatomy of the hip joint (26).**

### **The Femur:**

The femur is the longest and strongest bone in the human body. Its length is necessary to accomplish the biomechanical needs of gait (3).

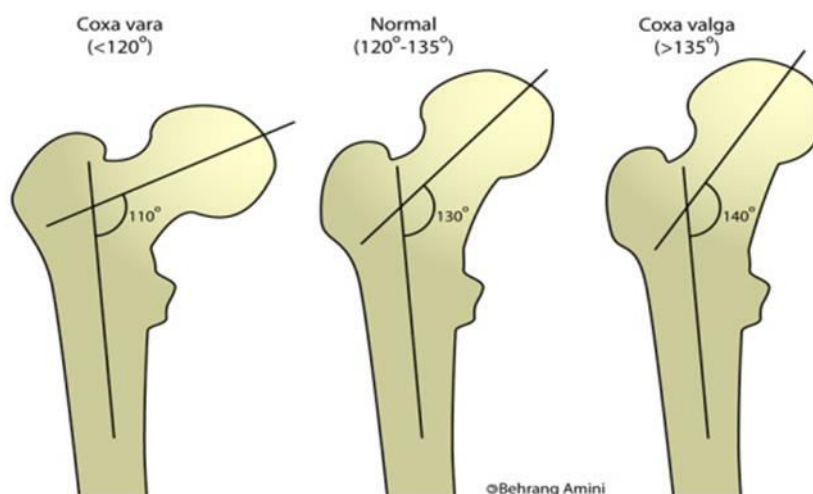
The neck of the femur is narrower than the equatorial diameter of the head and considerable movement in all directions is possible before the femoral neck impinges upon the acetabular labrum (Fig.1). The presence of a relatively narrow neck is the mechanical factor responsible for the wide range of movement in such a stable joint (4).

The hemispherical femoral head diameter averages 46 mm (range 35 to 58) and joins the femoral neck at the subcapital sulcus. The neck shaft angle averages  $135^{\circ}$  (range  $105^{\circ}$  -  $155^{\circ}$  with wide variability). Femoral version is determined by the angle between the plane of the femoral condyles and axis of the femoral neck (Fig. 3). The average adult angle of version is 10 to 15 degrees of ante-version with wide variations (Fig.2) (5).



**Figure (2): Femoral anteversion(27).**

In most hips, the center of the femoral head is at the level of the tip of the greater trochanter. As the neck shaft angle increases, the center of the head comes to lie above the level of the trochanter (resulting in Coxa valga). A decreased neck shaft angle results in coxa vara(5).



**Figure (3):** Femoral neck shaft angles(28).

Also, the distance between the center of the femoral head and the lateral aspect of the trochanter can vary independent of the neck shaft angle (although patients with increased valgus tend to have less offset, while patients with increased varus have more offset). These variants are important because if they are anatomically normal, they need to be reconstructed with the use of femoral components with similar offset and angulation. If the variant is pathological, it is necessary to reestablish normal hip joint kinematics and leg length (5).

## 2. Etiology of Dislocation in THR:

THA dislocation is defined as the complete loss of articulation contact between two artificial joint components<sup>1</sup>. Postoperative dislocation is still the most common early complication after THA and one of the most common causes of early revision of primary THA<sup>3</sup>.

The etiology of instability is often multi-factorial, one or more main contributing factors should be identified proposed a classification of THA instability which consists of three categories (6).

1. Instability due to soft tissue imbalance.
2. Instability caused by incorrect patient position (with impingement as risk factor).
3. Instability due to component malposition.

Investigating these factors individually is vital for preventing and treating dislocation<sup>8</sup>.

THA dislocation can be caused by 3 mechanisms or a combination of 2 mechanisms .Depending on the mechanical cause 3 dislocation directions can be observed, even though dislocation direction and component positioning are not necessarily related, the direction of dislocation of THR is usually posterior (77%) ,while anterior (23%) whereas superior or lateral dislocation has also been described<sup>1</sup>.

For treatment purposes, dislocation after total hip arthroplasty can be categorized early or late on the basis of the timing of the onset. Early dislocation usually occurs in the early post- operative period (within three months) after the arthroplasty and is often successfully treated with non-operative means. In contrast, late dislocation occurs after five years and generally requires surgical treatment. Dislocations occurring between three months and five years may be categorized as

intermediate. This temporal classification is useful because it highlights the differences in the etiology of the dislocation in each category, which in turn determine the type of treatment that is selected (19).

## **2.1 Risk factor for Dislocation:**

### **A. Risk factor related to patients:**

Any condition which weakens musculature and compromises the soft-tissue sleeve around the hip can lead to less intrinsic stability. Therefore patients with a weak abductor muscle, previous hip surgery, and autoimmune disease (rheumatoid, systemic lupus) are at risk to develop dislocations after THA (6).

#### **1-Age:**

In the elderly are major risk factors for dislocation after THA as these conditions often coincide with poor musculature and soft-tissue tension around the hip (6).

#### **2-Gender:**

Female gender is a major risk factor for dislocation in general and women experience significantly more late dislocations than men. The reason for that observation is unclear (6).

#### **3-Previous surgery:**

Prior fractures or surgical procedures involving the hip significantly increase the risk of dislocation. Dislocation rates of up to 50% after prior femoral neck fractures have been reported in the literature (9).

#### **4-Medical condition:**

Higher dislocation incidence of between 5% and 8% annually was observed in patients with neuromuscular conditions, such as muscle dystrophy and autoimmune disease, but also with Parkinson's disease. Some cases like un-cooperative patient, dementia and cerebral palsy consider

### **B. Risk factor related to procedure:**

#### **1-Surgical approaches:**

The choice of surgical approaches for THA is one of the first preoperative decisions that greatly influence the probability of a successful outcome for THA. basic surgical approaches have been used extensively in THA: anterior, posterior, lateral and anterolateral (8).

Numerous studies have shown that the posterior approach to the hip, involving detachment of the external rotators and the posterior joint capsule, is associated with a higher dislocation risk compared with the lateral, anterolateral or anterior approaches. A meta-analysis including more than 13,000 primary total hip arthroplasties with a follow-up period of at least 12 months calculated a dislocation rate of 3.23% for the posterior approach, while the rates for the lateral trans-gluteal approach and the anterolateral approach were 0.55% and 2.18% (9).

They found similar dislocation rates associated with the anterolateral, direct lateral and posterior approaches, if a capsular repair was performed in the latter. Without soft tissue repair, however, the posterior approach was found to have an 8 times greater relative risk of dislocation than with soft tissue repair

(6).

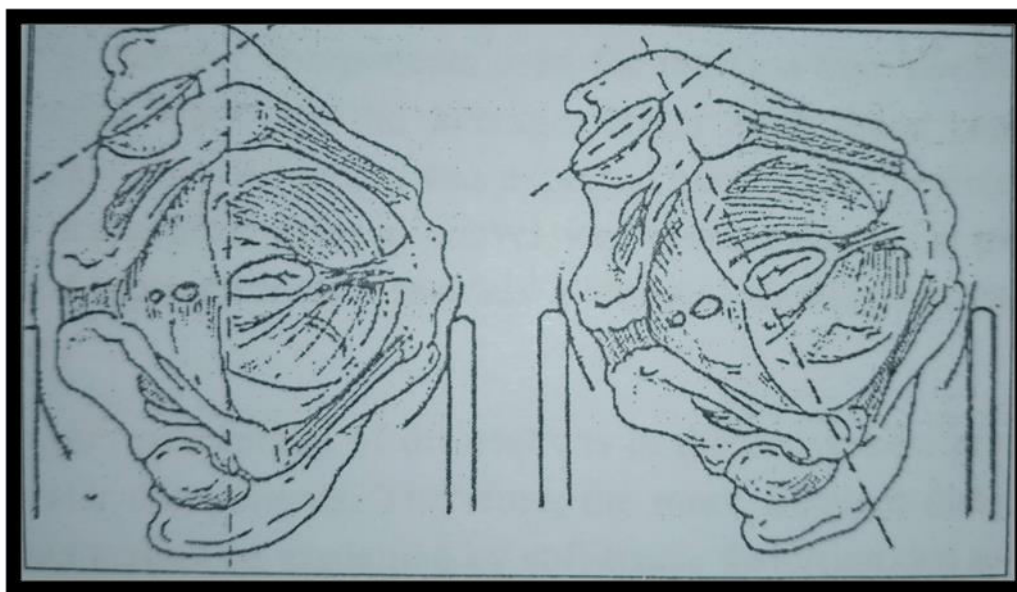
The main reason for the difference is that in the posterior approach, the capsule and the short external rotators that otherwise would provide posterior hip stability and act as a check rein to excessive hip internal rotation are taken down. There are also other reasons; inadequate acetabular

component anteversion is more common with the posterior approach because the femur can interfere with socket insertion, leading to insufficient anteversion, and because when the patient is in the lateral position the pelvis tends to roll forward, creating illusion of increased acetabular anteversion (7).

In contrast, the lateral trans-gluteal approach to the hip joint is associated with an increased risk of functional weakening of the abductor muscles resulting from partial detachment of the gluteus medius muscle or fracture of the greater trochanter. This mechanism is assumed to account for approximately 36% of THA dislocations<sup>1</sup>. Anterolateral and direct lateral approaches were developed to avoid complications inherent in transtrochanteric and surgical approaches oriented posteriorly to the hip for total hip arthroplasty, while maximizing the area for surgical visualization. All anterolateral approaches to the hip joint favor preservation of the posterior soft tissue structures. Variations to the anterolateral approach have been developed and typically differ by the point of entry into the abductors(8).

## 2.2 Patient positioning:

Errors in positioning the patient on the operating table are a common source of acetabular malposition. Secure stabilization of the patient in the lateral position, if the posterior or direct lateral approach is used or knowing how much the patient is tilted, is extremely important (20). When in lateral position, women with broad hips and narrow shoulders are in a relative trendelenburg position and the tendency is to implant the cup more horizontal than it has been planned. In men with narrow pelvis and broad shoulders the reverse is true (Fig 4)(7).



**Figure (4):** Wrong positioning along with insecure of the patient on the operation table can result in acetabular malposition(20).

## 2.3 Surgeon experience:

The surgeon's experience has been shown to be a major factor in the incidence of dislocation after THA. The risk of dislocation can decrease by a factor of 50% for every ten primary total hip arthroplasties performed annually. Nonetheless, all joint replacement surgeons should be familiar with the variations in the common surgical approaches including the orientation of normal and pathologic anatomy of the hip for each surgical technique perspective(8).

Studies have shown that with increasing volume of procedures performed by a surgeon, the risk of THA dislocation significantly drops(9).

#### **2.4 Conversion from hip hemiarthroplasty:**

Conversion of a hip hemiarthroplasty to a total hip replacement is a revision arthroplasty, but it differs from revision of total hip arthroplasties because a native acetabulum is replaced and the subsequent prosthetic femoral head is smaller, there were significantly more dislocations after the conversion procedures (22%) than after the revisions of the total hip arthroplasties (10%)(10).

The sizes of the femoral heads used in hemiarthroplasties have been reported to average 48 mm (range, 42 to 59 mm). Therefore, with femoral head sizes averaging approximately 30 mm, the conversion surgery was responsible for an average 18mm decrease in the head diameter. The importance of this downsizing of the femoral head in conversion surgery is that the soft tissues have been compromised by previous surgical trauma and subsequently seem intolerant of large reductions in head size(10).

Conversion surgery will likely become more prevalent since rates of hip fracture, the most common preoperative indication for hemiarthroplasty, are expected to increase. Controversy remains regarding the ideal arthroplasty option for patients with a hip fracture. So, while a hemiarthroplasty prosthesis may be more stable than a total hip prosthesis initially, the greater risk of dislocation after subsequent conversion of a hemiarthroplasty to a total hip arthroplasty should be recognized and considered during the initial decision process regarding hip fracture treatment. If conversion surgery is necessary, the dislocation risk should be addressed with an emphasis on soft tissue tensioning, including the use of a large femoral head to minimize femoral head downsizing(10).

#### **C. Risk factor related to implantation:**

The discussed risk factors place certain patient populations at increased or decreased risk for dislocation. But for an individual patient, a specific cause or combination of causes lead to the dislocation. Prevention and management of dislocation for individual patients are based on understanding the reasons that dislocation can occur. Fortunately, the number of causes of dislocation is limited, thus a systematic review of possibilities usually leads to identification of the source or sources of the instability(7).

The postoperative time of dislocation is important to determine and compare as the absolute risk of dislocation is not constant over time and a previous report suggested it was cumulative(11).

### **3.1Diagnosis**

History and examination:

Determining the etiology of THA instability requires a detailed patient history. Obtaining information about the mechanism of dislocation, any medical history, number of previous episodes of dislocation, presence of infection symptoms, review of previous documentation; including operative notes documenting what approach was used, types and positioning of implants, as well as any noted intra- or post-operative complications is vital, and complications associated with the procedure is crucial. Understanding the timing of instability, number of dislocations, any non-operative management attempted and fullness or swelling associated with a metal on metal or large metal head THA, can also help in determine the etiology (12).

A thorough physical examination can we required the location of previous incisions that may dictate any cause from surgical approach. While assessing range of movement may be intimidating because of the risk of causing a dislocation in the outpatient clinic setting, an apprehension sign can indicate the position in which the hip is unstable. Assessing the strength of the abductor complex against resistance, both in the supine and lateral position, can yield further information relating to the potential etiology of instability. A comprehensive neurovascular examination of the affected lower extremity as well as a gait analysis is important - patients with a significant Trendelenberg gait may have abductor dysfunction, which should have been identified in the strength-testing phase of the exam. The last component of the physical exam should concentrate on leg length; if a discrepancy is present, inadequate soft-tissue tensioning may be the reason for instability(12).

### **Laboratory investigation:**

It is important to exclude that patients with such infections may that cause instability owing to pus within the joint, leading to a non-concentric reduction of the femoral head within the acetabular liner(12).

The diagnosis of peri-prosthetic joint infection based on the following criteria.. a sinus tract into the joint, a pathogen cultured from tissue or fluid samples obtained from the affected prosthetic joint, or 4 of the following 6:

(1) elevated serum erythrocyte sedimentation rate (ESR) or serum C-reactive protein (CRP) concentration, (2) elevated synovial white blood cell (WBC) count, (3) elevated synovial neutrophil percentage (PMN%), (4) gross purulence, (5) isolation of a microorganism in 1 culture of peri-prosthetic tissue or fluid, and (6) 5neutrophils per high-power field in 5 fields at 400 times magnification(13).

Different values have been evaluated, and threshold levels of 22.5 mm/hr for ESR and 1.35 mg/L for CRP have shown 96% sensitivity and 77% specificity in diagnosing infection if one is positive, or 89% sensitivity and 93% specificity if both are positive (13).

### **Radiological evaluation:**

Standard hip radiographs should be obtained, including a standing antro-posterior (AP) pelvis, AP hip and lateral radiograph. It is imperative to make sure that the direction of dislocation, entire length of the femoral component also is visible radiographically - additional full-length femoral radiographs may be necessary to see the entire prosthesis. In addition, radiograph can be very helpful in evaluating the version of the acetabular component(12).

Additionally, assessment of the relationship of the greater trochanter to the femoral head should be performed to diagnose possible soft tissue tension as well as impingement. Version of the femoral component can be assessed using fluoroscopy (14).

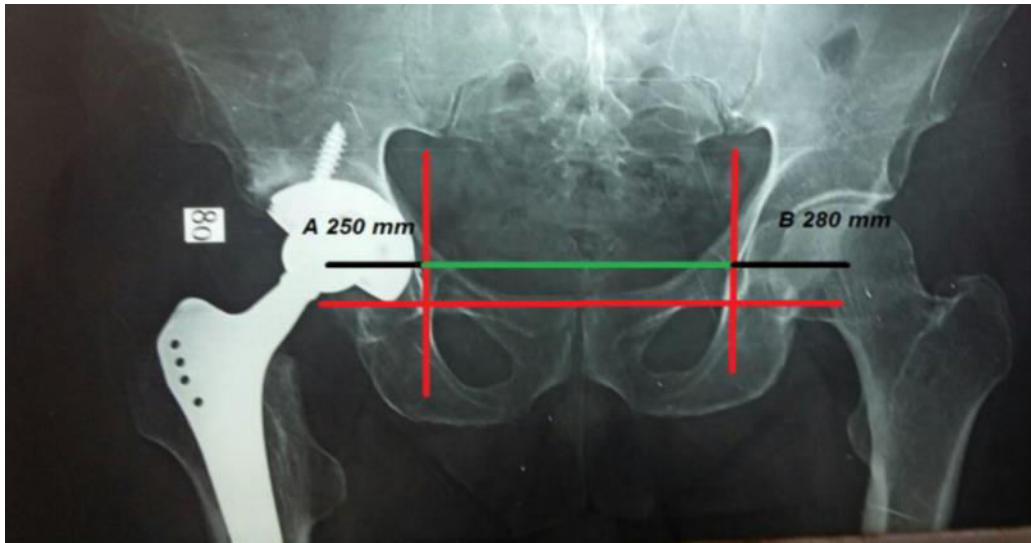
## **3.2 X-ray evaluation to THR:**

### **The horizontal center of rotation:**

The horizontal centre of rotation is defined by the distance between the centre of the femoral head and the teardrop shadow. Ideally, this distance should be equal to that of the contralateral hip; excessive lateral positioning of the acetabular component increases the risk for dislocation and



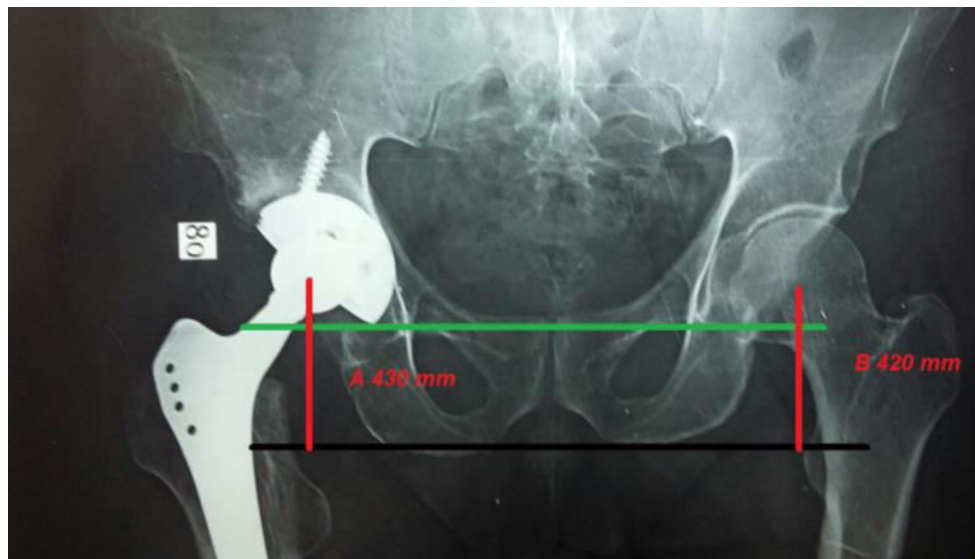
may cause limping. If there is change in migration more than 3mm is sign of early loosening (15).



**Figure (5):** Shows comparison between the horizontal centre of rotation between the operated side and non-operative side (16).

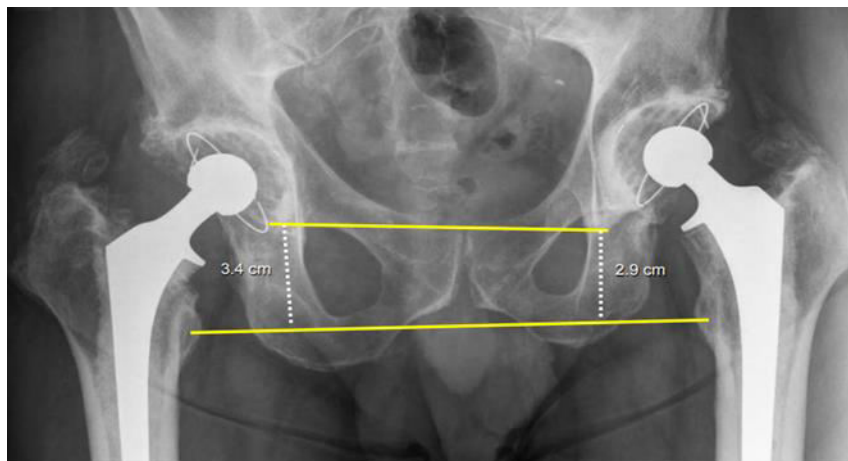
#### **The vertical centre of rotation:**

The vertical centre of rotation is defined by the distance between the centre of the femoral head and the transischial tuberosity line. Ideally, this distance should be equal to that of the contralateral hip, mimicking normal anatomy (15).



**Figure (6):** Shows comparison between the vertical center of rotation between the operated side and the sound site (16).

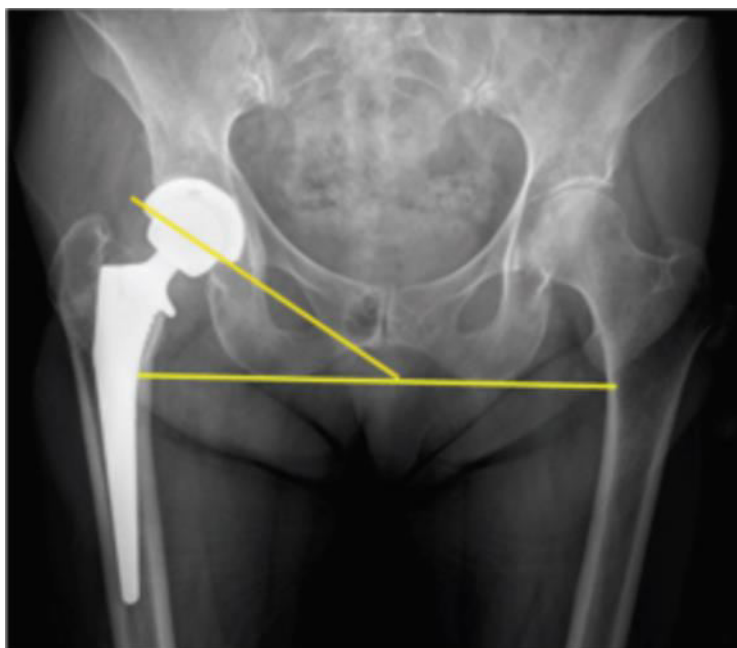



**Figure (7): Shows how to detect leg length discrepancy (16).**

### **The acetabular inclination:**

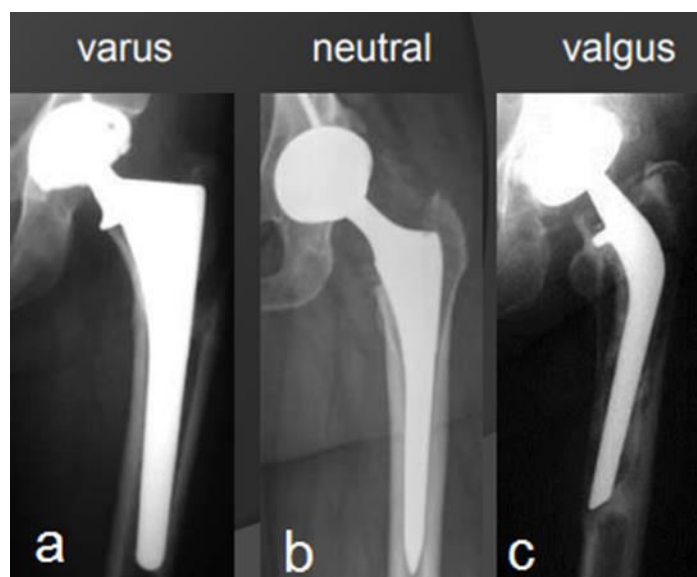
The acetabular inclination is the angle between the articular side of the acetabular cup and the transverse axis. Measurement of this angle can be done by drawing a line through the medial and lateral margins of the cup and measuring the angle with the transischial tuberosity line. The normal range of inclination is between 30 and 50°. Smaller angles provide a stable hip but a reduced abduction. Greater angles are associated with greater risk of hip dislocation. If there is change in angle of abduction at least 4° is sign of early loosening(15).



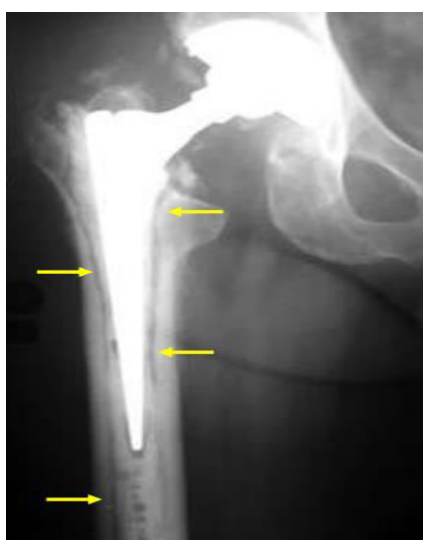
**Figure (8): Shows inclination acetabular angle postoperatively (16).**

### **Femoral stem positioning:**

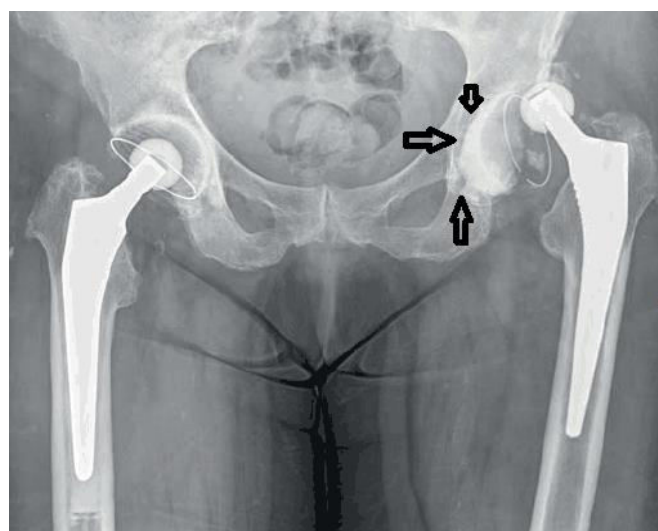
Ideally, the position of the femoral stem on an AP view should be seen in neutral alignment with the longitudinal axis of the femoral shaft and the tip situated in the centre of the shaft. Many studies have shown that failure of the femoral stem is associated with varus malpositioning. Valgus positioning is generally not a significant problem, but varus positioning puts the prosthesis at greater risk of loosening and fracture (17).



**Figure (9):** Shows femoral stem position (16).



**Figure (10):** Shows lucency around femoral stem (16).



**Figure (11):** Shows lucency around the acetabular cup and its dislocated (16).

### 3.3. Management:

About functional rating has been reported for patients experiencing multiple dislocations compared with those who experienced only one or two episodes of dislocation. Therefore, it is prudent for the orthopedist to identify the causes of instability and treat it and intervene early (14).

#### A-Close reduction and abduction brace:

Dislocations that occur in the first 3 months post-operatively are generally treated with closed reduction, most of these dislocations are due to relaxed soft tissues and immature scar tissue formed postoperatively assuming no obvious surgically correctable cause. One concern in primary dislocation is risk of re-dislocation, which can occur in up to 33% of cases. Time of dislocation after surgery may be a prognostic factor. Khan and colleagues reported that 60% of patients with

dislocation experienced primary dislocation after 5 weeks. closed treatment is successful in two thirds of cases(14).



**Figure (12): Hip abduction brace(18).**

### **B- Operative treatment:**

Surgery may be necessary for patients with persistent instability following non-operative management and for those who exhibit obvious component malposition. Reoperation for recurrent instability is not uncommon, with reported rates of 31% to 44% (14) .

Dislocations between 4 months and 5 years are usually due to component malposition or dysfunction of the abductor mechanism. Daley and Morrey assert that this subset of patients would benefit most from reoperation as long as the operative goal is well defined. In one study, component malposition (58%) and failure of the abductor mechanism (42%) were the most common causes of recurrent dislocation determined at the time of operation(14).

The historical rate of success of revision surgery for dislocation is lower than the success rate of revision THA for any other single indication. As our understanding of dislocation improves and as improved devices to manage dislocation become available, the rate of success almost certainly can be improved. Nevertheless, before undertaking revision for instability, it is wise for the surgeon to make the patient aware that restoration of stability is not always successfully accomplished(7).

### **Pre-operative evaluation:**

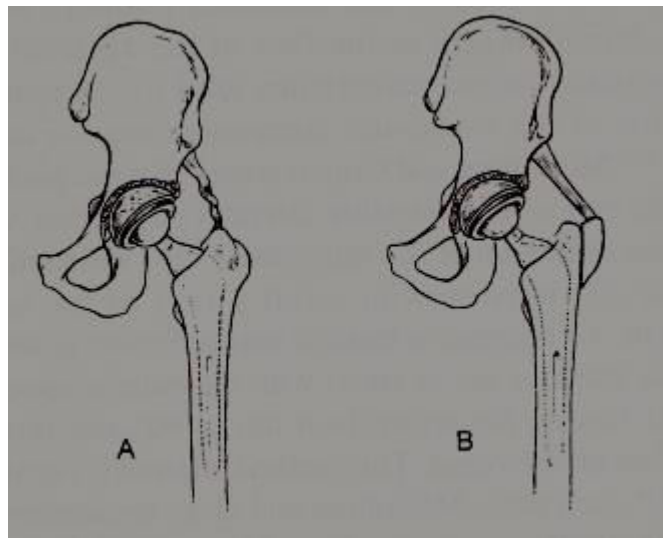
To treat an unstable hip successfully the surgeon must know the direction of instability. This may be surmised from a description of the activity leading to dislocation (hip flexion and internal rotation leading to posterior instability, hip extension, and external rotation leading to anterior instability). However, the most certain knowledge comes from a true lateral radiograph of the pelvis while the hip is dislocated in addition to knowing the direction of dislocation, the surgeon should try to identify other factors that contributed to the instability (7).

A physical examination can help identify factors that predispose to dislocation. Does the patient have abductor insufficiency? Does the patient have severe flexion or adduction contractures? Radiographic evaluation of the arthroplasty provides information about the status of component fixation and implant position. A true lateral radiograph of the pelvis and hip is the most direct

means of obtaining information on socket ante-version. CT scans can provide reliable information on socket and femur position(7).

### **Choosing the operation:**

Once a decision has been made to re-operate, the surgeon has the difficult task of choosing the best surgical procedure. The procedure chosen follows directly from a preoperative understanding of the etiology of the instability in the individual patient. Daly and Morrey, in their review of operative correction of unstable hip arthroplasty, concluded that the results of operative management for an unstable hip arthroplasty can be optimized when a precise determination of the cause of instability is made and appropriate measures applied component malposition requires component reorientation soft tissue tension problems require restoration of tension either by means of changing components or advancing the trochanter; impingement be identified and removed (Figure )(7).



**Figure (13):** Surgical options for management following total hip arthroplasty: A/laxity of abductor mechanism; B/trochanteric advancement (14) .

### **3.4 Operation techniques:**

this technique has been developed for accurate soft tissue balancing after dislocated total hip and not only to restore off-set, but also to restore leg length accurately, restoration of abductor muscle strength, minimization of limp, and decrease in the need for walking aids.

### **Reconstruction of abductor muscle:**

The main problem associated with these procedures is the variability in outcome. These procedures can also be technically demanding and are likely to fail if used in patients with component malpositioning. Therefore, soft-tissue reinforcement is being used with less and only in cases in which component position has absolutely been determined to be acceptable. Other, currently less used surgical procedures for addressing recurrent dislocation. Additionally, these procedures should be reserved for patients who are poor candidates for other options such as the use of a constrained liner (19).

**Greater trochanter Advancement:**

Trochanteric advancement is a safe and effective method of treating recurrent dislocation after total hip arthroplasty, particularly when continued dislocation or resection arthroplasty are the only alternatives. When implants are well fixed and well positioned, greater trochanteric advancement alone, which improves soft tissue tension by means of tightening the abductor mechanism. Kaplan and Robert Poss demonstrated the benefit of trochanteric advancement for treatment of recurrent dislocation. The procedure was performed on 21 patients who had experienced an average of 3.9 dislocations (range, 2-8) in a mean period of 47 weeks after hip replacement (range, 2 weeks to 10 years), and excluded other causes of dislocation. Sixteen of the 21 patients (76%) had no further dislocations after trochanteric advancement. Five patients (24%) dislocated again (21).

**Soft tissue reinforcement:**

The uses of additional static restraint to augment the deficient posterior capsule or enhance a deficient abductor mechanism have been described by many authors, although with notable variability in outcome. Were the first to report the use of an Achilles tendon allograft placed between the greater trochanter and the ischium to reduce the range of internal rotation and enhance stability. In their series of 10 patients, 6 had complete elimination of instability at 3-year follow up(22).

Recent Van Warmerdam described the use of an Achilles auto-graft sling to improve hip stability. In their series of 8 patients, 7 patients had no recurrent instability with maintenance of good postoperative range of motion at an average of 5 years' follow-up. The authors concluded that autograft slings can be used to improve hip stability without significant limitation of postoperative hip range of motion (23).

Barbosa described the successful use of synthetic ligament prosthesis to treat 4 patients with recurrent posterior dislocation of THA without ascertainable cause. At an average follow-up of over 2 years, none of the patients experienced further dislocation (24).

**Increase femoral head size:**

Large femoral heads represent another option to address hip instability. The larger of the femoral head, the greater the volume of the head that needs to be displaced from the acetabulum for dislocation to occur. Jumbo heads are commonly used for revision in dislocation and offer several advantages. These include a give more soft tissue tension by improve head neck ratio, give a larger range of motion before impingement of the prosthetic neck on the acetabular component, and an increased jump distance. Beaulé et al reported decreased episodes of Instability with use of jumbo large heads that average diameter of 44 mm (range, 40 to 50 mm)(19).

**Increase medial offset:**

When a femoral component with a modular head is in place, soft tissue can be improved if a modular head of longer neck length is placed. It should be recognized that long modular heads in most systems have skirts that reduce the head to neck ratio and can cause earlier prosthetic impingement for individual patients the advantages of improved tension have to be weighed against the possibility of earlier prosthetic impingement when this solution is used. If the femoral offset or increased proximal femoral component length can improve soft tissue tension(7).

Decreasing the neck shaft angle increasing offset, while reduces the height of the femoral head, and thus the limb length. This construct directly increases the magnitude of the abductor lever arm. It also has the positive effect of increasing abductor tension, making the muscles more efficient(25).

#### **Constrained liners:**

This device is especially suited for the treatment of recurrent dislocation secondary to soft tissue deficiency. It is also an excellent option for patients with recurrent dislocation of unknown etiology, elderly patients in whom the components are well fixed, and patients with neurological impairment. In other words, constrained liners are used as a salvage treatment option in the most difficult subset of cases. To our knowledge, Anderson et al. were the first to describe the use of constrained liners in patients with recurrent dislocation. They reported a success rate of 72% in a study of eighteen patients followed for a mean of thirty-one months (range, twenty-four to sixty-four months) after the use of this device(19).

**Conflict of Interest:** No conflict of interest.

#### **4. References**

1. **Michael Harty, M. (1998).** Anatomy the hip joint (chapter 2).in:The adult hip. 2nd ed. Lippincott-Raven publishers: 45-9
2. **Cameron, H. U (1992).** The technique of total hip arthroplasty. (St. Louis; Toronto: Mosby Yearbook, c1992.ix, 409 p.
3. **Brown CRW (1998).** **Arthritis and allied conditions.** The Adult Hip. Philadelphia: Lippincott-Raven :561–73.
4. **McMinn, R.M.H. (1994).** Introduction to regional anatomy. Last's Anatomy. Reg. Applied, 9th edn. Edinburgh Churchill Livingstone.
5. **Eftekhari, N.S. (1978).** Principles of total hip arthroplasty. St. Louis, (CV Mosby Company), pp 572-579.
6. **Kirschner, S., Stiehler, M. & Hartmann, A. (2014).** European Surgical Orthopaedics and Traumatology: the EFORT textbook.,1st (ed). New York: Springer Berlin Heidelberg 2621-2634.
7. **Berry, D.J. (2001).** Unstable total hip arthroplasty: detailed overview. Instructional course lectures, 50, 265-274.
8. **Mallory, T.H., Lombardi, J.A.V, Fada, R.A., Herrington, S.M. & Eberle, R.W. (1999).** Dislocation after total hip arthroplasty using the anterolateral abductor split approach. Clin. Orthop. Relat. Res. 166–172.
9. **Dargel, J., Oppermann, J., Brüggemann, G.P. & Eysel, P. (2014)** Dislocation following total hip replacement. Deutsches Ärzteblatt International. Dtsch. Arztebl. Int. 111, 884–891.



10. **Sah, A.P. & Estok, D.M. (2008).** Dislocation rate after conversion from hip hemiarthroplasty to total hip arthroplasty. *JBJS*, 90(3), 506-516.
11. **Meek, R.M.D., Allan, D.B., McPhillips, G., Kerr, L., & Howie, C.R. (2008).** Late dislocation after total hip arthroplasty. *Clinical medicine & research*, 6(1), 17-23.
12. **Sheth, N. P., Melnic, C. M., & Pappas, W. G. (2016).** Evaluation and management of chronic total hip instability. *The bone & joint journal*, 98(A), 44-49.
13. **Monsef, J.B., Parekh, A., Osmani, F., & Gonzalez, M. (2018).** Failed Total Hip Arthroplasty. *JBJS reviews*, 6(11), e3.
14. **DeVVal, H., Su, E., & DiCesare, P.E. (2003).** Instability following total hip arthroplasty. *Am J Orthop (Belle Mead NJ)*, 32, 377-382.
15. **Pluot, E., Davis, E.T., Revell, M., Davies, A.M. & James, S.L.J. (2009).** Hip arthroplasty. Part 2: normal and abnormal radiographic findings. *Clin. Radiol.* 64, 961–971.
16. **Brixey, Clark. (2014)** Total hip arthroplasty. *J. Arthroplasty* 202, 956–963.
17. **Williams, J. & Neep, M. (2012).** Radiographic evaluation of hip replacements. *Spectrum* 19, 8–12.
18. **Baldwin, K.F. & Dorr, L.D. (2001).** The unstable total hip arthroplasty: the role of postoperative bracing. *Instr. Course Lect.* 50, 289–293.
19. **Parvizi, J., Picinic, E. & Sharkey, P.F. (2008).** Revision total hip arthroplasty for instability: surgical techniques and principles. *JBJS* 90, 1134–1142.
20. **Canale, S.T. & Beaty, J.H. (2007).** Fractures and Dislocations of the Hip. *Campbell's Oper. Orthop.* 11th ed. Mosby Elsevier 3262–3270.
21. **Kaplan, S.J., Thomas, W.H. & Poss, R. (1987).** Trochanteric advancement for recurrent dislocation after total hip arthroplasty. *J. Arthroplasty* 2, 119–124.
22. **Turgeon, T.R., Lavigne, M.J., Sanchez, A.A. & Coutts, R.D. (2008).** Recurrent dislocation after total hip arthroplasty: treatment with an achilles tendon allograft. In *Orthopaedic Proceedings (Vol. 90, No. SUPP\_I, pp. 90-90)*. The British Editorial Society of Bone & Joint Surgery.
23. **Van Warmerdam, J. M., McGann, W. A., Donnelly, J. R., Kim, J. & Welch, R. B. (2011).** Achilles' allograft reconstruction for recurrent dislocation in total hip arthroplasty. *J. Arthroplasty* 26, 941–948.
24. **Barbosa, J.K., Khan, A.M. & Andrew, J.G (2004).** Treatment of recurrent dislocation of

total hip arthroplasty using a ligament prosthesis. *J. Arthroplasty* 19, 318–321.

25. **Charles, M.N., Bourne, R.B., Davey, J.R., Greenwald, A.S., Morrey, B.F., & Rorabeck, C.H. (2005).** Soft tissue balancing of the hip: the role of femoral offset restoration. *Instructional course lectures*, 54, 131-141.
26. **Thomas I. (2003).** Pelvic girdle and lower limb. In: *Gray's Anatomy*. Willimas P. Wawick R. 33rd ed. Philadelphia. Mosby Elsevier; 477-82.
27. **Nordin, M. & Frankel, V.H. (2001).** Basic biomechanics of the musculoskeletal system. 3rd ed. Philadelphia (Lippincott Williams & Wilkins) 272-7.
28. **Hoaglund FT, Low WD. (1980).** Anatomy of the femoral neck and head, with comparative data from Caucasians and Hong Kong Chinese. *Clinical orthopaedics and related research*. (152):10–6.