

Post Covid-19 Cerebral Mucormycosis - A Neurosurgical Perspective

Dr. A P Sharath (Resident Surgical Officer)¹, Dr. I D Chaurasia (Assoc. Prof., Neurosurgery)², Dr. Mohammad Riyaz (Resident Surgical Officer)³, Dr. Shivangi Pandey (Resident Surgical Officer)⁴, Dr. Arvind Rai (Prof. & Head Surgery)⁵

^{1,3,4,5}Dept of General Surgery, Gandhi Medical College and Associated Hamidia Hospital, Bhopal, M.P., India

²Dept of M.Ch. Neurosurgery General Surgery, Gandhi Medical College and Associated Hamidia Hospital, Bhopal, M.P., India

First Author: Dr. A P Sharath

Corresponding Author: Dr. I D Chaurasia

Abstract

BACKGROUND - Fungal infections of the central nervous system, especially cerebral mucormycosis are rare. Usually, it is a secondary opportunistic infection than a primary infection of the brain. Recently there has been a rise in cerebral mucormycosis in the patients of COVID 19 due to various factors like impairment of barrier defense mechanisms and use of immunosuppressive medications like steroids for the treatment of COVID 19. The following observational study is conducted by the neurosurgery unit of the General surgery department at Gandhi Medical College Bhopal and its associated hospital.

AIMS AND OBJECTIVES –

The aim of this study was to determine the pattern of cerebral involvement of mucormycosis and the various associated factors in the patients of COVID 19 infection.

MATERIAL AND METHODS- This is an observational study conducted by the neurosurgery unit of the General surgery department of Gandhi medical college and associated Hamidia hospital Bhopal. Details of 55 patients who were treated in various departments of this hospital for post-COVID 19 mucormycosis infection with any kind of cerebral involvement are collected and analysed. The study was undertaken for the duration of 08 months from March 2021 to October 2021.

KEYWORDS – Post-COVID 19 mucormycosis, cerebral mucormycosis, neurosurgical aspect of mucormycosis, a cerebral fungal infection.

CONCLUSION - Mucormycosis is a rare opportunistic infection. The patients with COVID 19 infection are found to be more susceptible to this fungal infection because of impairment of barrier defense mechanism and the use of immunosuppressive medications like steroids and tocilizumab for the treatment of COVID 19 disease. Most patients who encountered mucormycosis were diabetic. Being vigilant in high-risk patients for this fungal infection can improve the quality of patient care and outcome.

1. INTRODUCTION

Fungal infections of the central nervous system, especially cerebral mucormycosis are rare¹. It is usually not an independent disease, but a secondary opportunistic infectious disease caused by the members of the family mucoraceae². During the recent rise in COVID 19 pandemic, cerebral mucormycosis has been reported in an increasing number. This increase in the number of cerebral mucormycosis cases in patients of COVID 19 infection can be attributed to impairment of barrier defense, dysfunction of phagocytes and lymphocytes and the use of

immunosuppressive medications such as steroids and tocilizumab for the treatment of COVID 19³. Due to the aggressive pattern of spreading in this disease, it rapidly involves the surrounding structures. Cerebral extension of this fungal disease can occur either by direct extension, hematogenous route, or perineural spread². Local invasion by nasal and orbital route is the reason for the majority of intracranial mucormycosis³. The disease's hallmark is attributed to tissue necrosis from angioinvasion and subsequent thrombosis and endarteritis, causing dangerous black, necrotic eschars^{4,5}. Clinically, the patient may complain of nasal blockage, crusting, hyposmia or anosmia, headache, blurring of vision, facial pain, atypical signs and symptoms like proptosis, ophthalmoplegia, or periorbital cellulitis, and various other neurological signs and symptoms if the intracranial extension is present⁴. In perineural spread the enhancement in the affected nerve represents neuritis. However, it can progress into a full-blown abscess. MRI stands to be the best diagnostic and non-invasive imaging technology that produces three-dimensional detailed anatomical images that help determine disease spreading and management⁶. The most frequent imaging findings in intracranial mucormycosis are cavernous sinus thrombosis, brain infarction, brain abscess, and internal carotid artery occlusion. The cavernous sinus is usually the first intracranial structure to be involved leading to cavernous sinus thrombosis⁴. Surgical debridement is considered to be the mainstay of mucormycosis treatment and was associated with improved patient outcomes in several case series^{7,8}. Meanwhile extensive surgical debridement, such as orbital exenteration and craniofacial resection is associated with significant morbidity and mortality. Recent studies have found no evidence that such radical surgical procedures improve survival rates⁹. Hence the extent of surgical debridement warrants careful consideration taking into account the patients underlying comorbidities and life expectancy¹⁰. Therefore the decisions regarding the surgical approach, its goals, and extent require careful discussion among neurosurgeons, infectious disease specialist, radiologists, patient, and their families¹¹. Accepted indications for neurosurgery include relief of intracranial pressure, drainage of obstructive hydrocephalus, and excision of lesions compressing the spinal cord. Radical excision of the fungal brain abscess or granuloma should be avoided¹². The study undertaken has mainly focused on the various cerebral manifestations of mucormycosis in patients who were infected with COVID 19 and the neurosurgical overview of its outcomes. In our study, all the patients were clinically evaluated by a team of doctors from otorhinolaryngology, medicine, and neurosurgery specialties. All the patients were treated as per the standards and the results were obtained.

AIMS AND OBJECTIVES

The aim of this study was to determine the pattern of cerebral involvement of mucormycosis and the various associated factors in the patients of COVID 19 infection.

2. MATERIAL & METHOD

All the patients who were admitted in the departments of medicine, otorhinolaryngology, and neurosurgical units of general surgery of GMC Bhopal; for the treatment of post-COVID 19 mucormycosis and had their MRI scan suggestive of cerebral extension of the disease were involved in this study. This study was done for a period of 08 months from March 2021 to October 2021. We collected the details of the patient's symptoms at the time of presentation, co-morbidities, and their MRI brain reports to see the pattern of occurrence of the disease. all the patients were clinically evaluated by a team of doctors from otorhinolaryngology, medicine, and neurosurgery specialties. All the patients were treated as per the standard protocols of post-COVID 19 mucormycosis with the best of the facilities available in the

hospital. No treatment protocols were breached and patient care was not compromised at any level of the study. The collected data was analysed statistically and the results were obtained.

3. RESULTS

General information: There was a total of 55 cases of post-COVID 19 Mucormycosis with cerebral involvement studied which were aged between 24 years (the youngest) and 80 years (the oldest), with a mean age of 50.92 years. Among them, the maximum number of patients was in the age group of 51-60 (29%) years and the minimum was in the age groups of 21-30 and 71-80 (03.6%). 31 cases were male and 24 were female, with a male to female ratio of 1.29: 1.0.

Clinical presentation: Out of the 55 cases studied 26 patients had an eye-related presentation at the time of diagnosis which includes eye pain, eye swelling, and reduced visual acuity. 13 patients presented with hemiparesis, 12 patients presented with headache as primary complaint and 04 patients had other non-specific complaints.

Risk factors: Of all the cases total of 35 (63.6%) patients had exclusively diabetes mellitus 2 as a co-morbidity, 16 (29.09%) patients had both diabetes mellitus 2 and hypertension at the time of presentation, only one patient had only hypertension and 03 (05.45%) patients were not diagnosed with either of the two co-morbidities.

Imaging: MRI brain of all the 55 patients was collected and studied for cerebral involvement. 21/55 (38.18%) patients had involvement of the left side of the brain and 13/55 (32.72%) patients had the involvement of the right hemisphere. The manifestation of the disease in the brain has been divided into the following 7 groups for the convenience of understanding which is based on the MRI brain report.

1. Cerebral abscess (figure 2)
2. Cerebral infarct (figure 1)
3. Cerebral vascular thrombus
4. Thrombophlebitis
5. Ischaemic changes
6. Mixed presentation
7. Non-specific presentation

Out of the 55 patients; 11 (20%) patients had cerebral abscess, 20 (36.36%) patients had cerebral infarcts, 05 (9.9%) patients had thrombus in various cerebral vessels, 02 (3.63%) patients had thrombophlebitis, 04 (7.27%) patients had ischaemic changes, 06 (10.9%) patients had mixed presentations and 07 (12.72%) patients had non-specific presentations.

Outcome: It was observed that 33 (60%) patients out of 55 having cerebral involvement of post-COVID 19 mucormycosis had survived and were discharged of which most of them (75%) were in the age group of 51-60 years. 22 (40%) patients out of 55 died maximum of which was in the extremes of age groups [21-30, 71-80]. Out of all the deaths 71.5% (highest) of the patients had nonspecific changes in the brain as per the MRI brain report followed by cerebral infarct (50%).

TABLE 1 DISTRIBUTION OF AGE WITH OUTCOME

| AGE GROUP | NO OF PATIENTS | PERCENTAGE (%) | OUTCOME | |
|-----------|----------------|----------------|----------|----------|
| | | | SURVIVAL | DEATH |
| 21-30 | 02 | 03.63 | 00(00%) | 02(100%) |

TABLE 2 SEX DISTRIBUTION WITH OUTCOME

| GENDER | NO OF PATIENTS | PERCENTAGE (%) | OUTCOME | |
|--------|----------------|----------------|----------|-------|
| | | | SURVIVAL | DEATH |
| MALE | 31 | 56.36 | 17 | 14 |
| FEMALE | 24 | 43.63 | 16 | 08 |
| TOTAL | 55 | 100 | 33 | 22 |

TABLE 3 OUTCOME DISTRIBUTION

| OUTCOME | NO OF PATIENTS |
|----------|----------------|
| SURVIVAL | 33 |
| DEATH | 22 |
| TOTAL | 55 |

TABLE 4 DISTRIBUTION OF CO-MORBIDITIES

| CO-MORBIDITIES | NO OF PATIENTS | PERCENT AGE |
|----------------|----------------|-------------|
| DM2 | 35 | 63.63 |
| HTN | 01 | 01.81 |
| BOTH | 16 | 29.09 |

TABLE 5 DISTRIBUTION OF SIDE OF CEREBRAL INVOLVEMENT

| SITE OF INVOLVEMENT | NO OF PATIENTS | PERCENTAGE (%) |
|----------------------------|-----------------------|-----------------------|
| RIGHT HEMISPHERE | 18 | 32.72 |
| LEFT HEMISPHERE | 21 | 38.18 |
| BI-LATERAL | 16 | 29.09 |

TABLE 6 MRI FINDING WITH OUTCOME

| MRI FINDING | NO OF PATIENTS (PERCENTAGE%) | OUTCOME | |
|--------------------|-------------------------------------|-----------------|--------------|
| | | SURVIVAL | DEATH |
| ABCESS | 11(20.00) | 07(63.6%) | 04(36.3%) |
| INFARCT | 20(36.36) | 10(50%) | 10(50%) |
| THROMBUS | 05(09.09) | 04(80%) | 01(20%) |
| THROMBOPHLEBITIS | 02(03.63) | 02(100%) | 00(00%) |
| ISCHAEMIA | 04(07.27) | 03(75%) | 01(25%) |
| MIXED | 06(10.90) | 05(83.3%) | 01(16.6%) |
| NON-SPECIFIC | 07(12.72) | 02(28.5%) | 05(71.5%) |

| PRESENTING COMPLAINTS | NO OF PATIENTS |
|------------------------------|-----------------------|
| EYE RELATED | 26 |
| HEMIPARESIS | 13 |

| | |
|----------|----|
| HEADACHE | 12 |
| OTHERS | 04 |
| TOTAL | 55 |

TABLE 7 DISTRIBUTION OF PRESENTING COMPLAINTS

Fig. 1 Acute Infarcts and Chronic Small Vessels Ischemic Changes

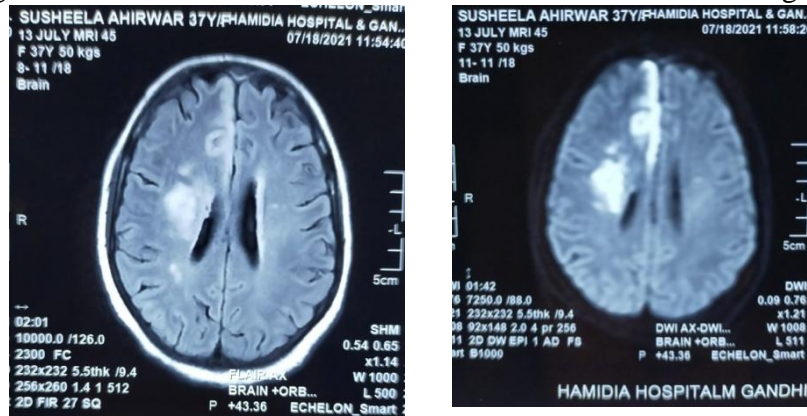
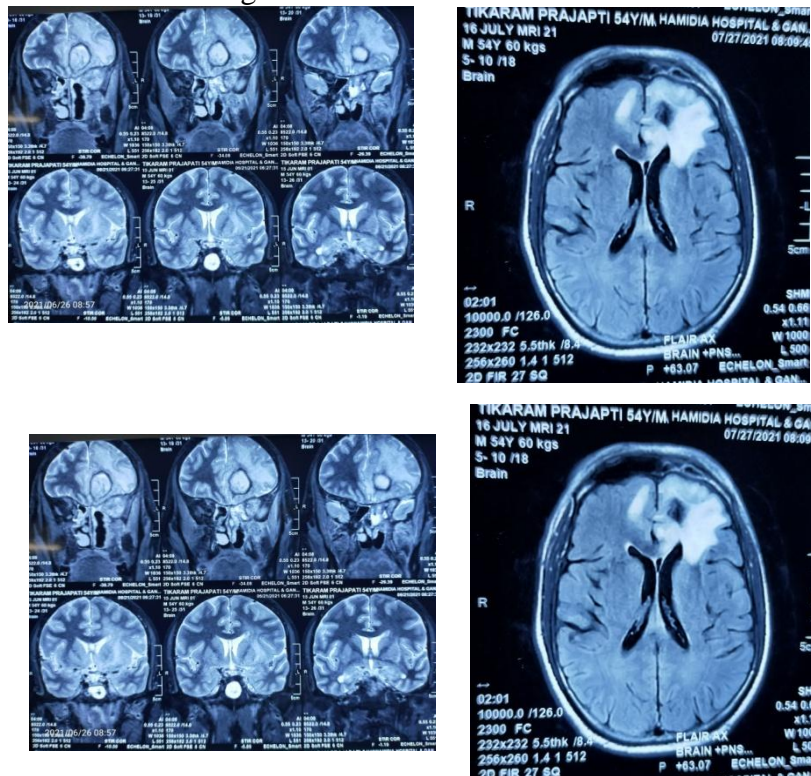


Fig. 2 Left Frontal Abscess



4. DISCUSSION

This research considered that intracranial mucormycosis in patients who had encountered with COVID 19 was not an independent disease, but a secondary opportunistic infectious disease. As the patients with COVID 19 who had been treated with immunosuppressive medications such as steroids and tocilizumab had higher chances of developing secondary opportunistic infections like mucormycosis³. This literature review suggested that almost all the patients who had post-COVID 19 cerebral mucormycosis were having diabetes mellitus 2 as one of the most common comorbidities^{13,14}. The intracranial extension of this opportunistic fungal infection could be through local invasion or blood circulation and become an intracranial infection-based systemic disease^{15,16}. At present, the disease still needs to be thoroughly studied. Therefore this study collected 55 cases of cerebral mucormycosis in patients who were infected with COVID 19 disease and reviewed the related literature for the analysis of this disease's pattern of involvement, risk factors, clinical manifestations and outcome with the aim of helping to understand and comprehend this disease and help in further studies.

Opportunistic infections with fungi in nasal sinusitis are rare, yet it is being reported more in the COVID 19 pandemic¹⁷. Mucormycosis caused by mucormycetes molds has five forms based on site of spread being sinuses, orbit, and brain (rhino-orbito-cerebral), pulmonary, gastrointestinal, cutaneous, and disseminated¹⁸. The infection begins with inhalation of the spores into the oral and nasal cavity. In persons with an intact immune system infection rarely develops because the fungal spores are phagocytized by macrophages. However, in individuals with uncontrolled diabetes mellitus and in immunocompromised patients with severe neutropenia, infection develops as their immune system is weak¹⁹. From here infection spreads to the paranasal sinuses and to orbit via ethmoid and maxillary sinuses or through the nasolacrimal duct resulting in orbital cellulitis. The infection may extend posteriorly to the orbital apex, leading to orbital apex syndrome. The fungus may gain access to the cavernous sinus and to the brain parenchyma through the cribriform plate, orbital apex, or orbital vessels²⁰. Mucormycosis is diagnosed through different approaches. According to the centers for disease control and prevention (CDC), facial swelling, headache, nasal or sinus congestion, and blackish discoloration within the nose or palate are clinical diagnostic approaches. Radiological diagnosis is reachable through CT or MRI, and laboratory diagnosis is obtainable either by culture or pathology²¹.

Fifty-five cases in 08-month duration in a single hospital are considered a relative breakthrough in incidence in such type of rare opportunistic disease. The following study aims at obtaining a pattern of this disease's cerebral involvement, related risk factors, and the outcome of the disease from a neurosurgical perspective.

5. CONCLUSION

Mucormycosis is a rare opportunistic infection. The patients with COVID 19 infection are found to be more susceptible to this fungal infection because of impairment of barrier defense mechanism and the use of immunosuppressive medications like steroids and tocilizumab for the treatment of COVID 19 disease. Most patients who encountered mucormycosis were diabetic.

Most of the patients of cerebral involvement of mucormycosis have evidence of nasal and orbital involvement. The treating doctor needs to be vigilant for the occurrence of this fungal infection in patients with comorbidities and treated for COVID 19 disease who are presenting with the typical above-mentioned clinical features. This can help in early diagnosis and better patient care.

6. REFERENCES

- [1] Jinjian Ma 1, Ruichao Jia 1, Jin Li 1, Yunyang Liu 1, Yuming Li 2, Peng Lin 3, Mingmu Zhang 4, Mu Li . Retrospective Clinical Study of Eighty-One Cases of Intracranial Mucormycosis. Oct-Dec 2015;7(4):143-50.
- [2] Kritika Sharma,1 Tapendra Tiwari,2 Saurabh Goyal,2 Rajaram Sharma. Rhino-orbito-cerebral mucormycosis causing cranial nerve abscess in post-COVID-19 status. . BMJ Case Rep 2021;14:e245756.
- [3] Poonia Nemi Chand, Mangal Akshay, Faujdar Mansi. Post Covid-19 Cerebellar Mucormycosis Without Apparent Rhino-Orbital or Ear Involvement – A Case Report. JMSCR Vol||09||Issue||06||Page 261-264||June.
- [4] Sharad Pandey, Abrar Ahad Wani. Intracranial Mucormycosis—A Minacious Foe. Indian Journal of Neurosurgery 2021; 10(02): 092-094.
- [5] Chikley A, Ben-Ami R, Kontoyiannis DP. Mucormycosis of the central nervous system. J Fungi (Basel 2019; 5 (03) 59
- [6] Galletti B, Freni F, Meduri A, et al. Rhino-Orbito-Cerebral mucormycosis in diabetic disease mucormycosis in diabetic disease. J CraniofacSurg 2020;31:e321–4.
- [7] Roden M.M., Zaoutis T.E., Buchanan W.L., Knudsen T.A., Sarkisova T.A., Schaufele R.L., Sein M., Sein T., Chiou C.C., Chu J.H., et al. Epidemiology and outcome of zygomycosis: A review of 929 reported cases. *Clin. Infect. Dis.* 2005;41:634–653. doi: 10.1086/432579. [[PubMed](#)] [[CrossRef](#)] [[Google Scholar](#)]
- [8] Lanternier F., Dannaoui E., Morizot G., Elie C., Garcia-Hermoso D., Huerre M., Bitar D., Dromer F., Lortholary O., French Mycosis Study Group A global analysis of mucormycosis in France: The RetroZygo Study (2005–2007) *Clin. Infect. Dis.* 2012;54:S35–S43. doi: 10.1093/cid/cir880. [[PubMed](#)] [[CrossRef](#)] [[Google Scholar](#)].
- [9] Davoudi S., Kumar V.A., Jiang Y., Kupferman M., Kontoyiannis D.P. Invasive mould sinusitis in patients with haematological malignancies: A 10 year single-centre study. *J. Antimicrob. Chemother.* 2015;70:2899–2905. doi: 10.1093/jac/dkv198. [[PubMed](#)] [[CrossRef](#)] [[Google Scholar](#)].
- [10] [Amanda Chikley](#), [Ronen Ben-Ami](#), and [Dimitrios P Kontoyiannis](#). Mucormycosis of the Central Nervous System. 019 Sep; 5(3): 59.
- [11] Ben-Ami R., Halaburda K., Klyasova G., Metan G., Torosian T., Akova M. A multidisciplinary team approach to the management of patients with suspected or diagnosed invasive fungal disease. *J. Antimicrob. Chemother.* 2013;68:iii25–iii33. doi: 10.1093/jac/dkt390. [[PubMed](#)] [[CrossRef](#)] [[Google Scholar](#)].
- [12] McCarthy M., Rosengart A., Schuetz A.N., Kontoyiannis D.P., Walsh T.J. Mold infections of the central nervous system. *N. Engl. J. Med.* 2014;371:150–160. doi: 10.1056/NEJMra1216008. [[PMC free article](#)] [[PubMed](#)] [[CrossRef](#)] [[Google Scholar](#)].
- [13] Sen M, Lahane S, Lahane TP, Parekh R, Honavar SG. [Mucor in a viral land: a tale of two pathogens](#). Indian J Ophthalmol 2021; 69 (02) 244-252.
- [14] Ribes JA, Vanover-Sams CL, Baker DJ. Zygomycetes in human disease. *Clin Microbiol Rev.* 2000;13(2):236–301. doi: 10.1128/CMR.13.2.236.
- [15] Abu El-Naaj I, Leiser Y, Wolff A, Peled M. The surgical management of rhinocerebralmucormycosis. J Craniomaxillofac Surg. 2013;41:291–5.
- [16] Jinjian Ma 1, Ruichao Jia 1, Jin Li 1, Yunyang Liu. Retrospective Clinical Study of Eighty-One Cases of Intracranial Mucormycosis. J Glob Infect Dis, Oct-Dec 2015;7(4):143-50.
- [17] Dyer O. Covid-19: India sees record deaths as “black fungus” spreads fear. BMJ. 2021;373:n1238. doi: 10.1136/bmj.n1238.

- [18] Ribes JA, Vanover-Sams CL, Baker DJ. Zygomycetes in human disease. *Clin Microbiol Rev.* 2000;13(2):236–301. doi: 10.1128/CMR.13.2.236.
- [19] Roden MM, Zaoutis TE, Buchanan WL, et al. Epidemiology and outcome of zygomycosis: a review of 929 reported cases. *Clin Infect Dis.* 2005;5(41):634–653. doi: 10.1086/432579.
- [20] Snaith J, Burns K, Kok J, Chen S, Cheung NW. A case of rhino-orbital mucormycosis in diabetes with haematogenous cerebral spread. *Med Mycol Case Rep.* 2016;13:22–24. doi: 10.1016/j.mmcr.2016.10.002.
- [21] Centers for Disease Control and Prevention, National Center for Emerging and Zoonotic Infectious Diseases (NCEZID), Division of Foodborne, Waterborne, and Environmental Diseases (DFWED): symptoms of mucormycosis, January 14, 2021.