

IMPORTANCE OF THE ALTITUDE INDEX IN THE DIAGNOSTICS OF FRACTURES OF THE CALCANEUS IN CHILDREN

Zevara Karimova, Yakshimurat Kurambaev, Zulkhumor Jumaeva
Termez branch of the Tashkent Medical Academy Republic of Uzbekistan
E-mail: zulkhumor.jumayeva@gmail.com

Abstract. *More often, the injuries happen as a result of direct trauma, and are rarely caused by non-direct action-traumatic force. The definition of tarano-calcaneus corner and higher index (rentgenological) has great influence on diagnostics and on curing calcaneus bones in children. On moderate displacement, closed reposition with the skeleton stretching or compression apparatus distinction osteosynthesis is recommended. On crude displacement, it is recommended to perform operative treatment and replace defects of bones by tissues free auto-transplantation.*

Keywords: *fracture of calcaneus, fracture of foot bone, stiffness, classification, deformation, fractures of metatarsal bone, regeneration, consolidation, altitude index.*

Introduction

Children's foot performs an important cushioning function due to its high elasticity and a peculiar arch of a similar structure. Therefore, stiffness occurs after fractures of the foot bones, especially in the plantar arch. This leads not only to a violation of the support, but also to a sharp decrease in the depreciation functions of the foot, which can be a cause of long-term effects due to joint overload, such as foot stiffness. Calcaneal fractures in children are relatively rare, and make up to 8-10% of all fractures of the foot bones [1, 2, 3, 4].

In this regard, morphofunctional diagnosis of the condition of the feet is an essential element in the prevention of a number of disorders of the musculoskeletal system [5,6,7]. The determination of the individual typological variability of the morphology and function of a healthy foot are of a particular relevance, since it is rather difficult to draw a clear line between the types of the normal foot and the initial stages of its deformation, taking into account gender, age, body type, and level of functional load [8].

The data obtained [9] indicate that with a dosed load in girls, the width changes more than the length. The width of the foot to a greater extent characterizes gender differences than its other parameters, in particular the index of the foot. In this case, the body mass parameters have a significant effect on the static parameters of the width of the foot [11,12].

Purpose. Determination of the altitude index for various fractures of the calcaneus in children. Based on the data, determine the degree of displacement of the fragments and the nature of the fractures.

Materials and methods. Over the past 10 years, 64 patients with calcaneus fractures aged 4 to 15 years have been treated in the Department of Pediatric Surgery and Traumatology. By the nature of the fracture, the children were divided as follows:

- isolated fractures of the internal process - 5;
- horizontal fractures of the tubercle - 10;
- partial apophysiolysis of the hillock - 12;
- vertical fractures of the calcaneal tuber with displacement - 9;
- compression comminuted fractures - 8;
- calcaneus fractures - 10.

The clinical picture of calcaneus fractures was diverse and depended on the type and degree of displacement of the fragments. With isolated fractures of the internal process and horizontal fractures without displacement, there was a moderately pronounced swelling and pain in the area of damage. The axial load on the heel was painless and the children could even step on their feet. Vertical changes without displacement were usually accompanied by pronounced swelling and pain on the lateral surfaces of the heel. The axial load was painful, the children did not step on the heel, but could rest on the front of the foot. Vertical fractures with displacement were accompanied by a flattening of the arch. Palpation of the calcaneal region was painful, patients could not step on their heels. As for the compression fractures of the calcaneus, they were characterized by severe deformation of the foot by a sharp flattening of the arch, thickening and widening of the heel. The tops of the ankles were lower than on the healthy side. Palpation exacerbated soreness, movements in the ankle joint, especially associated with tension of the calf muscle, were limited and painful.

The clinical picture with calcaneus fractures due to the variety of its injuries is very diverse. In widespread practice, the most commonly accepted classification of calcaneal fractures is the one proposed by Kaplan AZ [1]. However, these classifications are proposed for adults and cannot be fully used in pediatric traumatology, because they do not take into account the characteristics of childhood. In our work, we distinguish extraarticular and intraarticular fractures of the calcaneus. Extraarticular fractures include: isolated fractures of the internal process, partial apophysiolytic of the calcaneal tuber, fractures of the calcaneal tuber (horizontal and vertical). Compression comminuted fractures of the calcaneus are intraarticular injuries.

In isolated fractures of the internal process of the calcaneus, a moderate traumatic swelling is observed along the inner surface of the hindfoot. Palpation tenderness under the inner ankle is moderately expressed. Movements are possible almost in full, but painful. A child can lean on his leg.

Partial apophysiolytic of the calcaneal tuber is characterized by the forced equinus position of the foot. When viewed from behind, a traumatic swelling and a more pronounced retraction on the sides of the Achilles tendon are visible. Palpation of the calcaneal tuber is painful, while pressure on the lateral surfaces of the heel does not cause pain. Movement in the ankle joint, especially the extension of the foot, is sharply painful. A child cannot step on his foot.

In case of horizontal fractures of the calcaneal tuber (like the “duck beak”), when viewed from behind, a relative increase in the vertical size of the heel is noted. The openings on the sides of the Achilles tendon are flattened. Palpation in the area of the calcaneal tuber in the back and on the lateral surfaces is painful. Active movements in the ankle joint are practically absent due to pain, passive movements are sharply limited. The support function of the foot is impaired.

Vertical fractures of the calcaneal tuber are characterized by the presence of traumatic swelling along the lateral surfaces of the calcaneal region. In fractures without significant displacement, the deformation of the foot is not determined. Palpation on the lateral surfaces of the heel is sharply painful. No foot load possible. In fractures with displacement, deformation of the foot due to the flattening of its internal longitudinal arch is noted. Traumatic swelling is more pronounced and widespread. Achilles tendon tension is observed. The arch of the foot is changed a little. Movement in the ankle joint is limited by displacement due to pain. In fractures with a pronounced or gross displacement, there is a sharp expansion of the heel region, variation or valgization of the heel. The arch of the foot is flattened or completely absent. A comparative examination of the ankle tip on the affected side is significantly lower than on the healthy side. The patient cannot step on the foot.

Results and discussion

The final diagnosis was made only after x-ray examination. Radiographs were made in the lateral and dorsum-plantar (axial) projections. Particular importance was attached to the determination of the talus-calcaneal angle (Beler angle) from radiographs. As you know, this angle is formed by lines drawn through the highest points of the articular surface of the calcaneus. In children, this angle is normally 20° - 40° . With vertical tubercle fractures with displacement, as well as with compression fractures, the talocalcaneal angle decreased, with pronounced displacements it was zero or even opened in the opposite direction. In addition, the degree of compression of the calcaneus when it is damaged was determined by the altitude index, which represents the ratio of the height (the highest part of the articular surface in the lateral radiograph) to its width (in the axial image) (see Figure 1).

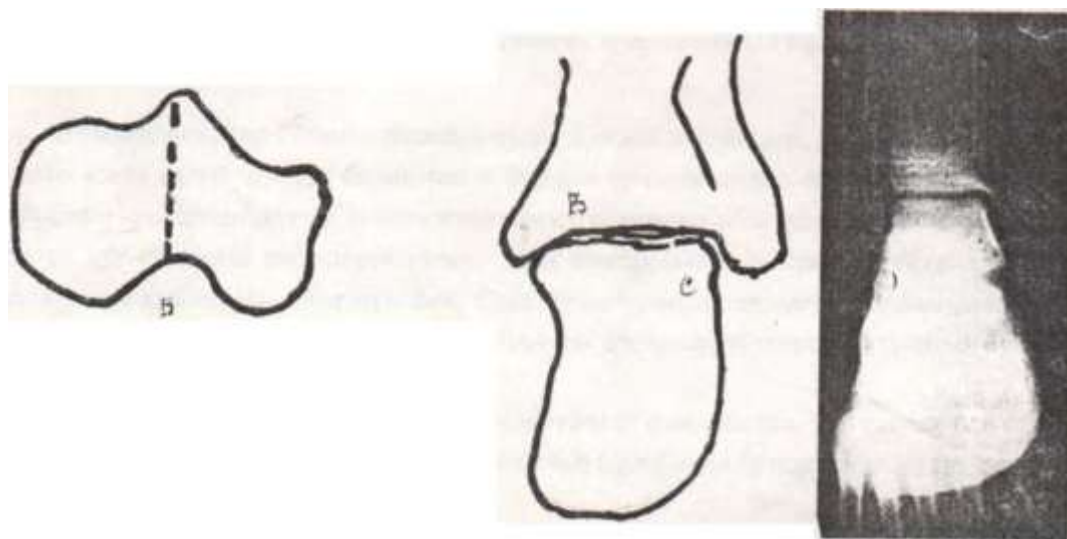


Figure 1. Determination of height and width of calcaneus for calculating the “altitude index”.

Normally, the altitude index in children is 0.7-0.9. With pronounced compression, this index decreased to 0.5. Analysis of the data of our material showed the following.

In 4 patients with compression calcaneal fractures, the talocalcaneal angle was 15° - 17° , and the altitude index remained within the normal range, which was classified as a calcaneus deformity of the first degree. At the II degree of deformity (5 patients), the talocalcaneal angle was reduced to 10° , and the altitude index was 0.6-0.65.

Deformity of the calcaneus bone of the III degree was observed in 4 patients — the talocalcaneal angle reached 5° , the altitude index decreased to 0.55-0.6. The IV degree of deformity was observed in 3 patients, in whom the talocalcaneal angle turned out to be about zero degrees, the altitude index was 0.5-0.55.

The next place in the frequency of fractures is occupied by the tarsal bones - 130 patients (33.9%). Most of the damage falls on calcaneus fractures, which were observed in 100 children (76.9%). Talus fractures occurred in 13 patients (10%). Fractures of other bones of the tarsus were observed much less frequently. Such a distribution of fractures is understandable, because fractures of the tarsus are observed mainly when falling from a height to the feet and the calcaneus first hits the surface.

Patients with phalange finger fractures were observed much less frequently in the hospital, since such patients are more often treated on an outpatient basis.

The distribution of patients by gender is interesting. It is known that the number of injuries in boys exceeds the number of injuries in girls by 3-4 times. In case of fractures of the foot bones, this ratio is not always observed. Thus, fractures of foot bones in boys were

observed almost 6 times more often (D:M =1:5.8). The ratio D:M =1:3.7 that features childhood injury, was observed only in children with fractures of the metatarsal bones. Among children with fractures of the phalanges of the fingers, this ratio was more than 2 times lower - D:M =1.7. Fractures of the tarsal bones were found in boys more than 15 times more often than in girls (D:M =1:15.2). Fractures of the calcaneus in boys are 19 times higher than the number of fractures in girls.

This phenomenon is difficult to explain. Obviously, sexual and psycho-physiological features cannot cause such frequent fractures of the tarsal bones in boys. Fractures of the foot bones were observed in all age groups, but their distribution by age and localization was also peculiar. So, fractures of the phalanges of the fingers prevailed in children under the age of 3 years, due to the mechanogenesis of the injury. Basically, fractures arose as a result of an impact of a heavy hard object. Fractures of the tarsus and metatarsal bones in children under 3 years of age were not noted. They were mainly observed in patients of the older age group (11-14 years) – 47,3%. Fractures of large bones of the foot (tarsus and metatarsus) were observed in three children aged 8-10 years. Almost a fifth of the fractures of large bones of the foot were noted in the age group of 4-7 years.

The overwhelming majority of fractures were not accompanied by a violation of the integrity of the skin - 291 children (87,1%). Open fractures were noted in approximately one eighth of patients - 43 (12,9%).

Mechanogenesis of trauma largely determines the localization, and the nature of fractures of the metatarsal bones. The distribution of patients according to the location and nature of the fracture is presented in the Table 1.

Table 1: Distribution of patients with metatarsal fractures according to the location and nature of the fracture

Metatarsal bones localization	Fravture type		Feature of the fracture								Total	
	closed	open	Subcapital		Diaphyseal						N	%
			N	%	Transverse		Oblique		Base			
					N	%	N	%	N	%		
I	43	5	7	14,6	11	22,9	13	27,1	17	35,4	48	25,5
II	35	3	11	28,9	10	26,3	9	23,7	8	21,1	38	20,2
III	38	5	11	25,6	12	27,9	11	25,6	8	20,9	43	22,9
IV	18	4	7	31,8	9	40,9	4	18,2	2	9,1	22	11,7
V	29	8	5	13,5	6	16,2	9	24,3	17	46,0	37	19,7
Total: N, %	163	25	41	21,8	48	25,5	46	24,5	53	28,2	188	100

As can be seen from the Table 1, fractures (epiphysiolysis) of the base are the characteristic of damage to the I metatarsal bone, which are noted in more than a third of patients. This fact indicates that fractures more often occur when a foot hits a solid object. Oblique daaphyseal fractures were observed in 27.1% of children, which indicates an indirect mechanism of injury. Slightly less transverse diaphyseal fractures occurred as a result of a direct impact (22.9%). Least of all were subcapital fractures.

The treatment of sick children with injuries of the calcaneus was planned individually depending on the type of fracture and the degree of displacement of bone fragments. In case of isolated fractures of the appendage of the talus or calcaneal tuber without displacement, the limb was fixed with a deep posterior plaster cast from the tip of the fingers to the middle third of the thigh, and the limb was bent to 90° in the knee joint. The duration of immobilization was usually 3-5 weeks. The limbs gave an elevated position, the foot was in the equinus position. From the very first days, exercise therapy was performed for the I period. After 1.5-2 weeks, the plaster cast was replaced with a lancet-circular bandage, and it

was applied to the knee joint, and in the ankle joint the foot was installed at an angle of 90°-100°. Usually, 1 month after hospitalization, patients were allowed to gradually advance, preferably with crutches. To accelerate the regeneration and consolidation of fragments, calcium preparations, mummies, osteogenon and vitamins were prescribed. After removal of the plaster cast, patients were prescribed exercise therapy, foot salt baths, light stroking massage, ionophoresis with calcium and phosphorus drugs, prolonged (up to 1 year or more) wearing of an arch support.

In case of horizontal tubercle fractures of the “duck beak” type and vertical fractures, a closed manual reposition was performed under local anesthesia with 1% novocaine solution and a plaster cast was applied in the above manner. Larger displacements required an open reposition with fixation of fragments by Kirchner spokes (Figure 2).

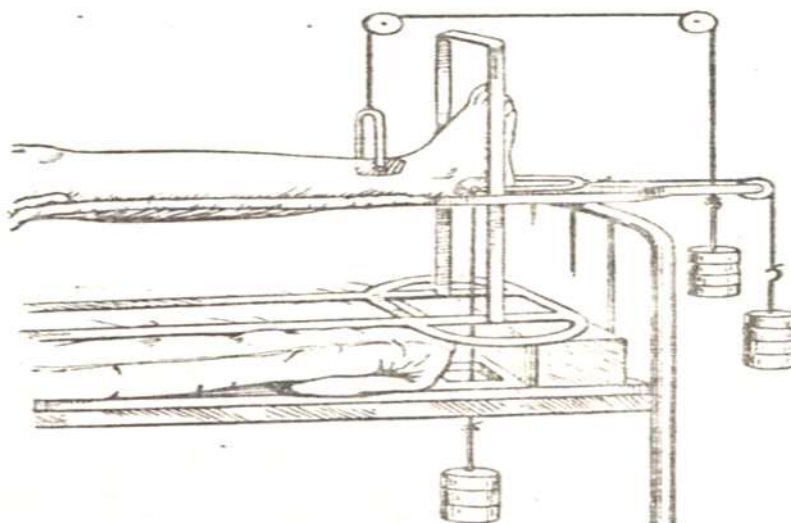


Figure 2. The scheme of superposition of skeletal traction in case of calcaneus fractures (according to Kaplan AZ).

Skeletal traction in 2 mutually perpendicular planes according to Kaplan AZ was used for vertical fractures of the calcaneal tuber with displacement of fragments (7 patients). The extension lasted 2-3 weeks, after which the needles were removed and a circular bandage was applied to the knee joint.

Compression fractures of the calcaneus of the III-IV degree were considered as an indication for surgical treatment. So, 4 patients underwent compression-distraction osteosynthesis. In 2 patients with compression fractures of the IV degree with open reposition, a defect appeared between the fragments, which required replenishment with an autograft taken from the iliac wing. Bone fragments and grafts were fixed with knitting needles and screws. Long-term results were studied in 30 patients. Patients, on the whole, did not present any special complaints, led an ordinary way of life, but 14 had flat feet, which was also observed on the intact side.

Thus, taking into account the information above, we consider our approach to the diagnosis and treatment of calcaneal bone fractures in children, based on the comparison of the clinical picture of the damage with the data of an X-ray examination, justified and think that it meets the requirements. The differentiated diagnosis of calcaneus fractures made it possible to select the optimal treatment tactics, due to the nature of the damage and the

degree of displacement of bone fragments. Patients with calcaneus fractures required lengthy rehabilitation measures with the obligatory wearing of arch support.

Conclusions

Calcaneal fractures more often occurred as a result of direct trauma, less often they were caused by indirect exposure to traumatic force. Determination of the talocalcaneal angle and the altitude index (radiological) is of great importance in the diagnosis of damage to the calcaneus in children. At moderately expressed displacements of fragments, a closed manual reposition by skeletal traction or by an external fixation apparatus is shown. With gross displacements, surgical treatment and replacement of defects with autografts should be performed.

Literature

- [1] Kaplan AV. Closed injuries of bones and joints. 3rd edition. 1979,125.
- [2] Volkov MV, Kodjibaeva ZK., Samoilovich EF. Diagnosis of calcaneus fractures. 1991,11
- [3] Circassian-Zade DI. Traumatology and orthopedics. Edited by Shaposhnikova YuG. Moscow,1997:2.
- [4] Musamatov X, Yumashev G, Silin L. Traumatology and orthopedics. Translation into Uzbek. 2007:1.
- [5] Bairov GA. Pediatric traumatology. 2015.
- [6] Volkov MV. Orthopedics and traumatology of infancy. 2016.
- [7] Smirnova LA. Traumatology and orthopedics. 2017
- [8] Perepelkin AI, Krajushkin AI. Dynamics of linear parameters of the foot of girls with increasing load. Bulletin of Volgograd State Medical University. 2013,2,25-27.
- [9] Perepelkin AI, Krajushkin AI, Smaglyuk ES et al. Study of the supporting surface of the foot in adolescence. Bulletin of new medical technologies. 2011:18,2,150-152.
- [10] Efimov AP. Informativeness of biomechanical gait parameters for assessing lower limb pathology. Russian Journal of Biomechanics. 2012,16,1,80-88.
- [11] Perepelkin AI, Mandrikov VB, Krajushkin AI. Influence of dosed load on changes in the structure and function of the human foot. Volgograd: Publishing House of Volgograd State Medical University. 2012,184.
- [12] Krishan K, Kanchan T, Sharma A. J Forensic Sci. 2011,56 (2),453-459.