

A Clinical Study Of The Incidence And Prevalence Of Salivary Gland Tumors In Zakho City

Hanan Abdulqader A. Dijwar^{#1} & Salih I.Ibrahim Naqid²

^{#1}Department of histopathology \zakho general hospital

²University of zakho \college of medicin\department of tissue of the body

Abstract: (*Background: The salivary glands have an important role in the functions of digestion by making lubrication fluid, respiration, speech, and overall homeostasis, and they also contain antibodies. Generally, the salivary gland tumors might be categorized into non inflammatory, inflammatory, and neoplastic swellings such as calculi, benign tumors like Warthin tumor, oncocytoma, pleomorphic adenoma, malignant tumors involving undifferentiated carcinoma, adenoid cystic carcinoma, and adenocarcinoma. Methodology: This epidemiological study is carried out at the Department of histopathology, Zakho general hospital, thirty salivary glands cases are involved in this work in a period of 15-years.*

Results: There are 30 patients with major salivary gland tumors, while 26 patients (86.666) had parotid and 4 patients (13.333) had sub-mandibular major salivary gland tumors. In the presented work, 26 (86.666) cases from a total of 30 salivary tumor cases have been benign, while only 4 (13.333) are malignant, from a total of 26 patents of parotid tumors, overall of 20(76.923) cases have been identified in superficial lobe, whereas only 6(23.076) cases have been in deep lobe, from a total of 30 salivary gland tumors, overall of 26(86.666) cases are pleomorphic adenoma and just 3 (11.538%) cases are mucoepidermoid carcinoma and only single case (3.333%) has been acinic cell carcinoma.

Conclusions: The parotid gland has been defined as the major site of origin which is related to benign as well as malignant tumors, also the pleomorphic adenoma is the major benign salivary gland tumor and mucoepidermoid carcinoma is the major common malignant tumor. The rest of the cases are autoimmune disease and minor salivary gland tumors.

Keywords: *Salivary gland tumors, parotid gland tumor, Pleomorphic adenoma, Mucoepidermoid carcinoma.*

INTRODUCTION

Salivary gland neoplasms (SGNs) can be defined as tumors created in the tissues of minor or major salivary glands. SGNs were infrequent lesions' heterogeneous group, with many biological features, which develop in the tissues of minor or major salivary glands [1]. There is no much information on SGN's total incidence in many regions because of the underreporting cases in the national cancer registries [2].SGN's global incidence was between 0.40 and 13.50 cases for every 100000 people and has an occurrence between 3 and 6% regarding all neck and head tumors based on a study [3].

There were up to 35 distinctive lesions classified via WHO as an SGN with the majority (ca. 65%–75%) of them indicated to be benign neoplasm [4]. Even though less frequent, Salivary gland carcinoma (SGC) representing a minimum of 24 distinctive histological subtypes,

which will make it challenging lesions' group for studying and developing treatment standards for [5]. The majority of publications provided a minor predominance in the females, yet the sex ratio is varying in many types of tumors [6]. Even though often inconclusive, diagnostic approaches like fine needle aspiration cytology (FNAC) were utilized for SGC [7], FNAC might experience sampling biopsy especially in the case when the tumor was in parotid's deep lobe [8], a few studies indicated cases that were related to tumor capsule seeding following the procedures of FNAC [9]. Other techniques for diagnostic imaging like computed tomography (CT), ultrasonography (US), and magnetic resonance imaging (MRI) were vital in diagnosing salivary gland tumor extent, location, and the existence of perineural invasion [10].

Generally, the salivary gland swellings are categorized into non-inflammatory, inflammatory, and neoplastic swelling such as calculi, benign tumors like pleomorphic adenoma, Warthin tumor, oncocytoma, malignant tumors that involve adenocarcinoma, undifferentiated carcinoma, and adenoid cystic carcinoma. In addition, connective tissue diseases such as lymphangioma, haemangioma neurofibroma, along with other autoimmune diseases like the Mikulicz disease, Sjogren's syndrome, and so on, salivary gland tumors showing different behavior [11]. The challenge of such tumors was further complicated in the management due to their bad economic condition, late presentation, and no health awareness among the general population. In addition, the salivary gland tumors were infrequent, including about (3-10%) regarding the neoplasm of the neck and head. Furthermore, the tumors' global incidence was 0.4-13.5 for every 100,000 individuals each year [3]. The main objective of this work is recognizing the incidence of many salivary gland tumours in Zakho

METHODS

The present retrospective study has been carried out at the Dept. of histopathology Zakho general hospital. Inclusion criteria: All the neoplastic swellings verified via biopsy or FNAC are involved. Exclusion criteria: Inflammatory, autoimmune, granulomatous swelling which involves the main salivary glands, and the neoplasm which involves the minor salivary glands have been excepted from the presented work. In the above study institutional ethical committee approval has been taken. From histopathology department of Zakho general hospital \head of the department \dr. qays ubaid. About 80% of salivary gland tumors were identified in the parotid gland and (10-15%) in the submandibular gland⁶. About 80% of parotid tumors as well as 50% of sub-mandibular tumors were benign. A study conducted by Thackray (1968)[12] provided a significant formula to express the incidence rate regarding such tumors in many anatomical regions. "For each 100 parotid tumors, there is 10 in submandibular glands, 20 in minor salivary glands, as well as one in sublingual glands".

RESULTS

In this work, there are 30 patients experiencing major salivary gland tumors, from that number, there are 26 patients experiencing parotid as well as 4 experiencing sub-mandibular major salivary gland tumors. Also, the maximum tumors' incidence was indicated in the third decade of life, while the next age incidence was indicated in the second decade (Table 1). Males have more susceptibility for developing malignant and benign parotid tumors compared to females (Table 2), swelling was the major presentation. Also, facial nerve paralysis has been indicated in 1 patient in the parotid gland malignancy. In this work, from 30 salivary tumor cases, there are 26 cases benign as well as 4 cases are malignant (Table 3). However, from the 26 parotid tumors' cases, there are 20 in the superficial lobe along with 6 were in the deep lobe, whereas from 30 salivary gland tumors, a total of 26 cases are

pleomorphic adenoma 3(13.05%) cases have been mucoepidermoid carcinoma, while a single case (4.35%) is acinic cell carcinoma (Table 4).

Table 1: Distribution of study subjects based on age.

Age group (years)	No. of Patient	%
0-10	0	0.00
11-20	1	3.33
21-30	11	36.66
31-40	10	33.33
41-50	4	13.33
51-60	2	6.66
61-70	2	6.66
Total	30	100%

Table 2: Distribution of study subjects based on gender.

Gender	No. of Patient	%
Male	17	56.67
Female	13	43.33
Total	30	100%

Table 3: Incidence of various salivary glands tumors by type.

Lesion	No. of Patient	%
Pleomorphic adenoma	26	86.67
Mucoepidermoid carcinoma	3	10.00
Acinic cell carcinoma	1	3.33
Total	30	100

Table 4: Incidence of various parotid S.G tumor

Parotid S.G tumor	No. of Patient	%
Superficial loob	20	76.92
Deep loob	6	23.08
Total	26	100

DISCUSSION

Salivary gland tumors consist of the morphologically diverse group related to uncommon tumors. In addition, their distinctive aspect of clinical presentation, morphologic configuration, and fairly unpredictable prognosis attracting considerable medical interests. The major patients' complaint with parotid gland tumors was the large swellings in the parotid region as well as below the ear lobe (Figure 1A). In our study most patients had been presented with swelling, Salivary gland tumors major presenting as painless enlarging mass gland tumor of parotid tumor as well as acinic cell carcinoma out of 4 malignant salivary gland tumors in present series. Furthermore, mucoepidermoid carcinoma has been defined as the major malignant salivary gland tumour of parotid [13].

The majority have been located in parotid glands and most have been benign. In minor and major salivary glands, pleomorphic adenoma is the most common type of tumor (Figure 2A). In the presented work, a total of 86.66% of patients experienced parotid tumors, while only 13.33% experienced sub-mandibular neoplasm (Figure 1B). Also, among parotid neoplasm, a

total of 20 cases are considered benign (Figure 3) and only 4 cases are malignant (Figure 2B). Pleomorphic adenoma is considered as the major benign salivary gland tumor identified in submandibular and parotid glands. The results have been indicated in this work, in which pleomorphic adenoma is the major benign salivary gland tumor at all locations. From the overall 26 pleomorphic adenomas in this work, most of them happened in the parotid gland (20 cases) succeeded by sub-mandibular gland (6 cases). In addition, the mucoepidermoid carcinoma can be specified as the major malignant salivary benign tumor typically showing no pain or other painful symptom which the patients don't care for, and thus, they present late to a concerned specialist[14,15].

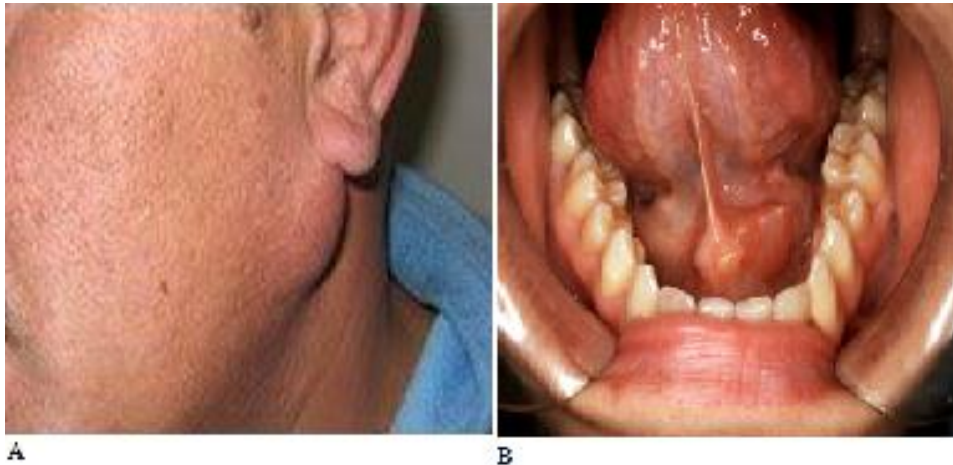

Figure (1): A) swelling in the parotid region and below the ear lobe clinical picture. B) Swelling in sublingual area clinical picture

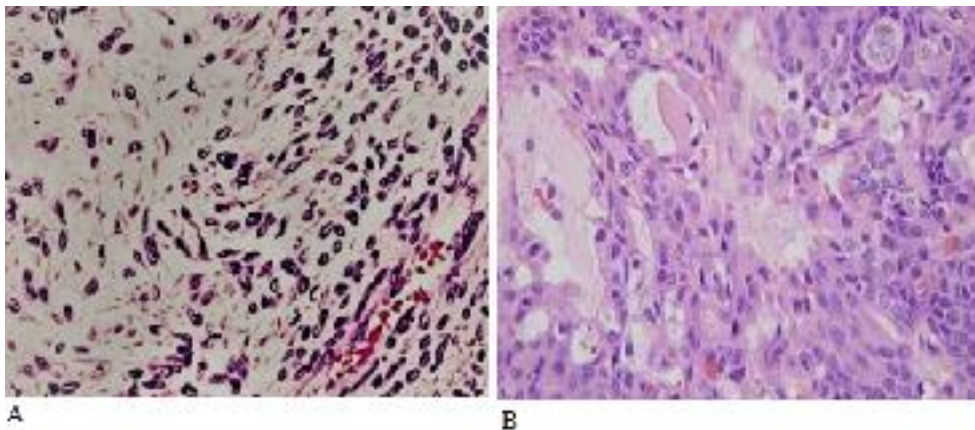


Figure (2): A) pleomorphic adenoma histopathological picture. B) mucoepidermoid Carcinoma histopathological picture

CONCLUSION

Salivary gland tumors are a subject of important interest as these are not very rare, have different histology and clinical features. The parotid gland can be defined as the major common origin site of malignant and benign tumors, pleomorphic adenoma is the major common benign salivary gland tumor, while mucoepidermoid carcinoma is the major common malignant neoplasm. The study suggested that increasing the awareness of the community regarding early referral of the parotid mass is vital, as surgical treatment in superficial parotidectomy from that is a vital process of treating these lumps. In addition, the surgery carried out via an experienced surgeon with distinctive interests in parotid surgery carrying minimal morbidity as well as surgery form the major treatment in salivary gland

tumors management because it serves therapeutic and diagnostic purposes, the general relative frequency regarding salivary gland tumors in such series correlate with that indicated in the majority of literature.

Funding: No funding sources

Ethical approval: This research has been approved by the Institutional Ethics \college of medicin\zakho university

REFERENCES

- [1] Ansari MH. Salivary gland tumors in an Iranian population: a retrospective study of 130 cases. *J Oral Maxillofacial Surg.* 2007;65:2187-94.
- [2] Jones AV, Craig GT, Speight PM, Franklin CD. The range and demographics of salivary gland tumors diagnosed in a UK population. *Oral Oncol.* 2008;44:407-17.
- [3] Ma'aita JK, Al-Kaisi N, Al-Tamimi S, and Wraikat Salivary gland tumors in Jordan: a retrospective study of 221 patients. *Croat Med J.* 1999;40:539-42.
- [4] Jaber MA. Intraoral minor salivary gland tumors: a review of 75 cases in a Libyan population. *Int J Oral Maxillofac Surg.* 2006;35:150-4.
- [5] Tian Z, Li L, Wang L, Hu Y, and Li J. Salivary gland neoplasms in oral and maxillofacial regions: a 23-year retrospective study of 6982 cases in an eastern Chinese population. *Int J Oral Maxillofac Surg.* 2010;39:235-42.
- [6] Bataskis JG, Regezi JA. The pathology of head and neck tumors: salivary glands. Part 1. *Head Neck Surg.* 1978;1:59-68
- [7] Saunders WB. *Paparella's Otolaryngology: Vol. III, 3rd Ed.* 1991;20:2099.
- [8] Wahiduzzaman M, Barman N, Rahman T, Khan ME, Islam MT, Bhuiyan MZ. Major Salivary gland tumors: A Clinicopathological study. *Journal of Shaheed Suhrawardy Medical College.* 2013;5(1):43-5.
- [9] Aggarwal P, Saxena S, Reddy V, Sharma P, Agarwal V. Demographics of salivary gland tumors: an institutional study in Western Uttar Pradesh. *Inter Oral-Med Sci.* 2015;13(2):75-80.
- [10] Araya J, Martinez R, Niklander S, Marshall M, Esguep A. Incidence and prevalence of salivary gland tumors in Valparaiso, Chile. *Medicina Oral, Patologia Oral Y Cirugia Bucal.* 2015;20(5):e532.
- [11] Rajdeo RN, Shrivastava AC, Bajaj J, Shrikhande AV, Rajdeo RN. Clinicopathological study of SGT
- [12] Shashikala V, Sonia Rani PB, Victor AJ. Clinicopathological study of salivary gland tumors. *Inter J Biomed Res.* 2016;7(9):621-3.
- [13] Adeola HA, Soyele OO, Adefuye AO, Jimoh SA, Butali A. Omics-based molecular techniques in oral pathology centred cancer: prospect and challenges in Africa. *Cancer cell international.* 2017 Dec;17(1):1-2.
- [14] D., Iseh, K. R., Sahabi, S. M., Amutta, S. M., Abdullahi, M., & Inoh, M. (2016). Pattern of Salivary Gland Tumor in Sokoto, North-Western Nigeria. *International Journal of Clinical Medicine*, 7, 347–35.
- [15] Leelamma JP, Mohan BP. Spectrum of primary epithelial tumors of major salivary glands: a 5 year record based descriptive study from a tertiary care centre. *Int J Adv Med.* 2017;4:5627.