

# Innovation Technique For Vasectomy, Vasovasostomy And Tissue Sampling For Experimental Studies Using A Rabbit Model.

Ali Thoulfikar A. Imeer<sup>1</sup>, K. A. Awad<sup>2</sup>, Rihab S. Zaki<sup>3</sup> and M. D. Tingari<sup>4</sup>

<sup>1</sup> Ali Thoulfikar A. Imeer: Assistant professor. Department of Anatomy, Faculty of Medicine, University of Al-Ameed, Karbala, Iraq, ORCID.0000-0003-0842-1072

<sup>2</sup> Khalid Amin Awad: Assistant professor. Department of Anatomy, Faculty of Medicine, University of Khartoum, P.O Box 102, Khartoum, Sudan. ORCID: 0000-0002-2751-5050

<sup>3</sup> Rihab Sidig ALZaki: Assistant professor. Department of Anatomy, Faculty of Medicine, International University of Africa, Khartoum, Sudan.

<sup>4</sup> Muddathir Dirdiry Tingari: Full professor. Department of Anatomy, Faculty of Veterinary Medicine, University of Khartoum, P.O Box 32, Khartoum North, Sudan

Email:<sup>1</sup>albassamali76@gmail.com,<sup>2</sup>khalid-alamina@uok.edu,<sup>2</sup>khalidalamina77@gmail.com.  
<sup>3</sup>rehabsidig25@yahoo.com,<sup>4</sup>muddathirtingari@yahoo.com

## ABSTRACT:

*This study aimed at developing a new technique of vasectomy, loupe-assisted vasovasostomy and tissue sampling hoping to achieve better results for experimental studies using a rabbit model. The technique described is typically helpful for anatomists undergoing similar research on animal model. The total number of rabbits used in this study was twenty-nine male rabbits of white New Zealand breeds. The animals were anaesthetized and bilateral vasectomy was carried out by ligation of the vas deferens at two points. The ligatures were put 1 cm apart. The suture material used was 4-0 nylon non-absorbable suture material. The segment between the two ligatures was excised and utmost care was observed to avoid damage to the blood vessels or sutures. Bilateral vasovasostomy was carried out after 16 weeks on 21 of the vasectomized animals (8 rabbits acted as control). One-layer method was adopted, using low power magnification spectacles (x 5) and non-absorbable suture material. Samples were obtained from vasovasostomized animals, under general anesthesia after, 24, 28, 32 and 36 weeks from the beginning of the experiment. The overall operation technique of loupe assisted modified one-layer technique was satisfactory and mean operation time was 70 - 100 minutes. The described technique is so clear that it could be adopted by other researchers intending to do similar work on vasectomy or vasovasostomy.*

**Key words:** Vasectomy, Vasovasostomy, loupe Assisted, vas deferens.

## 1. INTRODUCTION

Vasectomy is the occlusion of the vas deferens by surgical means and sometimes referred to as male sterilization (1). Vasectomy, also defined by the American Society for Reproductive

Medicine, as an elective surgical sterilization procedure for men that is intended to obstruct or remove a portion of both vasa deferentia, thereby preventing sperm from moving from the testes to the ejaculatory ducts (2). Vasovasostomy or vasectomy reversal involves rejoining of the two ends of the vas deferens, which was cut previously. As vasectomy is a reliable and popular method of birth control, the demand for vasovasostomy is increasing due to many causes like divorce and remarriage, death of children, economic causes and change of mind regarding parenting (3) Vasectomy is usually done in two steps; exteriorization of the vas deferens and then its division and further management. Exteriorization of the vas deferens can be done by scalpel or non-scalpel methods. After division of the vas, open –ended or close-ended vasectomy can be used, but the former was known to be associated with higher failure rates (4). Several techniques have been adopted to carry out vasovasostomy; these include macro-surgery, microsurgery, loupe –assisted, fibrin glue and robot-assisted (5-6) . Efficacy of these techniques varies in their patency, presence of sperms in the ejaculate and pregnancy rates following vasovasostomy. Macroscopic vasovasostomy is regarded as an effective mean of re-establishing fertility; it has satisfactory results, less cost and requires less skills(7) . Microsurgical techniques include two layers and modified one layer vasovasostomy. Lipshultz *et al* described in details a microscopic two layer technique for vasovasostomy together with pre- and post-operative preparations (9). Similarly, Silber gave comprehensive account on his 30 year experience in microscopic two layers vasovasostomy performed on more than 4000 patients(10). Fischer and Grantmyre (11) compared the outcomes of the two layer (in 23 men) and modified one layer (in 17 men) techniques; they concluded that modified one layer technique is simpler and faster with equivalent patency. Vasovasostomy can be more easier, faster and requires less expensive equipments with use of surgical loupes as reported by Hsieh *et al* (8). All of the above techniques have been carried out on human patients and were clinically oriented; we are presenting here our experience on rabbit model for experimental purposes.

## **2. MATERIAL AND METHODS:**

This is an experimental study with the initial experiments conducted on a domestic breed of rabbits. It turned out to be unsuccessful because of the narrow lumina of the excurrent duct system in general which is difficult to handle during vasovasostomy. We were fortunate when we reverted to the New Zealand bread which possess a much wider lumina and therefore we proceeded with our surgical procedure as detailed in the paper. twenty-nine sexually mature males of proven fertility weighing 2.5 – 3 kg were used in this study. Rabbit maturity was determined by age (about 6 months), examination of the genitalia and microscopic examination of semen samples. The animals were kept in separate cages under standard laboratory conditions, fed on dry straw and concentrated food, and given water ad libitum. The rabbits were kept in an air conditioned animal house of the Faculty of Pharmacy, University of Khartoum. They were left to adapt in the new environment for about one week at least before the commencement of the operation.

The total number of rabbits used in this study was 29, vasectomy was done on 29 rabbits, and after 16 weeks, vasovasostomy was carried out on 21 rabbits (8 rabbits acted as vasectomy control for anticipated morphological changes). Tissue samples were collected from different parts of the reproductive tract at different intervals following vasovasostomy. Subsequent treatment of tissues will be described in the appropriate sections.

## **3. OPERATION TECHNIQUE:**

**Vasectomy:** All operations were carried out under sterile conditions in the operative theatre of the Faculty of Medicine, University of Khartoum. The rabbits were anaesthetized by intramuscular injection of 1 ml (5 mg) of diazepam (Shanghai Pharmaceutical Co. Ltd. China) and 1 ml (50 mg)/kg of ketamine hydrochloride (Claris Lifesciences limited - India). They were then placed in a dorsal position with the fore and hind limbs being fixed to the operative table. The supra-pubic and lower abdominal areas were shaved and sterilized by Povidone – iodine. Local anesthesia was applied around operation site by spraying first and then infiltration with 5 ml of 2% Lidocaine hydrochloride (Pharmaceutical Solutions Industry – Saudi Arabia) in order to stop the protective reflex of the testis. Longitudinal skin incisions were made over both spermatic funiculi. The internal spermatic fascia was opened and the vas deferens, lying loose within the funiculi could be easily luxated leaving the scrotal contents in situ. Utmost care was observed to avoid damage of the accompanying blood vessels while applying blunt dissection to separate the contents of the cord. About 1 -2 cm long segment of the isolated vas deferens was carefully freed and two ligatures, 1 cm apart were applied using blue nylon 4 -0 (1.5 metric Johnson and Johnson). The two ligatures were connected together with 3- 4 cm of nylon suture (Fig.1), to facilitate subsequent identification of the two vas ends in vasovasostomy. The segment of vas deferens between the two ligatures was excised and utmost care was again observed to avoid damage to the blood vessels. The vas deferens was then repositioned underneath the funiculus. The fascia and overlying skin were sutured in layers with nylon 4-0 (4 metric Johnson & Johnson). Immediately after the operation, the animals were examined to ascertain that testis and accompanying epididymis and proximal part of the vas deferens remained free to move between the abdomen and scrotum. Following the operation, the rabbits were injected with prophylactic dose of long acting amoxicillin.

**Vasovasostomy (vasectomy reversal):** Bilateral vasovasostomy was carried out adopting the modified one layer anastomosis technique as the duration of surgery was considerably less than a two layer anastomosis (11). The rabbits were anaesthetized with the same protocol indicated above. Incision was done through the previous vasectomy site. The vas deferens was gently identified by its two ends suspended by the blue nylon. Both ends of the vas deferens were dissected out and the fibrous tissue was removed until normal lumina could be identified. Then the two loose ends were held together by bull-dog clamps which fixed the vas without crushing it (Fig.2). Vasovasostomy was done using low power magnification spectacles (x 5) and non-absorbable 45cm polypropylene suture material (monofilament, blue, 8-0, 6.5mm 3/8 circle taper point double needle). The needle was passed down through the wall of proximal part of duct, pierces to reach lumen, led to the other lumen of distal part of duct, and out again through the wall (Fig.3). The two ends of the duct were then apposed accurately and anastomosed with four interrupted sutures as mentioned above (Fig. 4). The mean operation time lasted for a period of about 140 -160 minutes. The vas was repositioned underneath the funiculus and the internal spermatic fascia and overlying skin were closed with polypropylene 4 -0 suture.

**Collection of samples:** At the end of the experiments, different parts of the reproductive tract were examined macroscopically to note the gross morphological features; size, shape...etc. before and after vasectomy and vasovasostomy. Samples were obtained from testes, epididymis, vas deferens and accessory glands under anesthesia (the same protocol indicated above). Samples from the accessory glands (prostate and bulbourethral glands) were obtained after the testes and epididymis were dissected out. The vas deferens act as a guide to the posterior wall of the urinary bladder. The prostate and bulbourethral glands

were identified by dissecting tissues between rectum and urinary bladder and removed en block together with the urinary bladder and urethra. Samples have been utilized for the preparation of routine histological, histochemical, ultra-structural and biochemical studies.

#### 4. RESULTS AND DISCUSSION:

The New Zealand rabbit is big in size and unlike the small domestic breed was found most suitable for experimental research on vasectomy and vasovasostomy. The operation technique involved an abdominal incision made on the inguinal supra-pubic area, through the abdominal skin and tunica vaginalis. This approach is in accordance with description of Flickinger (12), Miller *et al* (13) and Kong *et al.* (14). The overall one-layer method of vasovasostomy described by Fuse *et al.* (15) and Fischer and Grantmyer (11) has been adopted, but with the use of surgical loupes which proved to be satisfactory. Success of vasectomy was proved by coiling and tortuosity of the proximal segment of the vas deferens while the distal segment being narrowed (figure 5a). Post-vasovasostomy the vas deferens returned to almost normal size (figure 5b) compared to vasectomy proximal and distal segments shown in figure (5a) where the proximal segment showed turgidity and coiling. The size of the lumina post vasectomy also shows differences; the proximal being wider with thinner wall when compared to the distal segment (figure 2). After vasovasostomy the lumen of distal part of vas deferens started to show an increase in its diameter, with presence of intra luminal spermatozoa. Other methods (carried by other workers) were not described in details and we found difficulty to adopt what was carried out and how the method in question being approached. The mean operation time which lasted for 70 - 100 minutes is comparable to that of Flam *et al.* (16) who reported a mean operative period for bilateral vasovasostomy of 150 minutes. The use of long acting amoxicillin post-operatively proved to be helpful as the rabbits appeared healthy and there was no wound infection.

#### 5. CONCLUSION:

The described technique is simple detailed, doesn't take long time, and can be easily followed. It is typically suitable to adopt in experimental studies of vasectomy, vasovasostomy and sampling of genital organs.

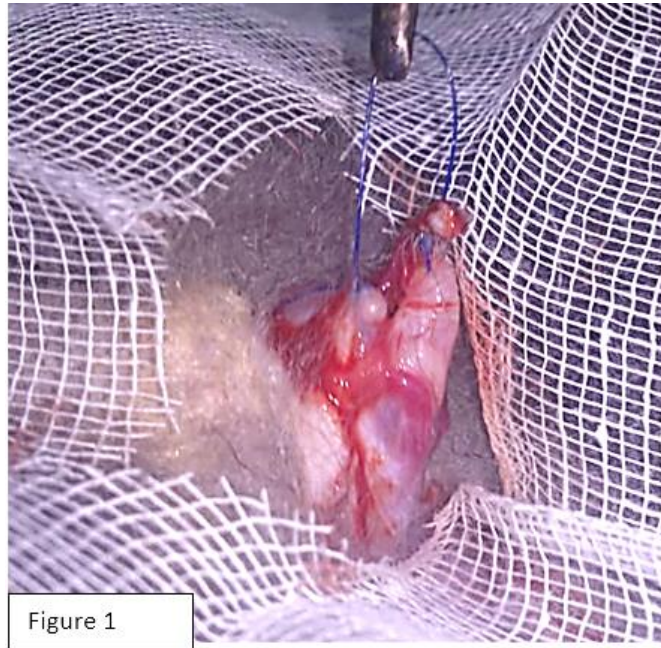#### 6. REFERENCES:

- [1] Farley T, Meirik O, Mehta S, Waites G. The safety of vasectomy: recent concerns. Bulletin of the World Health Organization. 1993; 71:413.
- [2] Practice Committee of American Society for Reproductive Medicine. Vasectomy reversal. Fertil steril. 2008;90: S78.
- [3] Banerjee AK, Simpson A. Reversing vasectomy. BMJ. 1992; 304:1130.
- [4] Michielsen D, Beerthuis R. State-of-the art of non-hormonal methods of contraception: VI. Male sterilisation. The European journal of contraception & reproductive health care: the official journal of the European Society of Contraception. 2010; 15:136-49.
- [5] Kuang W, Shin PR, Oder M, Thomas Jr AJ. Robotic-assisted vasovasostomy: A two-

layer technique in an animal model. *Urology*. 2005; 65:811-4.

- [6] Shekarriz BM, Thomas AJ, Jr., Sabanegh E, Kononov A, Levin HS. Fibrin-glue assisted vasoepididymostomy: a comparison to standard end-to-side microsurgical vasoepididymostomy in the rat model. *J Urol*. 1997; 158:1602-5.
- [7] Mason RG, Connell PG, Bull JC. Reversal of vasectomy using a macroscopic technique: a retrospective study. *Ann R Coll Surg Engl*. 1997:420-2.
- [8] Hsieh ML, Huang HC, Chen Y, Huang ST, Chang PL. Loupe-assisted vs microsurgical technique for modified one-layer vasovasostomy: is the microsurgery really better? *BJU international*. 2005; 96:864-6.
- [9] Lipshultz LI, Rumohr JA, Bennett RC. Techniques for vasectomy reversal. *The Urologic clinics of North America*. 2009; 36:375-82.
- [10] Silber SJ, Grotjan HE. Microscopic vasectomy reversal 30 years later: a summary of 4010 cases by the same surgeon. *Journal of Andrology*. 2004; 25:845-59.
- [11] Fischer MA, Grantmyre JE. Comparison of modified one- and two-layer microsurgical vasovasostomy. *BJU international*. 2000; 85:1085-8.
- [12] Flickinger CJ. Fine structure of the rabbit testis after vasectomy. *Biol Reprod*. 1975; 13:61-7.
- [13] Miller RJ, Killian GJ, Vasilenko P, 3rd. Effects of long- and short-term vasectomy on structural and functional parameters of the rat. *J Androl*. 1984; 5:381-8.
- [14] Kong LS, Huang AP, Deng XZ, Yang ZW. Quantitative (stereological) study of the effects of vasectomy on spermatogenesis in rabbits. *J Anat*. 2004; 205:147-56.
- [15] Fuse H, Kimura H, Katayama T. Modified one-layer microsurgical vasovasostomy in vasectomized patients. *Int Urol Nephrol*. 1995; 27:451-6.
- [16] Flam TA, Roth RA, Silverman ML, Gagne RG. Experimental study of hollow, absorbable polyglycolic acid tube as stent for vasovasostomy. *Urology*. 1989; 33:490-4.

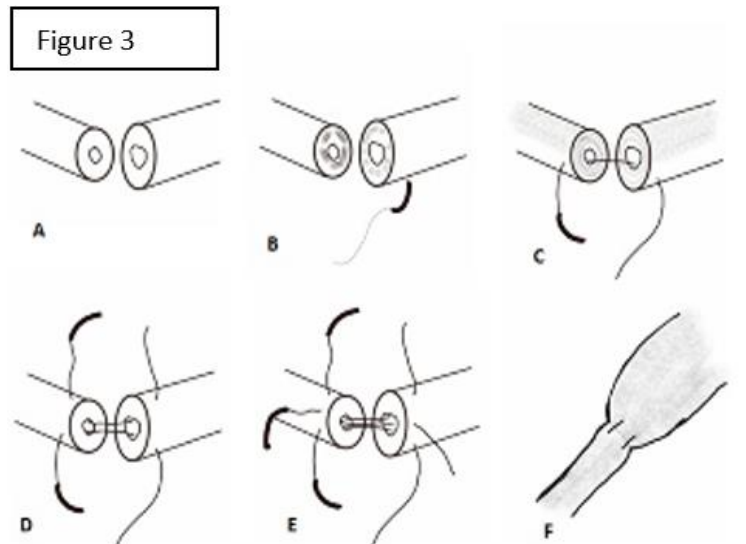
## Figure legends:



(Fig.1) Two severed ends of vas deferens: Note the two ligatures connected together with 3- 4 cm of nylon suture (held by the tissue forceps) to facilitate identification of the two ends during vasovasostomy.



(Fig.2) Two ends of the vas deferens ready to be reversed: They are aligned together by non-crushing bull-dog clamp. The two ends of the vas are different in thickness and diameter.



(Fig.3) diagrammatic representation of the steps undertaken in vasovasostomy: **A.** two ends approximated **B.** needle passed down through the wall of proximal part of duct which pierces to reach lumen, **C.** then led to the other lumen of distal part of duct ,and out again through the wall **D.** and **E.** other sutures done the same way **F.** the vas deferens after reversal.





Figure 4a

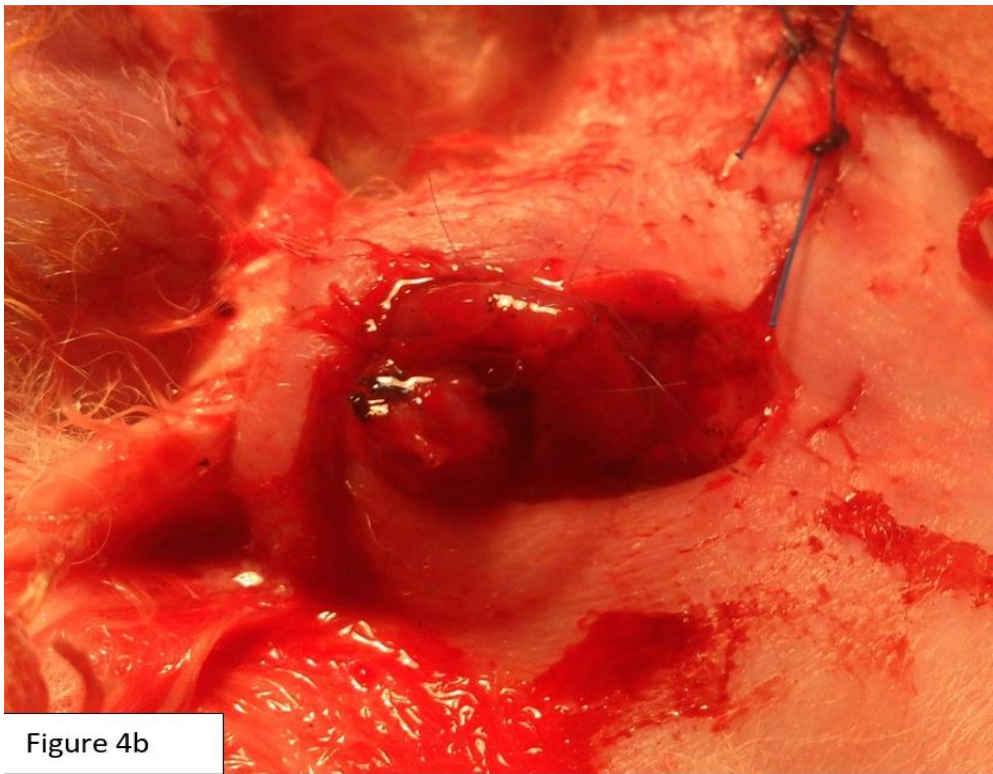
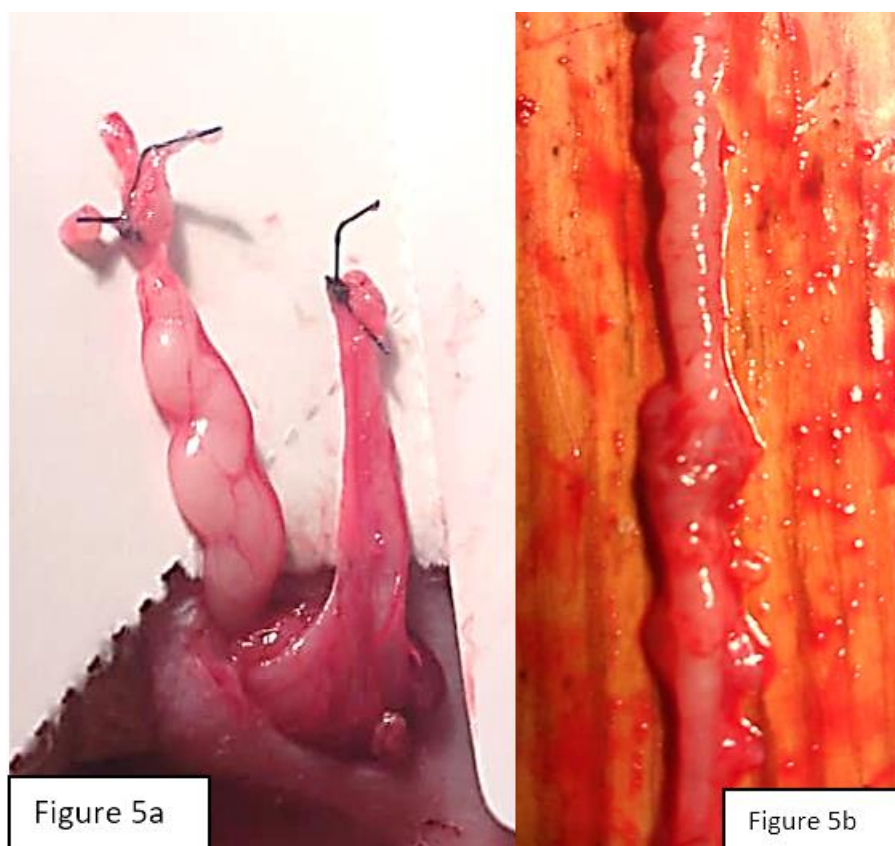


Figure 4b

(Fig.4) completed vasovasostomy: The two ends of the duct apposed accurately and anastomosed with four interrupted sutures in **a**: held by bull –dog and in **b**: ready to be internalized to the inguinal canal.





(Fig.5) **a.** Proximal and distal segments of the vas deferens post-vasectomy, the proximal segment showed turgidity and coiling. **b.** Post-vasovasostomy surgery with the vas deferens return to almost normal size.

*Declarations:*

*Ethical approval:*

All applicable international, national, and/or institutional guidelines for the care and use of animals were followed.

All procedures performed in this study were in accordance with the ethical standards of the Sudan Veterinary Council.

*Availability of data and materials:*

The datasets used during the current study are available from the corresponding author on reasonable request.

*Competing interest:*

The authors declare that they have no competing interests, neither financial nor non-financial.

*Funding:*

There are no funding bodies for this study other than the authors themselves.

*Authors` contributions*

*Ali.T. A. Imeer :Project development, data collection, manuscript writing and editing and data analysis.*

*Awad K.A.: Project development, data collection, manuscript writing and editing and data analysis.*

*Tingari M.D.: Project development, manuscript editing and data analysis.*

*Zaki R. S.: Data collection, manuscript editing and data analysis*