

Coexisting Adenocarcinoma Of Stomach With Hepatic Tubercular Granuloma.

Dr. Anita B Sajjanar

*Associate Professor Department of Pathology Datta Meghe medical college, Nagpur,
Maharashtra, India*

Dr. Obaid Noman,

*Associate Professor. Department of Pathology, Jawaharlal Nehru Medical College,
Datta Meghe institute of medical science, Sawangi, Maharashtra, India.*

Address for correspondence

Dr. Anita B Sajjanar

*Associate Professor Department of Pathology
Datta Meghe medical college, Nagpur, Maharashtra, India*

Abstract

Research on carcinogenesis is growing, possible correlation between cancer and other chronic illness is slowly being unveiled. Tuberculosis, one of the commonly occurring chronic granulomatous inflammation is considered as a risk factor for development of malignancy. The pathophysiology and practical implications of their co-existence have received little attention.

We present a case of elderly male, who was treated with antitubercular drugs thirty years ago for pulmonary tuberculosis. Recently patient presented with pain in the abdomen and loss of weight. Endoscopy of gastrointestinal tract showed ulceroproliferative growth involving pyloric region of the stomach with antral thickening. Cut section showing grey white growth with two adjacent ulcers. Gross examination of liver showed grey brown lobular mass in segment eight. Lymph node metastasis was seen in lesser and greater omentum. Special stains Mucicarmine & Alcian blue were positive but ZN stain for AFB was negative.

Pathologist needs to be aware of the coexistence of Koch's and malignancy as an uncommon event, maintaining a high index of suspicion for simultaneous and/or misleading presentations. Tuberculosis infection present in immunocompromised patient is well known. Present case highlights occurrence of tuberculous infection in the liver coexisting with gastric adenocarcinoma.

Keywords: *Hepatic, Gastric, Adenocarcinoma, Tuberculosis, Carcinogenesis*

INTRODUCTION

Research on carcinogenesis is expanding, possible correlation between chronic inflammation and cancer development is slowly being unrevealed. Tuberculous infection is considered as a risk factor for cancer development.

The pathophysiological and practical implications of their co-existence have received little attention. Chronic inflammatory condition creates a suitable microenvironment for the development of malignancy. Rapid diagnostic techniques such as Polymerase Chain Reaction (PCR) for tuberculosis should be considered in making the diagnosis.

Case report

A 68 year old male patient presented with history of fever, generalized weakness, pain abdomen, decreased appetite, weight loss and vomiting since 2 months. He is a known case of pulmonary tuberculosis treated with antitubercular drugs (ATT) about 30 years back. X-ray chest showed

scarred lesions on both the apices .Upper G I Endoscopy revealed ulceroproliferative growth over the pyloric region. CT scan of abdomen and pelvis showed stomach wall thickening and pyloric antrum narrowing.

Grossly partial gastrectomy with omentum specimen weighed 280gms(Fig. 1) Cut section showed greywhite growth measuring 30 X 2.5 X 2cm , adjacent to growth seen an ulcer with heaped up margin(Borrmann Type 3) and ulceroproliferative lesion measuring 4 X 4cms and 3.5 X 3cm respectively(Fig.2). Liver segment 8 showed greybrown lobular mass measuring 1.5 X 1.2 X 0.7cm.

Microscopy showed features of combined Diffuse& Intestinal types of infiltrating mucin secreting adenocarcinoma (Figs.3). Lymph nodes from lesser and greater omentum showed metastatic deposits. Sections from liver showed tubercular granulomatous lesion(Fig. 4). The special stains: Mucicarmin&Alcian blue are positive. The ZN stain for AFB is negative.

Discussion

The first published description of coexisting tuberculosis and carcinoma was by Bayle G I(1810).Indian authors have emphasized higher frequency of coexistence of these 2 lesions. It is said that factors that disturb host immunity increase susceptibility to active tubercular infection either endogenously or exogenously.^{1,2}

Tuberculosis and carcinoma may coexist at the same or different sites. The exact relationship between gastric carcinoma and hepatic granuloma is speculative. It is intricate to establish the possible cause and effect relationship. The development of mycobacterial infection in patients with immunosuppressed is well known.

Following 3 different types of association between tuberculosis and malignancy are described³

1. Development of carcinoma in the background of previous tuberculous infection. 2. Concurrent existence of TB and malignancy in the same patient or clinical specimens. 3. The diagnostic challenge - "Multifaceted presentation of these 2 disorders."

Possible correlation between these two conditions is slowly being unraveled. Tuberculosis is considered as a risk factor of development of carcinoma. However one should remember that the previous existence of tuberculosis may be merely a coincidental occurrence with cancer. Immunosuppression especially T cell defense mechanism is associated with mycobacterial infection.³Locally produced tumour peptides or antigen may also upset the milieu of granuloma and allow the TB organism to proliferate.²

A case of carcinoma stomach associated with isolated hepatic nodules of tuberculous origin treated earlier with antitubercular therapy (ATT) has been reported by Jayakumar J.⁴ Similar case of Isolated hepatic tuberculous pseudometastasis co-existent with adenocarcinoma of the stomach has been reported by Sen. M et al⁵ . Other related articles were reviewed ⁶⁻⁹ . Different studies on diagnostic modalities of tubercular lesions were reported ¹⁰⁻¹⁴ .

Abdomen is one of the common sites for extrapulmonary tuberculosis. The coexistence or predisposition of these 2 conditions is unclear and more challenging. Further research is required to determine tuberculosis or other similar chronic infection facilitating carcinogenesis.¹⁵⁻¹⁶

CONCLUSION

The pathologists and clinicians need to be aware of the coexistence of Koch's and malignancy as an uncommon event, maintaining a high index of suspicion for simultaneous and/or misleading presentations, as the lesions exhibit protean manifestations.

Present case is occurrence of Tuberculous infection in the liver (earlier a pulmonary lesion) coexisting with gastric adenocarcinoma.Detailed clinical, histopathological and microbiological evaluation should always be done. Synchronous hepatic TB and gastric adenocarcinoma is a rare finding and only a few reports are available in literature.

REFERENCES:

1. Jain B K , Chandra S S ,Narsimhan R, AnanthkrishnanN,Mehta R B. Coexisting TB and Carcinoma of colon. Aust N Z J Surg 1991;61: 828-31
2. Kaplan M H, Armstrong D,RosenP.Tuberculosis complicating neoplastic disease:A review of 201 cases cancer 1974; 33:850-8

3. M E Falagas, V D Kouranos et al. Tuberculosis and Malignancy .Q J Med 2010;103:p461-487
4. Jayakumar J :Isolated hepatic tuberculosis. Kathmandu Univ Med J (KUMJ). 2008 Jul-Sep;6(23):391-2.
5. García, E., Rey, P. del, &Martínez, E. “ Evaluationof blood processed by cell saver in pediatric scoliosis. *Journal of Medical Research and Health Sciences*, 3(6) (2020). <https://doi.org/10.15520/jmrhs.v3i6.193>
6. Sen M, Turan M, Karadayi K, Ugurlu L, Elagoz S .Isolated hepatic tuberculospseudometastasis co-existent with adenocarcinoma of the stomach; report of a case *ActaChir Belg*. 2004 Oct;104(5):601-3.
7. Dr.Anubha Singh, Dr.PreetiaishKaul (2018) Effectiveness of ManSure, a herbal reproductive health supplement, on semen quality (sperm count, sperm quality, sperm motility) in infertile men *International Journal Of Scientific Research And Education*.06,01 (Jan-18) 7788-91
8. Eman A Shakir, ZainabNazar (2017) Obesity increase the risk of carpal tunnel syndrome, *International Journal Of Scientific Research And Education*.05,04 (April-17) 6309-12
9. Jaiswal, N., J. Makrande, A. Bhake, and A.V. Bapat. “Ema, Vimentin, Desmin, Calretinin, e-Cadherin on Cell Block to Differentiate Adenocarcinoma Cells from Benign Reactive Mesothelial Cells.” *International Journal of Pharmaceutical Research* 11, no. 2 (2019): 1860–64. <https://doi.org/10.31838/ijpr/2019.11.02.213>.
10. Balwani, M.R., A. Pasari, A. Meshram, A. Jawahirani, P. Tolani, H. Laharwani, and C. Bawankule. “An Initial Evaluation of Hypokalemia Turned out Distal Renal Tubular Acidosis Secondary to Parathyroid Adenoma.” *Saudi Journal of Kidney Diseases and Transplantation : An Official Publication of the Saudi Center for Organ Transplantation, Saudi Arabia* 29, no. 5 (2018): 1216–19. <https://doi.org/10.4103/1319-2442.243965>.
11. Bawankule, S., S. Kumar, A. Gaidhane, M. Quazi, and A. Singh. “Clinical Profile of Patients with Hepatic Encephalopathy in Cirrhosis of Liver.” *Journal of Datta Meghe Institute of Medical Sciences University* 14, no. 3 (2019): 130–36. https://doi.org/10.4103/jdmimsu.jdmimsu_88_18.
12. Makhubele, H. D., &Bhuiyan, M. M. “ Primary Malignant Melanoma of the Breast: Mankweng Breast Oncology Experience. *Journal of Medical Research and Health Sciences*, 3(3), (2020), 900-902. <https://doi.org/10.15520/jmrhs.v3i3.185>
13. Garg, S., S. Vagha, and S.S. Khedkar. “Correlation of Clinical Presentation, Histopathology and Polymerase Chain Reaction for Diagnosis of Genital Tuberculosis at Rural Hospital.” *International Journal of Pharmaceutical Research* 11, no. 1 (2019): 1198–1202. <https://doi.org/10.31838/ijpr/2019.11.01.212>.
14. Kagoiyo, N. S., Wanjiku, M. S., &Kagoiyo, S. W. (2020). Evidence Based Health Demographic Assessment of URIRI Sub-County in Migori County, Kenya. *Journal of Current Medical Research and Opinion*, 3(08). <https://doi.org/10.15520/jcmro.v3i08.325>
15. Gupta, V., and A. Bhake. “Assessment of Clinically Suspected Tubercular Lymphadenopathy by Real-Time PCR Compared to Non-Molecular Methods on Lymph Node Aspirates.” *Acta Cytologica* 62, no. 1 (2018): 4–11. <https://doi.org/10.1159/000480064>.
16. Gupta, V., and A. Bhake. “Reactive Lymphoid Hyperplasia or Tubercular Lymphadenitis: Can Real-Time PCR on Fine-Needle Aspirates Help Physicians in Concluding the Diagnosis?” *Acta Cytologica* 62, no. 3 (2018): 204–8. <https://doi.org/10.1159/000488871>.
17. Sharma, S.K., and K. Dheda. “What Is New in the WHO Consolidated Guidelines on Drug-Resistant Tuberculosis Treatment?” *Indian Journal of Medical Research* 149, no. 3 (2019): 309–12. https://doi.org/10.4103/ijmr.IJMR_579_19.
18. Sharma, S.K., and A. Mohan. *Extrapulmonary Tuberculosis. Mycobacterium Tuberculosis: Molecular Infection Biology, Pathogenesis, Diagnostics and New Interventions*, 2019. https://doi.org/10.1007/978-981-32-9413-4_4.
19. SepidehMeshgi, Sahel ValadanTahbaz, HosseinYahyazadeh, MahsaMohammadzade, AbdollahNasehi, SaadatMolanaei. Synchronous Early Breast Cancer and Locally Advanced Primary Bladder Adenocarcinoma *International Journal of Current Research and Review*. Vol 12 Issue 10, May, 14-17

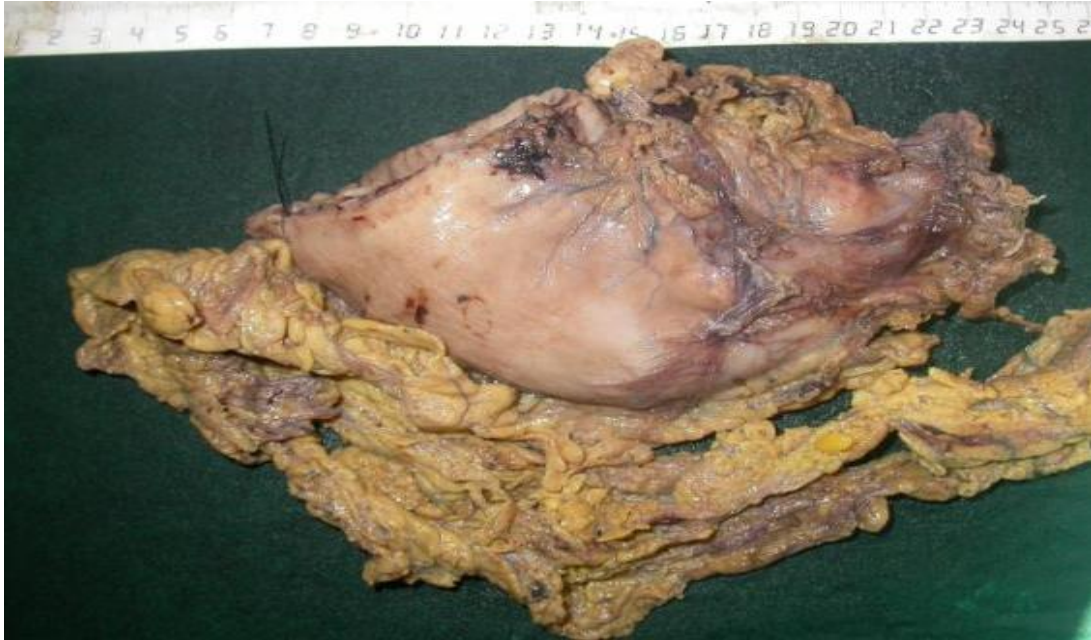

Figure 1-Partial gastrectomy specimen with omentum showing ill defined nodules

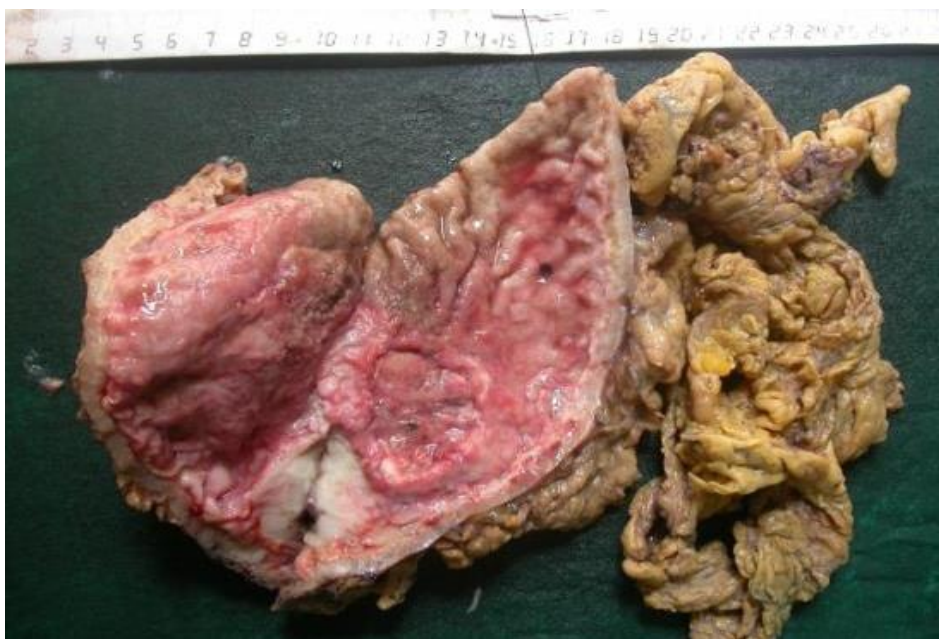

Figure. 2 Cut section showing greywhite growth: adjacent to it seen an ulcer with heaped up margin (Borrmann Type3) and ulceroproliferative lesion

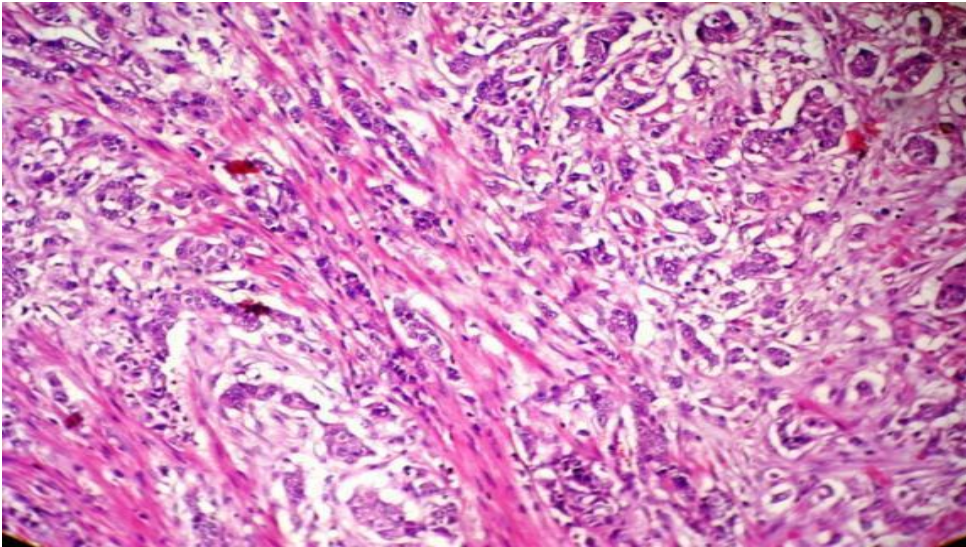


Figure 3 Diffuse type of infiltrating mucin secreting adenocarcinoma (H&Ex45X)

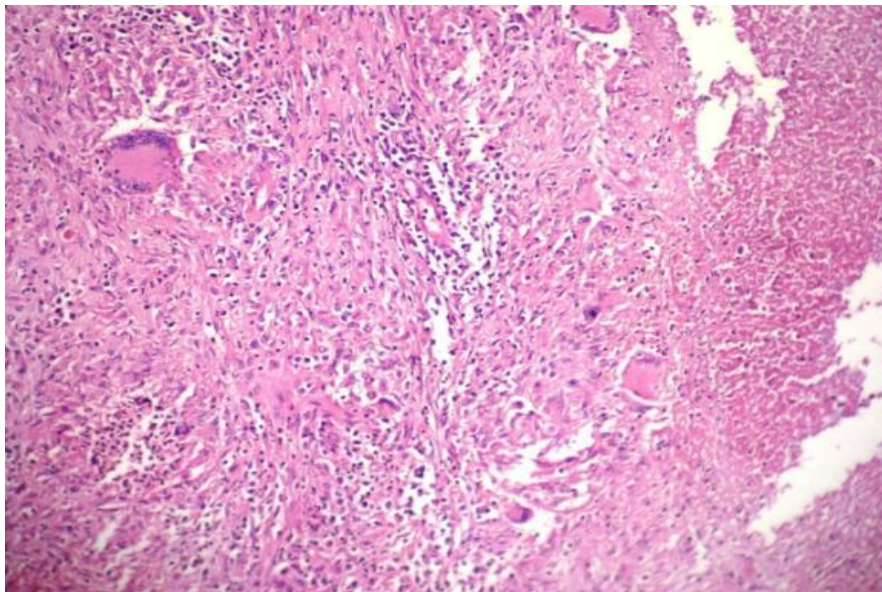


Figure .4Liver segment showing tuberculous granuloma (H&Ex45)