

Proboscis - A Case Study

Aiswarya Lekshmi RV¹, G Raju², K Chandrakumari³

¹ Assistant Surgeon, W&C Hospital, Thycaud, Thiruvananthapuram, Kerala, India

² Assistant Professor, Department of Anatomy,
Sree Gokulam Medical College & Research Foundation, Thiruvananthapuram, Kerala, India

² Research Scholar, Vinayaka Mission's Research Foundation
(Deemed to be University), Salem-636308, Tamilnadu, India

³ Professor and Head, Department of Anatomy,
Sree Gokulam Medical College & Research Foundation, Thiruvananthapuram, Kerala, India
¹rajugangadharakurup@gmail.com, ²aisuleks@gmail.com, ³kchandrakumari@rediffmail.com

Abstract: *Cyclopia or Holoprosencephaly is a type of defect of the forebrain of the embryo in which the right and left halves of Cerebral hemispheres, Thalamus and Hypothalamus are not fused. Scientists accept that various factors like gestational diabetes, exposure to chemicals or toxins may raise the risk of Cyclopia and other forms of Holoprosencephaly. For some infants with Cyclopia, origin recognized as change with a specific gene, their proteins act diversely influence the formation of brain. Recently existing as a result of birth with Cyclopia usually remain for about hardly any hours. In many instances, source unrevealed. Expecting here after that deformities could perhaps cured prior to gestation and Cyclopia able to be prevented.*

Keywords: *Cerebral hemispheres, Cyclopia, Gestational diabetes, Holoprosencephaly, Hypothalamus, Thalamus*

1. INTRODUCTION:

Cyclopia is a rare congenital anomaly known as Holoprosencephaly/ Alobar Holoprosencephaly occurs when forebrain does not cleave into two equal Cerebral hemispheres, Thalamus and Hypothalamus. One-third of babies with Cyclopia / other kind of Holoprosencephaly, cause identified as an abnormality with their chromosomes. Holoprosencephaly more common when there are three copies of chromosome 13.

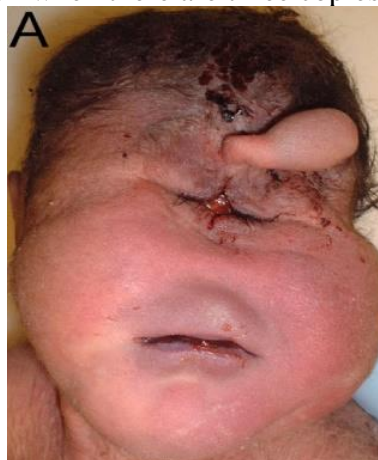

Fig.01: Proboscis in Patau syndrome. Cyclopia correlated in addition to having no nose as well as snout development over the eyeball.

(Photo Courtesy)^[65]

Other chromosome abnormalities identified as possible causes, too. Most obvious symptom of Cyclopia is single eye / partially divided eye, has no nose, but Proboscis can be above the eye. Cyclopia results in a miscarriage / stillbirth. After birth chance of survival usually few hours only. Cyclopia occurs in about 1 in 1,00,000 new borns (including stillbirths). Similar disease exists in animals. No way to prevent the condition and presently no treatment. A developmental abnormality in which there is only one eye generally exist together besides a congenital disorder involving insufficient division of the lobes of the brain. Optic abrasion nearby absolute Optic joining in a isolated orbit / as pair of eyeballs in a solitary orbit. Imperfections of Eye connect alongside a developmental abnormality in which there is only one eye involve a fissure of the Iris supposed to be a persistent embryonic cleft (coloboma), Retina and Optic nerve; in constant Optic nerve numbers any one / two is practicable as well as not present / uncommon Optic chiasma / Cyclopia take place once front / ventral segment of spinal column including next to chorda mesoderm insufficient in number; scarcity show to divergent entrance of prosencephalon substance accompanied by critical disturbance of median line Facial growth. Cyclopia is unusual in human beings familiar in sheep / livestock scraped at length California false hellebore (*Veratrum californicum*) by period 13.5 of pregnancy (**Fig.02**). Manage toxic exist steroidal alkaloids Jervine, Cyclopamine (11-deoxojervine) and Cycloposine. Various procedures of malformations of an embryo or a foetus were suggested: imperfect bones of the skull and face cartilage forming, reserved Calvary clover track waving including revise catecholamine liberate in the neuroepithelium of neural tube.

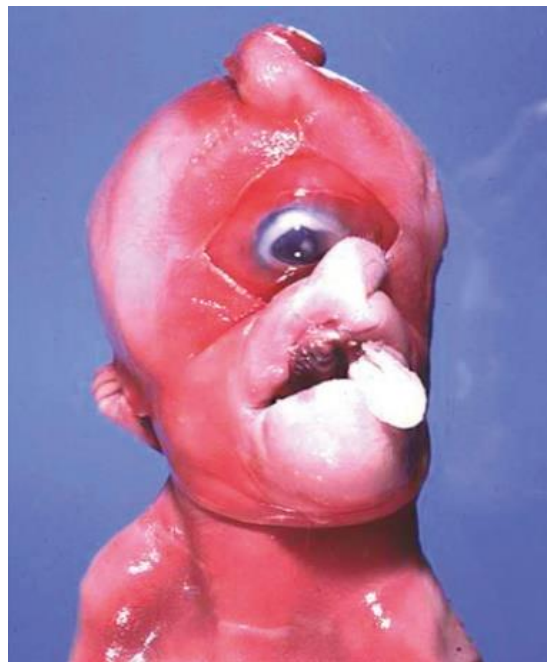

Fig.02: Cyclopia namely a Foetal hog

(Photo civility: Dr. John King,Ithaca, NY

Replicate from Haschek,W. M., Rousseaux,C.G., Wallig, M.A.(Eds.),2010.

Fundamentals of Toxicologic Pathology. Second ed., Academic Press, Fig.20.8,p.654 next to consent.)

In Teratology, Proboscis is a closed at one end, pipe-like formation, frequently detect in median of the Face. Regularly notice within serious configurations of Holoprosencephaly involve Cyclopia also generally outcome of rare growth of snout.

Chromosomes usually affected in cases of Proboscis are Chromosome 13 and 18.

Signs & Symptoms :

Expressing possibility differ much in scope along with seriousness, hang on quantity also position of past hereditary data including further components. Hardly any instances within which specific persons having Chromosome 18 Ring possess little / not any evident indications. Further having Chromosomal abnormality might have numerous characteristics.

1. Intellectual disability
2. Hypotonicity
3. Growth retardation / Malformations of Craniofacial region.
4. Affecting the Cranium and Face attributes **includes :-**
 - a. Microcephalus
 - b. Ocular Hypertelorism
 - c. Vertical skin folds may cover Epicanthal folds
 - d. Ptosis
 - e. Extremely curved roof of the mouth
 - f. Cavil model jaws
 - g. Depressed, deformed auricles including Stenotic / Atretic External acoustic meatus alongside connected auditory perception damage.

Other Physical abnormalities :

- i. Deficiency of Immunoglobulin A [IgA] assist build definite contaminations
- ii. Rib bone / Vertebral defects
- iii. Clinodactyly of fifth fingers
- iv. Webbing of neck
- v. Congenital Heart defects
- vi. Renal defects.

2. MATERIALS AND METHODS

During the period of January 2014 to July 2016 a study was managed by Sree Gokulam Medical College & Research Foundation, Thiruvananthapuram about the Foetal anomalies, Ultrasound and Autopsy comparative study. Detailed recording of the history of the patients were obtained in the form of a Proforma and Informed Consent for Autopsy from the parents were collected. Collected Foetuses and Placenta were obtained ranging from sixteen to twenty weeks of gestation were preserved in 10% formalin which is the fixative used.

3. OBSERVATION AND RESULTS

Proboscis

Among the Fifty specimens we studied, One case of Proboscis was detected.

Features of Foetus showed :

A Male baby with an unusual Congenital Facial anomaly.

- i. Snout like projection from the midline foetal face.
- ii. On examination, the structure was covered with healthy skin and subcutaneous tissue.
- iii. Ultrasound examination revealed Holoprosencephaly and Cyclopia.




Fig.03 : Foetus with Proboscis and Cyclopia

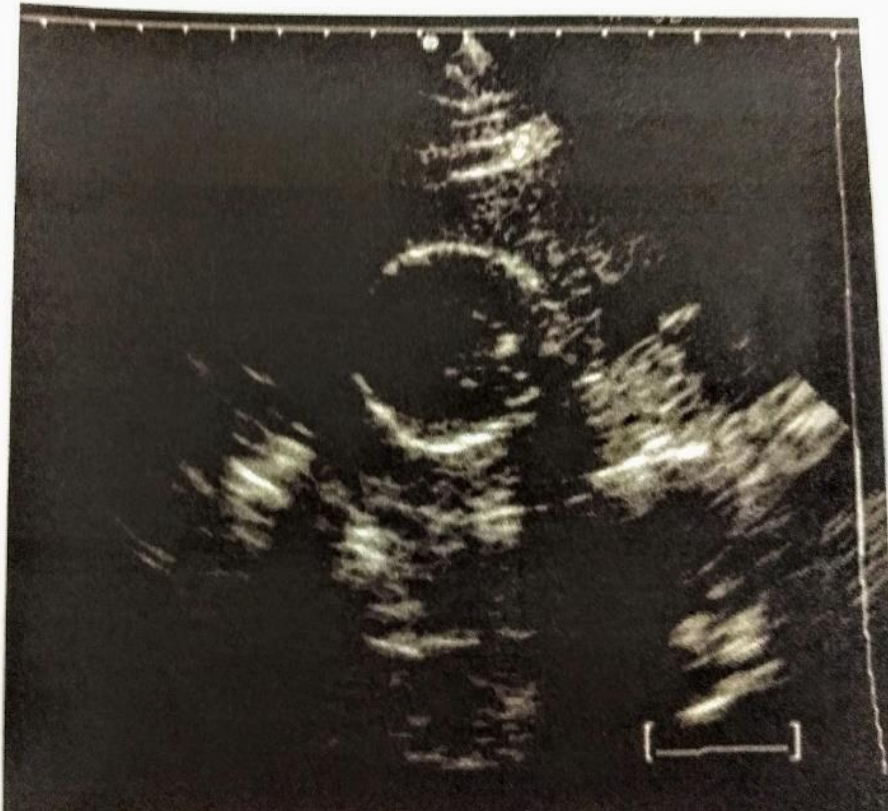


Fig.04 : Ultrasound picture shows Holoprosencephaly



Fig. 05 : Cyclops

Photo Courtesy : Dr. K. Chandrakumari, Professor & Head, Department of Anatomy Sree Gokulam Medical College & Research Foundation, Thiruvananthapuram, Kerala

4. DISCUSSION

TYPES OF PROBOSCIS

Holoprosencephalic Proboscis

Holoprosencephaly can be Ethmocephaly and Cebocephaly. In Ethmocephaly, pair unrelated Hypoteloric eyeballs exist related and congenital absence of the nose including snout arrangement above the eye. In Cebocephaly, no snout development take place, yet isolated nare snout is present.

Lateral Proboscis / Proboscis Lateralis / Lateral Nasal Proboscis

Rare Nasal anomaly. Tubular proboscis as formation constitute insufficient emergence of unilateral snout; establish alternatively of nares. Bulbus olfactorius generally primary about the side concerned during malformation. Tear passage, Os nasale, Nasal fossa, Vomer, Antrum of Highmore, Ethmoidal sinuses and lamina cribrosa of the ethmoid bone chambers frequently lost continuously those edge too. Ocular hypertelorism perhaps nearby.

Supernumerary Proboscis

Supernumerary Proboscis / Accessory Proboscis establish once the two nares set up including Proboscis also. Accessory Proboscis appear from being in excess of the usual relating to the sense of smell Placode.

Disruptive Proboscis

Disruptive Proboscis take place on condition that Hamartoneoplastic injury appear in Prosencephalon of foetus within its initial phases of growth.

Incidence :

Females further often compared to Males at a proportion of roughly **3:2**. Prevalence is 1 in 16,000 inborn animals with 1 in 200 within abort fetuses.^{[63][64]} Increased Parental age (age 32 years and 38 years, respectively).

Related Disorders :

- i.** Chromosomal disorders involving chromosome 13 and 18p (10% of individuals affected)
- ii.** Seizures
- iii.** Median cleft lip and Cleft palate
- iv.** Hypertelorism / Hypotelorism
- v.** Nasal abnormalities

5. CONCLUSION

Out of Fifty specimens One case of Proboscis was reported having similar features of Holoprosencephalic Proboscis. Congenital anomalies are practically more in Low Socio-economic group, Increase in Maternal age with History of Consanguineous marriages. Presence of Specific Chromosomal abnormality can be confirmed by Chromosomal analysis. To prevent the birth of Congenitally abnormal babies; role of Antenatal check up, Genetic counselling is very much essential.

Conflicts of interest

All authors have none to declare.

Acknowledgements

We acknowledge the contribution of Dr.Alex.K.Ittyavirah, Radiologist and Ultrasonologist, Ittyavirah Scan and Research Centre, Thiruvananthapuram and the faculties of the department of Anatomy.

REFERENCES

- [1]Barrow M V.1971, a quick history of Teratology to the first 20th century Teratology 4:119-130.
- [2]Harvey,Wolf,Von Haller & the Hunters. Grays Anatomy 38th Edition ELBS, Churchill Livingstone:3:333.
- [3]Gregg N M. 1941, Congenital cataract following German measles within the mother. Trans.Ophthalmol. Soc.Aust.3:35.
- [4]Lenz W, Knapp K..1962, Foetal malformation thanks to Thalidomide. Ger.Med.Mon.7:253.
- [5]Warkany J. 1965, Congenital Malformations: Notes &Comments. Chicago,Year Book Medical Publishers, Inc.
- [6]Globus M S, Hall B D, Filly RA,PoskanzerLB,1977.Prenataldiagnosis of achondrogenesis. J Paediatrics, 91;464.
- [7]Taylor K J W & McCready V R,1976. A Clinical evaluation of grey scale Ultrasonography. Br.J.Radiol.49:244-252.
- [8]Santosand & Duenheolter,1975.
- [9]Carr D H.1970. Heredity & the Embryo.Science J.6:75.
- [10]WilsonGJ.1973.Environment&BirthDefects.Academic Press, Newyork.

- [11]Persaud T V N.1979.Problems of Birth Defects.From Hippocrates to Thalidomide & after.Baltimore, University Park Press.
- [12]Isaksen C V, Eik-Nes S H, Blaas H G, Torp S H. Foetus & Infants with Congenital Urogenital system anomalies: correlation between prenatal ultrasound & postmortem findings. *Ultrasound. Obstet Gynecol* 2000;15:177-185.
- [13]Bhat B V , Babu L. Congenital malformations at birth a prospective study from South India; *Indian J Paediatr.*1998 Nov-Dec;65(6):873-81.
- [14]Chen-Chith J Sun, Kathryn Grumbach, Donna T. DeCosta,1999. Correlation of Prenatal Ultrasound Diagnosis and Pathologic Findings in Foetal Anomalies, *Paediatric & Developmental Pathology.* Vol, Issue 2:pp 131-142.
- [15]AntonssonP,SundbergA,KublickasM.2003.CorrelaionbetweenUltrasound&Autopsyfindin gsafter2ndTrimesterterminationsofPregnancy.*JPerinatMed.*2008;36(1):59-69.doi:10.1515/JPM.2008.005.
- [16]Sankar V H, Phadke S R. Clinical utility of Foetal autopsy and comparison with prenatal ultrasound findings. *Journal of Perinatology.*2006;26:224-29.
- [17]Zsanett Szigeti M D, Akos Csaba M D,Barbara Pete M D,2002. Correlation of Prenatal Sonographic Diagnosis and Morphologic Findings of Foetal Autopsy in Foetuses with mongolism .
- [18]A.Kaasen,J.Tuveng,A.Heiberg.2004.CorrelationbetweenPrenatalUltrasound & Autopsy findings: A Study of Second Trimester abortions. *Ultrasound .Obstet Gynecol;*28:925-933.doi:10.1002/uog.3871.
- [19]Myrte Maessen & Beatrice C.van der Matten.
- [20]HulyaAkgun,MustafaBasbug,MahmutTuncayOzgun.2007.CorrelationbetweenPrenatalUltrasound&FoetalAutopsyfindingsinFoetalanomaliesterminatedinthesecondtrimester.*Perinat.Diagn.*2007;27:457-62.doi:10.1002/pd.1710.
- [21]Taksande A,Vilhekar K,Chaturvedi P,Jain M.CongenitalmalformationsatbirthinCentralIndia:ARuralMedicalCollegeHospitalbasedata.
*IndianJHumGenet.*2010Sep;16(3):159-63.doi:10.4103/0971-6866.73412.
- [22]Mandeep Singh Bindra.2010. Congenital Malformation in Perinatal Autopsy. A Prospective Study.
- [23]Gagnon A. Society of Obstetricians & Gynaecologists of Canada Genetics Committee. Evaluation of Prenatally diagnosed structural congenital anomalies. SOGC Clinical Practice Guideline no. 234, September 2009. *J Obstet Gynaecol Can* 2009;31:875-81.
- [24]Zhara Abd-Alkader Taboo;2012.Prevalence and Risk Factors for Congenital Anomalies in Mosul City;The Iraqi Postgraduate Medical Journal:Vol 2, No 4.
- [25]Nayab Alia,Irshad Ahmed, Amir Hayat Mahais.Congenital Anomalies:Prevalence of Congenital anomalies in 2nd Trimester of Pregnancy in Madina Teaching Hospital, Faisalabad on gray scale ultrasound;2010;JUMDC, Vol.1,Issue 1, Jan-Jun 2010.
- [26]Rema Devi, Preetha Tilak, Sayee Rajangam;2007;Multiple Congenital anomalies- an aetiological evaluation;Bombay Hospital Journal.
- [27]Kulkarni M L. Congenital malformation. *Indian Paediatr* 1989;26:5-9.
- [28]Tomatir A G, Demirhan H, Sarkun H C, Kaksal A. Major Congenital anomalies: A Five year Retrospective Regional Study in Turkey. *Genet Mol Res* 2009;8:19-27.
- [29]Bai N S, Mathew E, Nair P M, Sabrinathan K. Perinatal mortality during a South Indian Poulation. *J Indian Med Assoc.* 1991;89:97-98.
- [30]Sharma A K. The Clinical Value of Perinatal Autopsy. *Indian Paediatr.* 1994;31:5-7.
- [31]Valerie Desilets, Luc Laurier Fetal and Perinatal Autopsy in Prenatally Diagnosed Foetal Abnormalities with Normal Karyotype;SOGC Technical Update;2011;No-267:1047-1057.

- [32]Wright C, Lee R E. Investigating Perinatal death: A Review of the choices when autopsy consent is refused. Arch Dis Child Foetal Neonatal Ed.2004;89:285-8.
- [33]Battaglia J. Paying our last respects: the neonatal autopsy as continuing care and ethical obligation. Neoreviews 2003;4:E207.
- [34]Lyon A. Perinatal autopsy remains the gold standard. Arch Dis Child Foetal Neonatal Ed 2004;89:F284.
- [35]Firestone F A;1945; The supersonic reflectoscope , an instrument of inspecting the inside of solid parts by means of sound waves. J. Acoust.Soc.Am.17:278-29.
- [36]Dussik T K;1942; On the likelihood of using ultrasound waves as a diagnostic aid. Neurol. Psychiat.174:153-168.
- [37]Howry D H;1958; Development of an Ultrasonographic diagnostic instrument. Am.J.Phys.Med.37:234.
- [38]Holmes J H, Howry D H, Posakony G J and Cushman C R;1954; The Ultrasonic visualization of sentimental tissue structures within the physical body .Trans.Am.Clin.Climatol.Assoc.66:208-223.
- [39]Wild J J and Reid J M;1957; Current development in Ultrasonographic equipments of diagnosis .IRE Trans.Ultrason. Engng.5:44-56.
- [40]Donald I;1975;Gray scale imaging in Sonar.Scot Med,J,20:177.
- [41]Kobayashi, Fleisher, Sample, Brown, Leopold, Filly, Sanders and Winsberg;1960.
- [42]Arthur C, Fleischer M D,Sandra G, Krihner M D and grey A, Thoma MD;1985;Prenatal detection of foetal anomalies with Ultrasonography. Paediatric Clinics of North America,Vol.32,No.6.
- [43]TanakaK,MiyajimaG,WagaiT,YasuuraM;1950;DetectionofIntracranialanatomicalabnormalitiesbyultrasound.TokyoMed.J.69:52.
- [44]Campbell S, Pearce J M;1983; U.S. visualization of congenital malformations. Br,Med.Bulletin;39:322-331.
- [45]Kanan Shah and C.A.Pensi; Study of incidence of Congenital Anomalies in New Borns; Gujarat Medical Journal;2013:Vol.68:No.2.
- [46]MohantyCetal;CongenitalAnomaliesinNewborn.Astudyof10,874consecutivebirth.J.MohannH,BhardwajS,BalA.CongenitalVisceralMalformationsRoleofPerinatalAutopsyindiagnosis.FoetaldiagnosisandTherapy2004;19:131-133.AnatomicalSocietyofIndia.1989,Vol.38,No.2.
- [47]MishraP C, Baveja R;Congenital anomalies in New borns A Prospective study. Indian Paediatrics, Jan.1989.Vol.26.
- [48]MohanH,BhardwajS,BalA.CongenitalVisceralMalformationsRoleofPerinatalAutopsyindiagnosis.FoetaldiagnosisandTherapy2004;19:131-133.
- [49]AiyarRR,AgarwalJR.ObservationonNewborn:AStudyof10,000consecutivelivebirths.Indian Paediatr 1969;6:729-742.
- [50]L Lomax, H Johansson, L Valentin. Agreement between Prenatal Ultrasonography and Foetal Autopsy findings: A Retrospective study of trimester terminations of pregnancy. Ultraschall Med 2012 Dec 29;33(7):E31-7.Epub 2012 Nov 29.
- [51]Cornelia Tennstedt,Rabih Chaoui, Rainer Bollmann;1997;Correlation of Prenatal Ultrasound Diagnosis and Morphological Findings of Foetal Autopsy.
- [52]Boyd P A, Tondi F, Hicks N R. Autopsy after termination of pregnancy for Foetal anomaly. A retrospective cohort study. Brit Med J 2004; 328:131-144.
- [53]S Acarturk, K Kivanc, E Atilla. Proboscis lateralis: evaluation of the anomaly and a review of two cases. Plastic and Reconstructive Surgery, June 2006 [3][permanent dead link]
- [54]UH Vyas, SC Raibagkar, HJ Vora. Proboscis lateralis-A 17 years follow up, a case report. Indian J Plastic Surg January–June 2003 Vol 36 Issue 1[4].

- [55] Jones KL. *Smith's Recognizable Patterns of Human Malformation*. 5th ed. Philadelphia, PA: W.B. Saunders Company; 1997:64-67.
- [56] Gorlin RJ, et al., eds. *Syndromes of the Head and Neck*. 3rd ed. New York, NY: Oxford University Press; 1990:52-53, 573-80.
- [57] Buyse ML. *Birth Defects Encyclopedia*. Dover, MA: Blackwell Scientific Publications, Inc.; 1990:381-83, 876-77.
- [58] Tsukahara M, et al. Familial del(18p) syndrome. *Am J Med Genet*. 2001;99:67-69.
- [59] Taine L, et al. 18p monosomy with midline defects and a de novo satellite identified by FISH. *Ann Genet*. 1997;40:158-63.
- [60] Velagaleti GV, et al. Familial deletion of chromosome 18 (p11.2). *Ann Genet*. 1996;39:201-04.
- [61] Gocke H, et al. The fetal phenotype of the 18p-syndrome. Report of a male fetus at twenty-one weeks. *Ann Genet*. 1988;31:60-64.
- [62] Carratu A, et al. Monosomy 18p syndrome with holoprosencephaly. *Minerva Pediatr*. 1983;35:1225-28.
- [63] *Taber's Cyclopedic Medical Dictionary*, ISBN 0-8036-0654-0
- [64] Leroi, Armand Marie *Mutants: On Genetic Variety and the Human Body*, p.73. ISBN 978-0142004821
- [65] Chan A et al- Chan A, Lakshminrusimha S, Heffner R, Gonzalez-Fernandez F. Histogenesis of retinal dysplasia in trisomy 13. *Diagn Pathol*. 2007 Dec 18;2(1):48 PMID:18088410 doi:10.1186/1746-1596-2-48.