

Case of Retroperitoneal Mass with Negative Biomedical Marker for Pheochromocytoma with Anticipated Difficult Airway

Dr. Shilpa Deshmukh¹, Dr. Girish Saundattikar² Dr. Balkees Nazeer³, Dr. Dheeraj Ravindran⁴

- 1- Assistant Professor, Department of Anaesthesiology, Dr. D. Y. Patil Medical College, Hospital & Research Centre, Dr. D. Y. Patil Vidyapeeth, Pimpri, Pune 411018, Maharashtra, India
- 2- Professor and HOD, SKN Medical College & General Hospital, Narhe, Pune. Affiliated to MUHS, Nasik.
- 3- Junior Resident, Department of Anaesthesiology, Dr. D. Y. Patil Medical College, Hospital & Research Centre, Dr. D. Y. Patil Vidyapeeth, Pimpri, Pune 411018, Maharashtra, India
- 4- Junior Resident, Department of Anaesthesiology, Dr. D. Y. Patil Medical College, Hospital & Research Centre, Dr. D. Y. Patil Vidyapeeth, Pimpri, Pune 411018, Maharashtra, India

Corresponding Author

DR. BALKEES NAZEER

Junior Resident, Department of Anaesthesiology, Dr. D. Y. Patil Medical College, Hospital & Research Centre, Dr. D. Y. Patil Vidyapeeth, Pimpri, Pune 411018, Maharashtra, India

Abstract

Pheochromocytomas are catecholamine secreting tumours that arise from chromaffin cells of the sympathoadrenal system. They account for fewer than 0.1% of all cases of hypertension in adults but have lethal potential and are one of the few truly curable forms of hypertension. The symptoms with the greatest “pooled sensitivity” are hypertension, headache, palpitation, and diaphoresis. The diagnosis is based on these symptoms and high levels of plasma-free normetanephrine and/or metanephrine. This report is of the successful anaesthetic management of a 40-year-old female, a known case of hypertension for 10 years, with only low back ache, and vomiting as her presenting complaints, posted for excision of a retro-peritoneal mass, whose intraoperative tumour manipulation led to a hypertensive crisis, showing its true colours! The histopathological report of resected specimen, obtained post-operatively, came to be consistent with pheochromocytoma. A high level of clinical suspicion of pheochromocytoma in such cases will turn out to be the saviour of the day, by prompting us to meticulously evaluate, appropriately optimise and adequately prepare for any intra-operative events in an otherwise “simple case abdominal mass excision!”

INTRODUCTION:

Pheochromocytoma (PCC) and paraganglioma (PGL) are rare neuroendocrine tumors that arise from chromaffin cells in the adrenal medulla. The 2014 Endocrine Society Clinical Practice Guidelines state an overall PCC prevalence of 0.2-0.6% in patients with hypertension. In addition, they suggest that the prevalence of familial and extra adrenal tumours in patients carrying germ-line mutations in PCC susceptibility genes may be as high as 50%. They account

for fewer than 0.1% of all cases of hypertension in adults but have lethal potential and are one of the few truly curable forms of hypertension.

Once diagnosed as PCCs, their removal can prevent lethal complications like hypertensive crises. Main aims of anesthetic management include proper preanesthetic checkup, intraoperative fluid management as well as management of complications like hypertension and posttumor removal hypotension. The chief presenting complaints are fluctuating blood pressure (BP), sweating, and palpitations. Catecholamine release, if not controlled, can result in severe hypertension, cerebrovascular, and myocardial complications. This patient group poses a challenge to anesthesiologists in managing them intraoperatively as well as in ICU.

Here, we report a case of clinically undiagnosed pheochromocytoma for surgical resection. We discuss the preoperative evaluation, intraoperative management, and postoperative care of patients who will undergo resection of pheochromocytoma.

CASE REPORT:

A 41-year-old female with complaints of lower abdomen pain and lower backache, nausea, and vomiting for a duration of 2 days. She was a known hypertensive for 10 years and was on regular treatment with T. Amlodipine 5mg OD. On admission, her BP was >180/110 mm of Hg for which Inj. NTG IV infusion was started. During this episode of hypertension, the patient had complaints of palpitation. CECT (A+P) revealed right paraaortic retroperitoneal mass (46x30x35mm) compressing and displacing the IVC as well as abutting the left renal vein and right renal artery and a small right kidney (66x24x26mm). (**Figure 1 &2**) Considering the patient's presentation of hypertension and the CT findings, plasma metanephrine, and urine vanillyl mandelic acid levels were assessed which were surprisingly normal thus excluding the diagnosis of pheochromocytoma. However, the patient was posted for exploratory laparotomy with excision of the right retroperitoneal mass. Pre-anaesthetic check-up revealed restricted mouth opening and Mallampati classification IV, along with hypertension and tachycardia. Dental opinion was obtained and diagnosed with grade 2 oral submucosal fibrosis. Cardiac opinion was obtained for optimization. Pre-op optimization was done with the addition of alpha blocker T. Prazosin 5mg OD and beta blocker T. Metoprolol 25mg BD and the patient was taken for surgery under ASA III after obtaining high risk, SICU and Ventilator consent adequate blood and blood products reserved and the advice to continue antihypertensives on the day of the surgery. Appropriate counseling and consents were taken for epidural catheterization, central venous cannulation, arterial line insertion and awake fiberoptic intubation i/v/o oral submucosal fibrosis grade II. In Pre-op OT preparation, all the emergency drugs and equipment's were kept ready because of our high level of suspicion for a hypertensive crisis and major blood loss and anticipated difficult airway. Baseline heart rate and blood pressures on the day of surgery were 100 bpm & 158/90 mm of Hg. Epidural catheter insertion for intra and postoperative analgesia was secured in sitting position under all aseptic precautions with 18G Touhy's Epidural kit. Awake fiberoptic intubation with minimal pressor response was a challenge. This was tackled by bilateral superior laryngeal nerve block, transtracheal nerve block, spray-as-you-go technique with 2% Lignocaine, and IV Fentanyl. Following the securing of airway with oral endotracheal tube, patient was induced with Inj. Propofol 2mg/kg and neuromuscular blockade was achieved with Inj. Vecuronium with initial dose of 0.1mg/kg followed by 1/4th the dose of Inj. Vecuronium as maintenance doses. Anaesthesia was maintained with O₂ 50%/AIR and Sevoflurane. Post induction vitals were

within 20% of baseline. Arterial line and CVC secured for IBP and CVP monitoring. Intra-operatively, the tumor was confirmed to be arising from the adrenal gland. Hence, right adrenalectomy and right nephrectomy were planned intra-op. Tumor manipulation led to a hypertensive crisis with BP > 300/160 mmHg, which was effectively managed with the prompt initiation and titration of Inj. NTG, then Inj. Sodium Nitroprusside and Inj. Labetalol IV infusions. Post tumor ligation, hypotension (80/40 mm of Hg) was managed with fluids and boluses of IV mephentermine. Upon completion of the surgery, the patient was extubated uneventfully and shifted to SICU hemodynamic monitoring and observation. The patient was kept in the ICU for 2 days and later shifted to the ward uneventfully. The histopathological report of the resected specimen was consistent with pheochromocytoma.

DISCUSSION:

Pheochromocytoma is suspected in one/more of the following situations ⁽²⁾, Hyperadrenergic spells presenting as hypertension, headache, palpitation, and diaphoresis or Familial syndromes (e.g. – MEN2, NF1, VHL) or Family history of pheochromocytoma. While Biochemical confirmation is by Plasma metanephrines and 24-hour urine metanephrines diagnosis is by Localization of the adrenal mass in Abdominal/adrenal CT/MRI with ⁶⁸GA DOTATATE PET/CT & ¹²³I-MIBG Scintigraphy. In our case it was only the clinical suspicion based on presenting history and symptoms, as biochemical markers were not in favor and imaging studies were inconclusive. In such scenario's anticipation, vigilance and preparedness of the anesthetist is warranted to handle any crisis.

routine findings in preoperative echocardiograms include moderate to severe left ventricular hypertrophy in conjunction with varying degrees of diastolic dysfunction that correlate with the severity, duration, and degree of blood pressure control. Catecholamine cardiomyopathy has been well described (catecholamine-induced cardiomyopathy)^[3] Pre-operative optimization was adequately done by increasing fluid & salt intake and restoring volume status, normalizing BP and HR. Preoperative optimization helps in preventing the wide variation in arterial BP during the intraoperative period. This is achieved by antiadrenergic drugs, i.e., alpha (α) and beta (β) blockers. The sympathetic blockade is achieved first by an α adrenergic blocker followed by an α - β blocker. Alpha blockade results in vasodilatation and tachycardia which is controlled by beta blockers. If beta blockade is achieved first, then there may be unopposed vasoconstriction in skeletal muscles causing hypertension ^[4]. α -Adrenergic blockade should be started 10- 14 days prior to surgery and agents used are Nonselective – Phenoxybenzamine or Selective – Doxazosin, Prazosin ⁽⁵⁾.

β -adrenergic blockade is initiated, once adequate α -blockade is achieved as per Roizen's criteria ⁽⁶⁾ Adequate α blockade is established once there is no in-hospital blood pressure >160/90 mmHg for 24 h prior to surgery or No orthostatic hypotension with blood pressure <80/45 mmHg or No ST or T wave changes for 1-week prior to surgery or No more than 5 premature ventricular contractions per minute.

Our intraoperative management goals were to Avoid histamine & catecholamine-releasing drugs and pressor responses due to anesthetic techniques. Prevention of sympathetic responses is essential for smooth induction especially in high risk patients, i.e. patients with hypertension, rhythm disturbances, myocardial ischemia, raised ICP etc. Various strategies have been developed for combating these responses targeting different levels of the sympathetic reflex pathway.⁵ The methods used can either (a) block the afferent pathway- superior laryngeal

nerve block via topical application or infiltration of local anesthetic; (b) block the central mechanism of integration and sensory input via opioids etc; or (c) block the efferent pathway and effector sites - beta blockers (BB), calcium channel blockers (CCB), lignocaine etc.^[7] Hypertensive crises are generally managed with a vasodilator, while tachyarrhythmias, including the reflex tachycardia seen with the use of many vasodilators, are controlled with β -blockers. β -Blockers also minimizes the excessive inotropy seen with epinephrine-secreting tumours.^[8] Management of Hypotension post tumor excision was with Fluids – Crystalloids & colloids and Vasopressin

CONCLUSION:

Major catastrophic cardiac events are significantly more likely to occur in pheochromocytoma patients throughout the perioperative phase. Careful preoperative optimization, precise intraoperative planning, and Hemodynamic management are necessary for successful treatment. In cases where the blood and imaging investigation criteria are unable to diagnose pheochromocytoma conclusively, clinical suspicion and preparation for the same would help prevent otherwise unforeseen complications.

References

1. Aygun N, Uludag M. Pheochromocytoma and Paraganglioma: From Epidemiology to Clinical Findings. *Sisli Etfal Hastan Tip Bul.* 2020 Jun 3;54(2):159-168.
2. Jacques W. M. Lenders, Quan-Yang Duh, Graeme Eisenhofer, Anne-Paule Gimenez-Roqueplo, Stefan K. G. Grebe, Mohammad Hassan Murad, Mitsuhide Naruse, Karel Pacak, William F. Young, Jr, Pheochromocytoma and Paraganglioma: An Endocrine Society Clinical Practice Guideline, *The Journal of Clinical Endocrinology & Metabolism*, Volume 99, Issue 6, 1 June 2014, Pages 1915–1942
3. Kassim TA, Clarke DD, Mai VQ, Clyde PW, Mohamed Shakir KM. Catecholamine-induced cardiomyopathy. *Endocr Pract* 2008;14:1137-49
4. Amod KS, Taskeen F, Murthy KTV, Sahajananda H. Anesthetic Management of Pheochromocytoma. *J Med Sci* 2019;5(1): 11–13
5. Ramakrishna H: Pheochromocytoma resection: Current concepts in anesthetic management. *J Anaesthesiol Clin Pharmacol* 2015; 31: 317–23
6. M. F. Roizen, R. W. Horrigan, M. Koike, E. I. Eger, M. F. Mulroy, B. Frazer, et al; A prospective randomized trial of four anesthetic techniques for resection of pheochromocytoma. *Anesthesiology* 1982; 57:A43
7. Bhardwaj N, Thakur A, Sharma A. A review of various methods for prevention of pressor response to intubation. *International Journal of Research and Review.* 2020; 7(7): 360-363
8. David Connor, Stephen Boumphrey: Perioperative care of phaeochromocytoma, *BJA Education*, Volume 16, Issue 5, May 2016, Pages 153–158

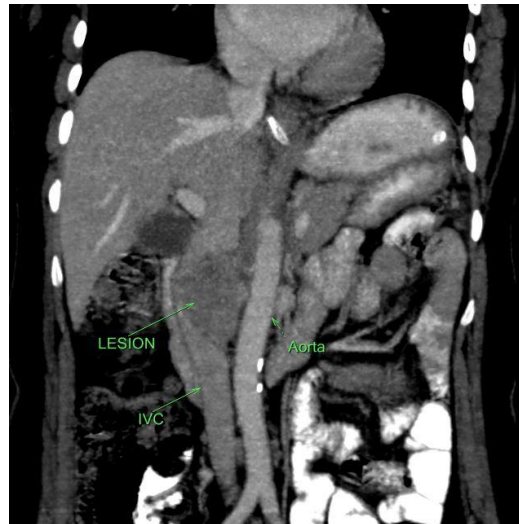


Figure :1 LEISON IN CECT ABDOMEN

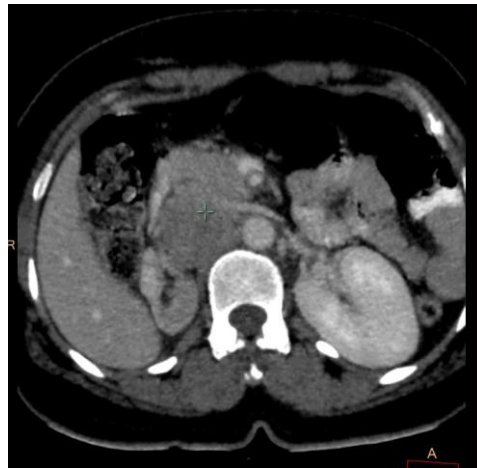

FIGURE: 2. LEISON IN CECT ABDOMEN