

The Research Of Different Methods Efficiency Of Posttraumatic Valve Defects Plasty

A.M. Mamadaliev¹, M.A. Aliev², K. Dj. Saidov³

^{1,2,3}“Neurology and Neurosurgery” department Samarkand state medical institute

1. INTRODUCTION

Cranio-cerebral injury (CCI) is an urgent problem accounting for 35-40% of all injuries in peacetime. In associated injuries, the CCI proportion reaches 70-72%. Clinical and neurological symptoms in CCI in general and in post-traumatic skull defects in particular are varied. These patients have cerebral, focal, vegetative-somatic symptoms, and some patients have epileptic seizures [3,4,6].

Since ancient times, doctors have been dealing with the post-traumatic defects closing and restoring the cranial vault integrity problem, and until now, researchers are developing various plasty methods of skull defects and finding the best method for fixing the graft [1,2,5].

When carrying out restorative treatment, it is optimal to eliminate or completely compensate for the damage, and with a trepanation defect in patients with severe traumatic brain injury consequences, pathogenetic therapy should be started with its plastic closure [4,8,9,10].

The optimal characteristics for any fixation system are biological material inertness, fixation reliability, lack of displacement between the graft and the cranial vault, ease of use, and moderate the construction cost, lack of artifacts during neuroimaging, neurophysiological or any other research methods. None of the known graft fixation methods to date satisfies all these requirements to a sufficient extent [7, 10, 11, 12, 13].

The skull defect presence, especially an extensive one, leads to the organic and functional disorders development of the brain structures, impaired hemo- and cerebrospinal fluid dynamics in the brain. At the same time, the danger of traumatizing an unprotected brain from the outside increases significantly [1,3,4,10].

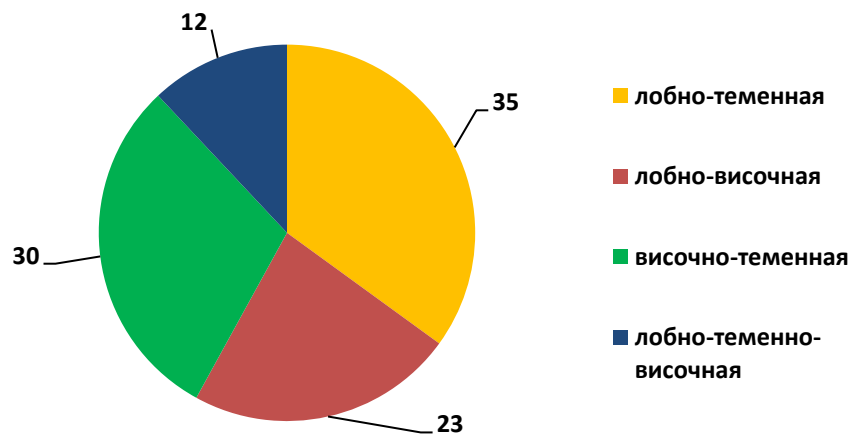
Considering the above, in this work, we set ourselves the goal of investigating the clinical and neurological symptoms significance and assessing the using various methods effectiveness of post-traumatic cranial vault defects plasty.

2. MATERIAL AND METHODS

This work is based on the analysis of 60 patients surgical treatment results with post-traumatic defects of the cranial vault bones (PTDCVB) of various localization who were hospitalized in 1st clinic neurosurgical department of Samarkand state medical institute in the period from 2017 to 2019 and archival material from 1992 to 1995.

Among the analyzed patients, men predominated - 45 (75.0%) and 15 (25.0%) women. All patients had a TBI history. In 48.5% patients, the skull defect was localized in the fronto-parietal region, in 42.9% in the frontotemporal region, in 56.4% in the temporoparietal region, and in 8.6% patient in the fronto-parietal-temporal region (Fig. 1). According to the skull defects size, the patients were divided into 3 groups: small - up to 10 cm² - in 24 (40%) patients, medium - up to 30 cm² in 32 (53.3%) patients and large - up to 60 cm² in 4 (6.7 %) patients.

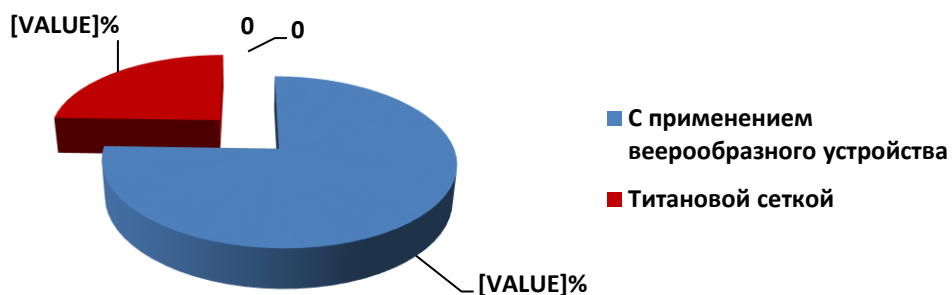
Fig. 1. The cranial vault defects localization



Out of 60 patients with PTDCVB, 53.3% underwent autoplasty of the cranial vault bones defects using a fan-shaped titanium device, in 46.7% patients alloplasty was performed using a titanium mesh (Fig. 2.).

All patients underwent a comprehensive examination, including clinical neurological, laboratory, and X-ray with the use of modern neuroimaging research methods (MSCT with 3D skull reconstruction and MRI).

Fig. 2. Distribution of patients by skull defects plasty methods.



3. RESULTS AND DISCUSSION.

Various clinical and neurological disorders were observed in both patients groups in the preoperative period.

The neurological picture of trepanned skull syndrome (TSS) included cephalgia (98.4%), meteorological stability (88.4%), decreased ability to work (47%), decreased memory (72%), impaired intellectual function (38%), bulging subject to brain tissue in the trepanation window (72%), post-traumatic mental changes associated with cosmetic issues and constant fear of brain injury (88%), epileptic seizures (36.8%). Focal symptoms were seen as hemiparesis, central paresis of the facial nerve, amaurosis, hyposmia, anosmia, and myopia. Hemiparesis was observed in 17.5%, central paresis of the facial nerve on the right in 15.4%, on the left in 12.4%, amaurosis in 5% after severe CCT (one eye), hyposmia in 5.6%, anosmia in 8, 6% and amblyopia in 12.4%.

In 25% patients, cranioplasty was performed within 1 year after trauma and resection craniotomy, and in the remaining 75% patients, plastic skull defects was performed after 1 year.

In both groups of patients, surgical intervention began with the separation of the excision of the skin-aponeurotic scar with the release of the edges of the bone defect and dura mater (DM).

Developed by Professor A.M. Mamadaliev with co-authorship and a fixing fan-shaped device used in practice for autoplasty of defects of the cranial vault [7, 8] consists of several identical titanium plates, hinged-connected to each other. The ends of the plates have a rounded shape and at one end of each of the plates there is a hole for mutual fixation. A stainless steel rivet used in medicine is used as a plate retainer. Alternatively, the swivel connection can also be made with stainless steel wire or thick silk. The plates are in various sizes. Their length can be up to 150 mm, width - up to 10 mm and thickness up to 2 mm. The size and number of plates depend on the size of the bone defect in the cranial vault. In working order, the device has the shape of a "Fan" (Fig. 3.).

The free ends of the plates were installed in "grooves" made between the outer and inner plates of the skull bone along the edges of the defect. The number of grooves depended on the number of plates. The hinge-connected end of the device was placed on the opposite side of the bone defect on the made depression on the outer lamina. Bone fragments removed during trepanation were evenly and closely placed over the fan-shaped device. These fragments were prophylactically treated with an antiseptic solution. The postoperative wound was sutured tightly.

Fig. 3. Fan-shaped titanium device used for autoplasty of the cranial vault defects

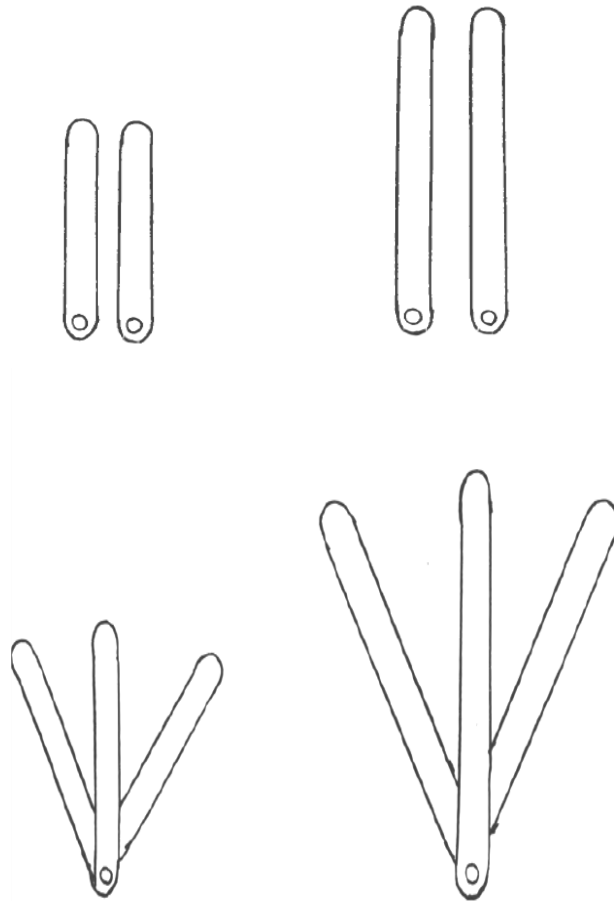
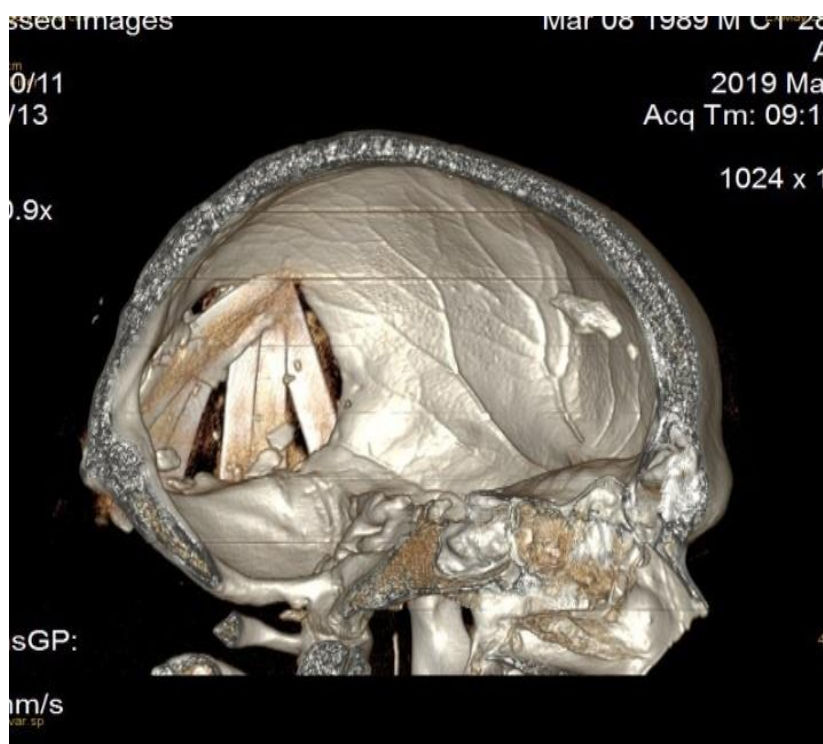


Fig. 4. Skull MSCT with 3D reconstruction after autoplasty using a fan-shaped titanium device



The best results were observed after autoplasty of bone defects of the cranial vault. There were no purulent complications in this group of patients (Fig. 4.).

Out of 28 patients who underwent allocranioplasty with titanium mesh, 5 (17.9%) patients had various complications in the graft rejection form, postoperative wound suppuration and margins osteomyelitis of the bone defect, which eventually required grafts removal (Fig. 5).

In all other cases, a satisfactory cosmetic and clinical effect was obtained. At the time of discharge, patients with autoplasty of skull defects did not show any complaints, there was no pain in the transplant area, the postoperative scar was soft, painless, the skin color was not changed, there was no swelling, the symmetry of the skull was restored.

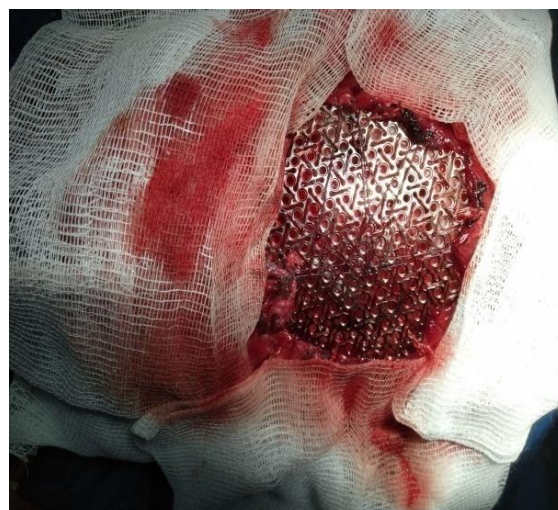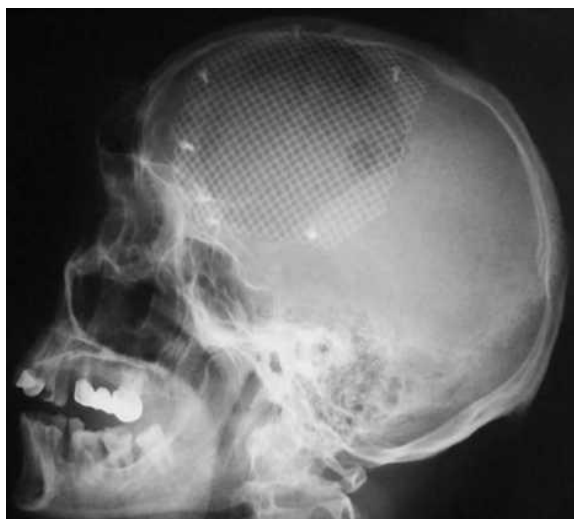Control examination did not reveal any abnormalities in the neurological status in patients of both groups. Pain syndrome regressed in 58 (96.7%) patients. In all cases, a good cosmetic result was achieved.

After 8 months. up to 1 year old, there was a good regeneration of autologous bone with filling of the skull defects, and on palpation the grafts did not differ from the surrounding bones of the cranial vault; symmetry was restored in all cases. Observational radiographs of the skull were performed in dynamics to control the regenerative process of autografts. With the consent of the patients, after the above terms after the operation, the titanium plates ("fan") were removed through a small skin incision in the area of the hinge joint of these plates.

The follow-up research of patients from 8 months to 1 year after the operation showed focal symptoms regression from the CN functions, motor and sensory spheres, amaurosis in 75% - patients in one eye did not improve. General cerebral symptoms completely disappeared in 97% of patients, trepanned syndrome disappeared in 98%, memory and cognitive functions recovered in most patients (93%), epileptic seizures, on the background of appropriate therapy, completely stopped in 89% of patients, the rest became rare. The ability to work was

restored in 82% patients, depending on the profession.

Fig. 5. Craniogram of patient V.A. State after alloplastic titanium implant in the left fronto-parietal-temporal region (after surgery).



4. CONCLUSIONS

1. The patients' follow-up research after surgery after 8 months to 1 year showed an improvement in cerebral symptoms, trepanned syndrome, focal neurological and cognitive symptoms, and in most patients the termination of epileptic seizures.
2. The autocranioplasty method use using a fan-shaped fixing titanium device in patients in the acute CCT period and in the late period of traumatic disease already with existing defects of the bones of the cranial vault showed the high efficiency of this method. The advantage of this type of plastic over others is that the patient's own bone tissue is used as a plastic material. The simplicity of the metal device, its fixation in the area of the bone defect, the ease of further removal and the possibility of performing autocranioplasty in any neurosurgical hospital - all these positive qualities also showed the advantages of this method over other types of plastic surgery. This method shortens the duration of the operation, reduces postoperative complications and can be the method of choice in the reconstructive surgery of skull defects.
3. Studies have shown that the use of implants made of titanium mesh optimizes the task of eliminating complex skull defects, reduces the trauma and duration of the operation, and provides predictable good functional and cosmetic results. It should be noted that 5% of patients in this group had various complications.

5. References.

- [1] Belchenko, V.A. Reconstruction and endoprosthesis of the edges and walls of the orbits, bones of the cranial vault, upper and middle zones of the face / VA Belchenko // Proceedings of the III Congress of Neurochir. Ros. - SPb, 2002. - p. 634.

- [2] Gaidar, B.V. Practical neurosurgery: Guide for a doctor. / Under. B.V. Gaidar red. - SPb .: Hippokrat, 2002 .- 648 p.
- [3] Gusev E.I. Neurology and neurosurgery: textbook: in 2 volumes / E.I. Gusev, A.N. Konovalov, V.I. Skvortsova; ed. A. N. Konovalova, A. V. Kozlova. - M.: GEO-TAR-Media, 2009. - T. 2: Neurosurgery. - 420 p.
- [4] Konovalov, A. N. Clinical guidelines for traumatic brain injury / A. N. Konovalov, LB Likhтерman, A. A. Potapov. - M., 2002. - 675 c.
- [5] Levchenko, O. V. Modern methods of cranioplasty / O. V. Levchenko, V. V. Krylov // Neurology. - 2009. - № 1.
- [6] Mamadaliev, AM Predicting the outcomes of traumatic brain injury in the acute period. Dis. d.m.s. M. 1988.
- [7] Mamadaliev, A.M. Yuldashev Sh.S. A device for autoplasty of cranial vault defects. Medicine problems. Abstracts of the scientific conference dedicated to the 600th anniversary of M. Ulugbek. Samarkan department AN RUZ. honey. the Department. 1994. -p. 41-42.
- [8] Mamadaliev A.M., Yuldashev Sh. S. Device for autoplasty of cranial vault defects. Patent for invention of the Russian Federation N2050833 dated December 27, 1995.
- [9] Mamadaliev A.M., Shodiev A.Sh. Neurosurgery. A textbook for medical students, clinical residents, graduate students and practitioners. Tashkent, "Ilm-Ziyo-Zakovat", 2019.384 p.
- [10] Potapov O.O. Dosvshsu chasnogo zakryttya defekpv istok cherepa / OO Potapov, OP Dmitrenko, OP Kmita // IV Congress of Neurosurgeons of Ukraine: thesis. dokl.D., 2008. - P. 23.
- [11] Yuldashev S.S., Mamadaliev A.M. (2018). Autoplasty of post-traumatic cranial vault defects [Autoplasty of post-traumatic cranial vault bones]. Samarkand, Zarafshon.
- [12] Tanaka, Y. Developmentoftitaniumfixationscrewforhydroxyapatiteosteosynthesis (APACERAM) / Y. Tanaka // Surgneurol. - 2008. - Vol. 70, № 5.- P. 545-549.
- [13] Wilkinson, H. A. Cranial bone fixation / H. A. Wilkinson // J. Neurosurg. - 2004. -Vol. 100, № 6. - P.1 134-1135.