

## **ROLE OF DIFFUSION WEIGHTED IMAGING AND DYNAMIC CONTRAST ENHANCED MRI IN PREDICTING BREAST MALIGNANCY**

First author and corresponding author : Dr. Ayush Gupta, Junior Resident, Department of Radiodiagnosis, SMS Medical College, Jaipur.

Second author : Dr. Isha Gupta, Junior Resident, Department of Radiodiagnosis, SMS Medical College, Jaipur

Third author : Dr. Hari Prasad Saharan, Junior Resident, Department of Radiodiagnosis, SMS Medical College, Jaipur.

Fourth author : Dr. Manit Kulariya, Junior Resident, Department of Radiodiagnosis, SMS Medical College, Jaipur

Fifth author : Dr. Usha Jaipal, Senior Professor, Department of Radiodiagnosis, SMS Medical College, Jaipur.

Sixth author : Dr. Kuldeep Mendiratta, Senior Professor and HOD, Department of Radiodiagnosis, SMS Medical College, Jaipur.

### **INTRODUCTION**

Breast cancer is the most common malignancy in women in both developed and developing countries<sup>1</sup>.

The incidence of breast cancer is on rise in every country and it presents a great challenge to the entire Healthcare system, the greatest increase is seen in Asian countries<sup>1,2</sup>. Where the incidence peaks among women in their forties, in contrast to western countries where it peaks among women in their sixties<sup>3,4</sup>.

Different epidemiological and environmental risk factor associated with breast malignancy are early menarche, late Menopause, nulliparity, elderly primigravida, diminished lactation, excessive exposure to ionizing radiation, family history of breast cancer, previous personal history of breast cancer and other breast diseases such as fibrocystic diseases<sup>5</sup>.

An early and accurate diagnosis of breast cancer has a favorable prognosis than that of late detection<sup>6</sup>.

Mammography is an excellent screening modality for detecting breast cancer at clinically occult stage. However it is non-specific and the nature of lesion may not be fully

ascertained in many cases<sup>7</sup>. Mammography has low predictive value and limited sensitivity in dense breast tissue<sup>7</sup>.

MRI on the other end is ideal for breast imaging because it is non-invasive, non-irradiating and 3-dimensional modality with its excellent ability to depict soft tissue contrast, it is also used to assess axillary lymph nodal status<sup>8</sup>. Dynamic contrast enhanced MRI and DWI have been found to be more accurate in detection of malignancy within dense breast tissue, differentiation of malignancy versus scarring and also in detection of implants.

This study aims to assess and compare the diagnostic efficacy of DCE-MRI and DWI in differentiating malignant and benign breast lesions.

## **MATERIALS AND METHODS**

### **STUDY AREA :**

Department of Radiodiagnosis and Modern Imaging, SMS Medical College and Hospital, Jaipur, Rajasthan

### **STUDY TYPE :**

Hospital based cross-sectional and quantitative study.

### **STUDY DESIGN :**

Analytical type of observational study.

### **STUDY DURATION :**

Data collection for study was started after approval from the institutional research and review board from October 2020 up to September 2022.

### **STUDY TOOL:**

Pre-tested, pre-designed proforma was used to collect data.

### **EQUIPMENT:**

3T Philips Ingenia MRI Machine

### **SAMPLE SIZE:**

A sample size of 50 cases who met the inclusion criteria

### **SAMPLING TECHNIQUE:**

Eligible cases were included in the study.

## **STATISTICAL ANALYSIS:**

Data was expressed in terms of sensitivity and specificity of both CEMRI and DWI with appropriate and necessary tabular presentation.

Diagnostic accuracy of both the modalities was calculated.

Quantitative data was analyzed by mean values and SD.

Qualitative data was analyzed in terms of percentage and proportion.

Difference in proportion was analyzed with Chi Square test and difference in mean was analyzed with unpaired 'T' test.

For significance, P value less than 0.05 was considered significant.

## **STUDY UNIVERSE:**

Patients with clinically suspected breast mass referred to the Department of Radiodiagnosis and Modern Imaging for MRI at SMS Medical College & Hospital, Jaipur.

## **STUDY POPULATION:**

Patients who fulfilled inclusion and exclusion criteria.

## **INCLUSION CRITERIA**

- Patients with history and examination suggestive of breast mass.
- Patients referred from surgery and surgical oncology and suspected to have breast masses and were willing to undergo MRI.
- Those who gave written and informed consent to be included in study.

## **EXCLUSION CRITERIA**

- Patients with MRI incompatible devices and implants.
- Non-availability of histopathological examination report.
- Patient with claustrophobia.

## **METHODOLOGY**

### **TECHNIQUE**

1. MRI was done using Philips Ingenia 3.0 Tesla machine. Following sequences were taken on MRI (slice thickness 3 mm with 0.5 mm interstice gap)
  - TIW\_TSE Axial & T2W\_TSE Axial
  - T1 weighted dynamic contrast enhanced
  - T2W SPAIR Axial
  - Diffusion weighted images
1. Kinetic Assessment on MRI: ROI was selected in the maximum enhancing part of the lesion on T1 post contrast dynamic sequences. Time intensity curves were obtained, and the most suspicious curve was considered. The curves were then categorized into type I (persistent), 2 (plateau) & 3 (washout).
2. BIRADS category were assigned for MRI, based on the most suspicious finding on imaging.
  - Category I: Negative
  - Category 2: Benign
  - Category 3: Probably benign
  - Category 4: Suspicious abnormality
  - Category 5: Highly suggestive of malignancy
  - Category 6: Known biopsy proven malignancy
3. In all the patients, histopathological diagnosis were made by fine needle aspiration cytology, biopsy or postoperative pathological analysis.

## **RESULT AND DISCUSSION**

Out of benign lesions, the most common lesion was fibroadenoma – 69% of total benign lesions. Other than these, among benign lesions 1 case each of benign cyst, intraductal papilloma, breast abscess & phyllodes tumor were encountered in our study. 48% of the cases in this study turned out to be malignant in the final histopathological analysis. Out of the malignant lesions, the most common lesion was IDC - 83.3% of total malignant cases. Among the malignant lesions other than invasive ductal carcinoma, DCIS was the most common lesion- 3 cases (12.5% of total malignant lesions). Other

than these, among malignant lesions, 1 case of invasive lobular (4.1%) was encountered in our study.

In our study, a total of 21 lesions showed diffusion restriction. Out of these, 90.4% lesions were malignant most of which were IDC on histopathology, while 9.5% lesions were benign. 1 lesion showed peripheral diffusion restriction which was benign on histopathology. 28 lesions didn't show diffusion restriction. Out of these, 82.1% lesions were benign, while 17.8% lesions were malignant.

In our study, 23 lesions depicted homogenous enhancement. Out of these 82.6% lesions were benign, while 17.3% lesions were malignant. 19 lesions depicted heterogeneous enhancement. Out of these 94.7% lesions were malignant, while 5.2% lesions were benign. 3 lesions showed rim enhancement, all were benign (100%). 2 lesions demonstrated non mass like enhancement. 1 focal NMLE and 1 clumped NMLE. Both of these were malignant (DCIS) on histopathology (100%). 3 of the lesions didn't show any enhancement, these lesions were benign on histopathology (100%).

In this study, out of total 50 lesions, only 3 lesion didn't show any enhancement on post contrast sequences (6%). Type 1 dynamic curve was seen in 17 lesions, 100% of these proved to be benign on histopathology. Type 2 dynamic curve was seen in 24 lesions, out of which 18 lesions proved to be malignant (75%) & 6 lesions were benign(25%). Type 3 dynamic curve was seen in 6 lesions, 100% of these lesions proved to be malignant on histopathology.

The sensitivity, specificity, positive predictive value, negative predictive value of MR mammography in differentiating benign from malignant lesions based on diffusion restriction in the lesion were 79.17%, 88.46%, 86.36%, 82.14% respectively and based on the type of enhancement (taking heterogeneous enhancement and NMLE as suspicious) were 83.3%, 96.15%, 95.24%,86.21%, respectively.

On kinetic analysis, type1 curve is quite specific for benign lesions,while type 3 curve is

quite specific for malignant lesions. However, type 2 curve can be seen in both benign & malignant lesions.

### CONCLUSION

To conclude, Diffusion weighted imaging and Dynamic contrast enhanced MRI sequences along with kinetic curve assessment have profoundly increased the diagnostic efficacy of MRI Breast in predicting malignancy. No enhancement and homogenous enhancement on post contrast sequences were features of benign lesions on the other hand heterogeneous enhancement were more commonly seen in malignant lesions.

79.1% of malignant lesions showed diffusion restriction on DWI images. 100% of lesions with Type 3 kinetic curve and 75% of lesions with Type 2 kinetic curve were malignant on histopathology.

### ACKNOWLEDGEMENT

We thank all the doctors, paramedical staff, MRI technicians of the Radiodiagnosis department, SMS medical college and included patients for their cooperation.

### REFERENCES

- (1) Anita Khokhar. Breast cancer In India: where do we stand and where do we go? Asian Pacific J Cancer Prey, 2012; 13(10)A8614866.
- (2) Hortobagyi GN, Garza SJ, Pritchard K, et al (2005). The global breast cancer burden: variations in epidemiology and survival, Clin Breast Cancer. 2005;6:391-401.
- (3) Green M, Raina V (2008). Epidemiology, screening and diagnosis of breast cancer in the Asia—Pacific region: current perspectives and important considerations. Asia Pac J Clin Oncol 2008; 4:5-13.
- (4) Anderson BO, Jakesz R. Breast cancer issues in developing countries: an overview of the breast health global initiative. World J Surg. 2008; 32:2579-85.
- (5) Prince AH, Kavitha S, Biju VS, MS Vidyasagar, Suma N. Risk factors for breast cancer among women attending a tertiary care hospital, J Collaborative Res Int ,viedPublic 1-11th 2010; 2:109-16.
- (6) Padhmini Balasubramaniam, Vijaya Kartikeyan Murugesan, Vinod Boopathy.

Role of MR Mammography in differentiating malignant from benign in suspicious breast masses: JCDR 2016 : Vol-10(9) : TC05-TC08.

- (7) Kuhl CK, Schrading S, Leutner CC, Wardelamnn E, et al. Mammography, usg, MRI for surveillance of women at high familial risk of breast cancer. J ClinOncol. 2005;23(33): 8469-8476.
- (8) Pediconi F, Catalano C, Occhiato R, et al. Breast lesion detection and characterization at contrast-enhanced MR mammography: gadobenate dimeglumine versus gadopentetate dimeglumine. Radiology. 2005;237:45-56.

**Table 1 : Distribution of study subjects according to histopathological diagnosis**

<b>Histopathological diagnosis</b>	<b>N</b>	<b>Percentage</b>
Fibroadenoma	18	36
Intraductal papilloma	2	4
Granulomatous Mastitis	2	4
Hamartoma	1	2
Phyllodes	1	2
Abscess	1	2
Benign cyst	1	2

IDC	20	40
DCIS	3	6
ILC	1	2
<b>Total</b>	<b>50</b>	<b>100</b>

**Table 2 : DWI on MRI in relation to Histopathology**

DWI	Malignant		Benign		Total	
	N	%	N	%	N	%
Restriction	19	79.2	2	7.7	21	42
Peripheral restriction	0	0	1	3.8	1	2
No restriction	5	20.8	23	88.5	28	56
<b>Total</b>	24	100	26	100	50	100

Chi-square = 26.295 with 2 degrees of freedom; **P < 0.0001 (S)**

**Table 3 : T1C+ on MRI in relation to Histopathology**

T1C+	Malignant		Benign		Total	
	N	%	N	%	N	%
Clumped NMLE	1	4.2	0	0	1	2
Focal NMLE	1	4.2	0	0	1	2
Heterogenous	18	75	1	3.8	19	38
Homogenous	4	16.7	19	73.1	23	46
Rim	0	0	3	11.5	3	6
No	0	0	3	11.5	3	6
<b>Total</b>	24	100	26	100	50	100



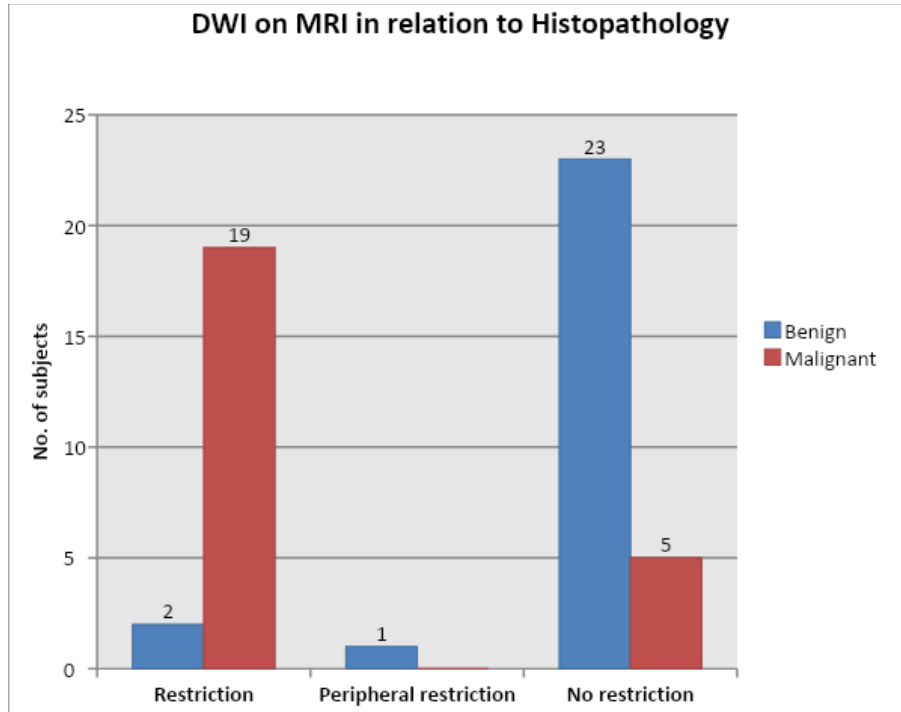
Chi-square = 32.966 with 5 degrees of freedom; **P < 0.0001 (S)**

**Table 4 : Curve on MRI in relation to Histopathology**

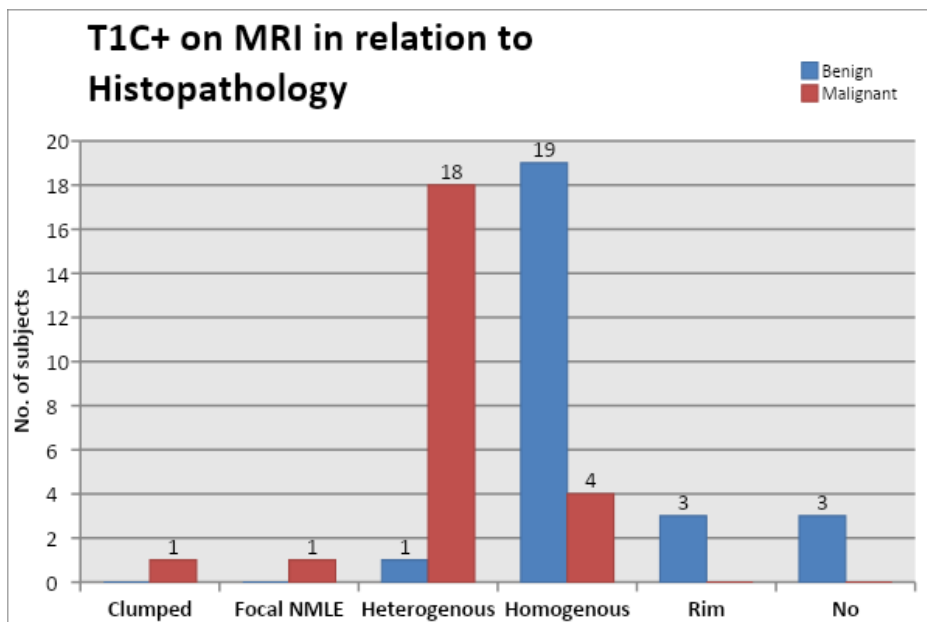
Curve	Malignant		Benign		Total	
	N	%	N	%	N	%
<b>Type I</b>	0	0	17	65.4	17	34
<b>Type II</b>	18	75	6	23.1	24	48
<b>Type III</b>	6	25	0	0	6	12
<b>No enhancement</b>	0	0	3	11.5	3	6
<b>Total</b>	24	100	26	100	50	100

Chi-square = 31.971 with 3 degrees of freedom; **P < 0.0001 (S)**

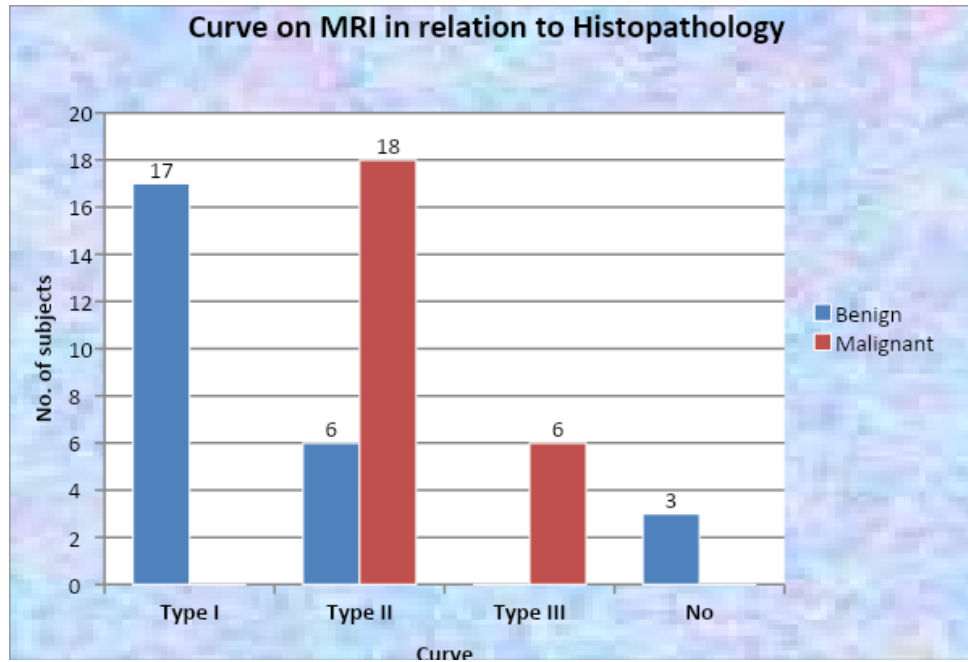
Graph 1 : DWI on MRI in relation to histopathology



Graph 2 : T1C+ on MRI in relation to histopathology

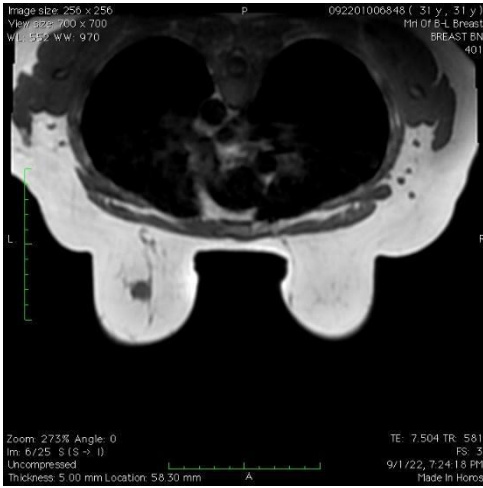

Graph 3 : Kinetic curve on MRI in relation to histopathology

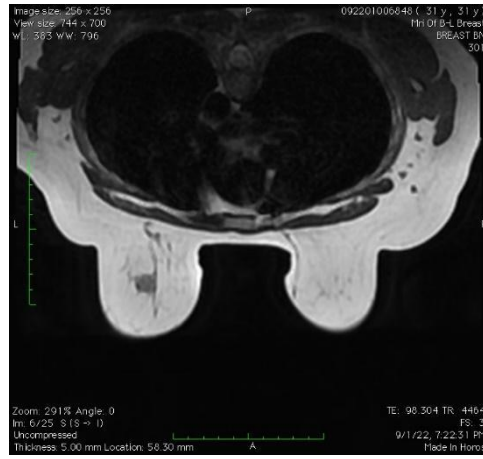


## CASE ILLUSTRATIONS

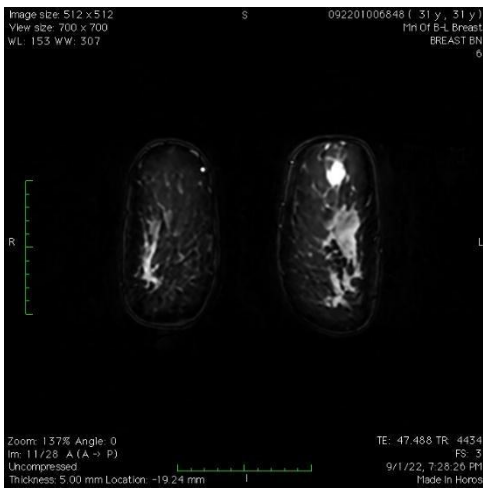
### CASE 1



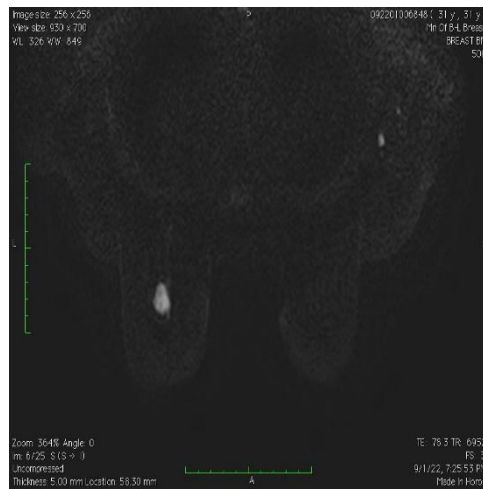(A)



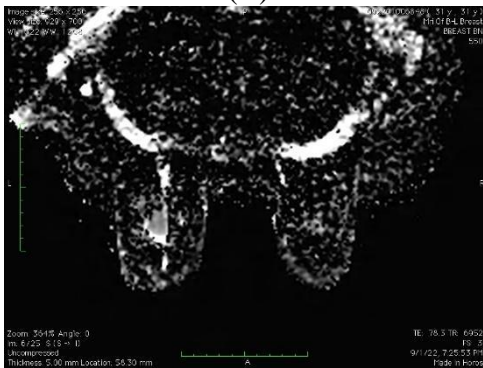
(B)



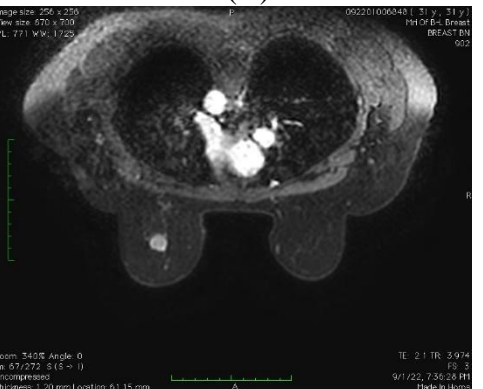
(C)



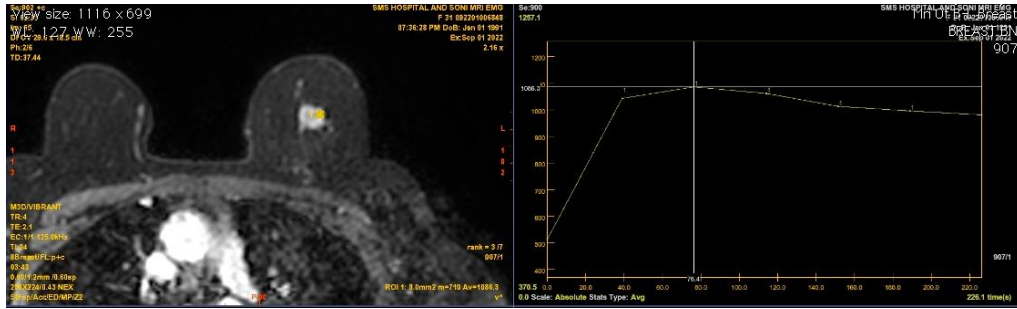
(D)



(E)



(F)



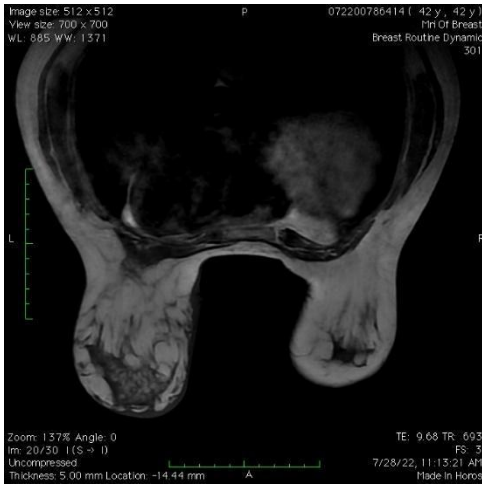(G)

**Case - 1** : 31 year old female with palpable lump in left breast.

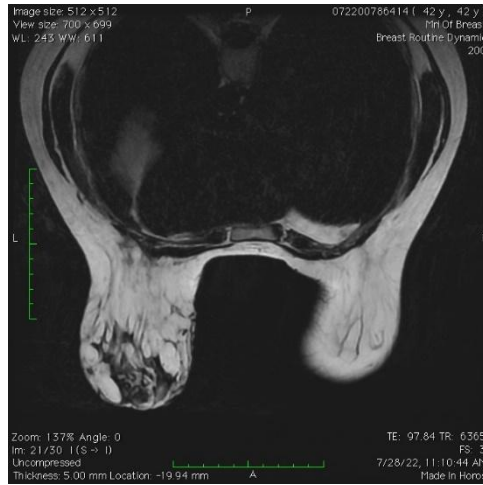
- A) T1WI & B) T2WI show hypointense oval mass with irregular margins in left breast.
- C) On Coronal STIR images the mass is hyperintense.
- D) DWI & E) ADC map the mass is showing diffusion restriction.
- F) T1 post contrast fat suppressed
- G) Kinetic assessment of the mass shows Type - III curve.

**This mass lesion proved to be an Invasive ductal carcinoma on histopathology.**

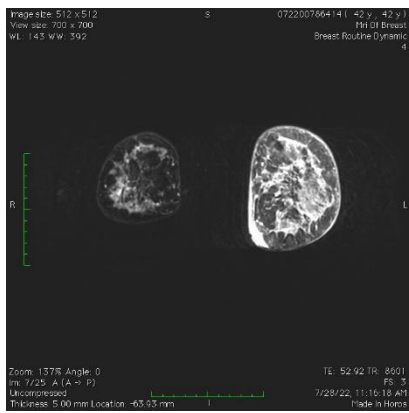
## CASE 2



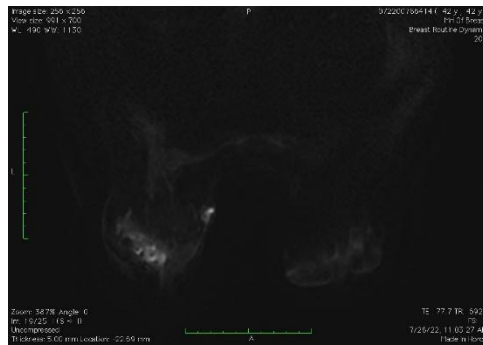
(A)



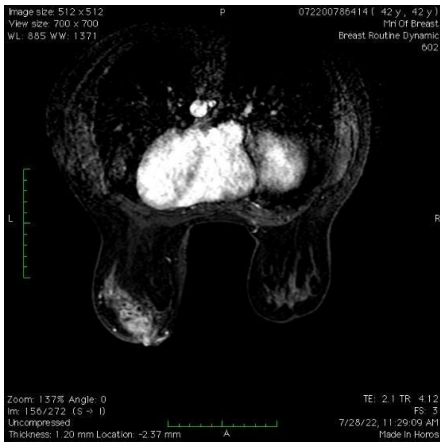(B)



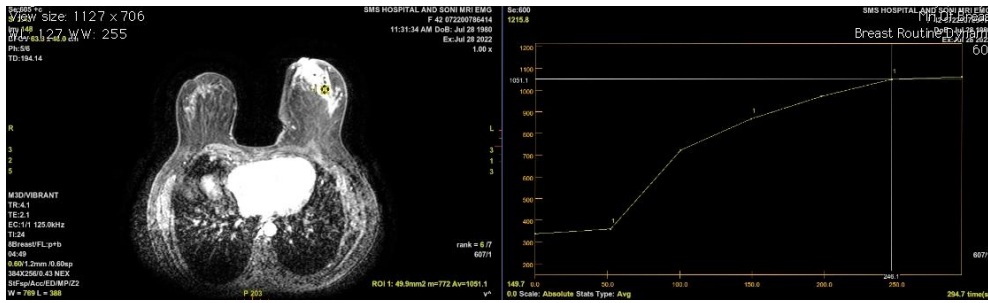
(C)



(D)



(E)



(F)

**Case - 2 :** 42 year old female with painful enlargement of left breast.

A) T1WI isointense & B) T2WI hyperintense oval mass with irregular margins in left breast.

C) On Coronal STIR image the mass and skin of left breast show hyperintensity.

D) On DWI the mass is showing diffusion restriction.

E) T1 post contrast fat suppressed

F) Kinetic assessment of the mass shows Type - I curve.

**This mass lesion proved to be granulomatous mastitis on histopathology.**