

CONFERENCE/MEETING ABSTRACT PROCEEDING

Congress Abstracts: 2018-European Clinical Case Reports Congress (EUCCR-2018), 21–22 April 2018, Vienna, Austria

Aamir Shahzad*† and Randall J. Cohrs*†

Keywords: Clinical case reports**Oral Abstracts****First report of a case of central nervous system vasculitis associated to the use of the check point inhibitor ipilimumab**

Juan Maya, Florentina Berianu, Benjamin Wang, Andy Abril and Ronald R. Butendieck Jr.
Mayo Clinic Florida, Jacksonville, US

Introduction

Recently, cancer treatment was revolutionized by the use of immune checkpoint blockade. Through the use of inhibitors of cytotoxic T-lymphocyte-associated antigen 4 (CTLA-4) and programmed cell death-1 (PD-1), cytotoxic T cells can be activated to destroy tumor cells. The first immune checkpoint inhibitor to display high antitumor activity was the monoclonal antibody ipilimumab, and even though it has improved the outcome of different types of cancer, several immune-related adverse events (irAEs) have been reported associated to its use.

Case Description

A 70-year-old male was diagnosed with stage 3A melanoma and was started on monthly ipilimumab. After his third dose, he noticed generalized arthralgia and stiffness, and after his fourth dose he reported unsteady gait and dizziness. Over several weeks his gait continued to decline, he was having significant joint pain and he was unable to walk without assistance. He presented to our rheumatology clinic where he was found to have synovitis of several joints, a wide based gait and a positive Romberg; the remaining of his neurological exam was normal. He had a slight elevation of his CRP, but his sedimentation rate, RF, CCP, ANA and ENA were unremarkable. MRI of the brain with and without contrast demonstrated multifocal tiny

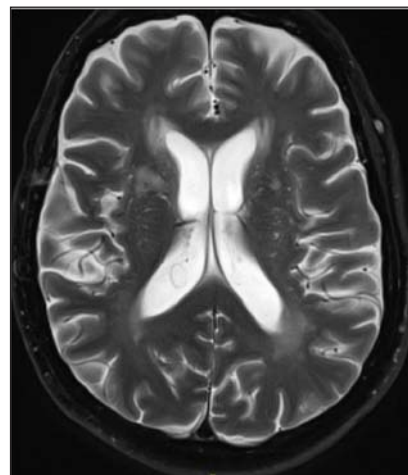
curvilinear enhancing foci within the cerebral white matter with perivascular appearance, suggestive of vasculitis.

Results

He was started on prednisone 1 mg/kg for possible irAEs and 1 week later he reported that his joint pain and dizziness had resolved, and that he was able to walk without assistance. Two weeks after starting the prednisone a new MRI demonstrated resolution of the curvilinear foci of abnormal brain perivascular enhancement. After discussing steroid sparing treatment options with the patient, he decided that he wanted to avoid biologics so he opted for methotrexate. His prednisone was progressively tapered and he is currently asymptomatic on methotrexate 20 mg/weekly and prednisone 10 mg/day.

Take Home Message/Conclusions

Although irAEs are being reported more frequently as the use of check point inhibitors increases, as far as our knowledge goes, this is the first time that CNS vasculitis has been associated to the use of ipilimumab. The morbidity of CNS vasculitis and irAEs can be catastrophic but it seems that when autoimmune pathologies are associated to checkpoint inhibitors they rapidly improve with immunosuppression. We consider that it is crucial to be aware

**Figure 1:** Brain MRI with and without contrast.

* Department of Neurology, University of Colorado School of Medicine, Colorado, US

† European Society for Translational Medicine (EUSTM), AT

Corresponding author: Aamir Shahzad
(aamir.shahzad@ucdenver.edu)

and to promptly recognize possible irAEs, since treatment can dramatically improve the outcome and quality of life of these patients.

Demonstration of significant decrease in optic nerve sheath diameter after hemicraniectomy using bedside ultrasonographic measurement of optic nerve sheath diameter

Odmara Barreto-Chang, Michael Huang and Julin Tang
UCSF, San Francisco, US

Introduction

Optic nerve sheath diameter measurement is a technique that has been used to predict elevated intracranial pressure in patients with head injury. One of the first studies was reported by Galetta in 1989. They demonstrated a marked reduction of cerebrospinal fluid pressure correlated with a decrease in the subarachnoid fluid of the optic nerve sheath. Multiple studies have focused on the use of ONSD that can be used to correlate elevated ICP in adults and children. There are many advantages of using ONSD including: non-invasive, rapid performance, relatively low costs, portability and avoidance of ionizing radiation among others.

Case Description

A 33-year-old woman with left subdural and epidural hematomas after a mechanical fall from stairs presented to the emergency department in critical state with presumed elevation of ICP and loss of consciousness requiring immediate intubation upon arrival. Bedside ED optic nerve sheath diameter ultrasonography demonstrated a significant difference between both eyes, O.D. 5.1 mm and O.S. 7.2 mm, with a left blown pupil. The patient was taken for a CT scan and brain images demonstrated both epidural and subdural hematomas on the left side. She underwent a left decompressive hemicraniectomy for the evacuation of hematoma.

Results

A repeat bedside measurement of ONSD ultrasonography after hemicraniectomy demonstrated decrease diameter of the left side to 5.4 mm and the right side remained 5.1 mm. The patient had a significant decrease in intracranial pressure which correlated with the decreased diameter of the nerve sheath on the left side.

Take Home Message/Conclusions

We report the use of ultrasonography for monitoring intracranial pressure in the postoperative period as it served as an auxiliary tool that can be easily used at the bedside to predict pressure changes that can ultimately affect therapeutic interventions and outcomes in a rapid manner. To our knowledge this is the first case report of using optic nerve sheath diameter ultrasonography for assessment of intracranial pressure postoperatively. Further studies are needed to determine whether this clinical practice of ONSD measurement should be adopted

more widely perioperatively for rapid diagnosis and ICP monitoring.

I cannot get out of bed

Dana Harris, Alex Kesler and Timothy Malouff
Mayo Clinic, Jacksonville, US

Introduction

Hypokalemic periodic paralysis is a rare autosomal dominant neuromuscular disorder with an incidence of 1 in 100,000. It is caused by a defect in skeletal muscle calcium ion channels and presents with muscle weakness precipitated by heavy exercise, stress, or high carbohydrate meals. Attacks begin in late childhood or teenage years. Examination during an attack demonstrates weakness affecting the legs more than the arms, hyporeflexia or areflexia. Between attacks examination is normal. A diagnosis is made by history, hypokalemia and EMG. The treatment consists of potassium supplementation, potassium sparing diuretics or carbonic anhydrase inhibitors and a low carbohydrate diet and decreased exercise.

Case Description

A 21 year old male presented to the hospital with acute flaccid paralysis. He woke up in the morning and could not get up from bed. The days prior he played basketball and consumed high carbohydrate snacks. He was diagnosed with hypokalemic periodic paralysis at the age of 14. His sister and father also have this diagnosis. He is hospitalized several times a year with paralysis, and he lost his job. He does not have medical insurance or a family physician. Home medications are daily potassium chloride and spironolactone. He reported compliance with taking the medications.

Results

Serum potassium was 2.1 mm/L. Other electrolytes and vital signs were normal. An electrocardiogram showed sinus arrhythmia, low T waves and high U waves. An electromyography showed absent peroneal/anterior tibialis motor response and low left ulnar motor amplitude, consistent with a muscle channelopathy. Other causes of hypokalemia were excluded. The diagnosis was hypokalemic periodic paralysis. Treatment consisted of potassium supplements and he was discharged when serum potassium normalized and he was able to get up from bed. Discharge medications were potassium chloride, spironolactone and triamterene. He was advised on low carbohydrate diet and decreased exercise.

Take Home Message/Conclusions

Hypokalemic periodic paralysis is a rare autosomal dominant condition which causes paralysis of arms and legs associated with low serum potassium. It is exacerbated by a high carbohydrate diet and strenuous exercise. It should be included in the differential diagnosis in young patients presenting with acute flaccid paralysis. It can be excluded by a normal serum potassium. The paralysis resolves with normalization of serum potassium. The treatment con-

sists of medications that increase serum potassium and modifications in diet and exercise. Regular medical follow up with measurement of serum potassium may prevent hospitalizations.

Herpes Zoster: New developments in latency & Vaccines

Randall J. Cohrs

University of Colorado School of Medicine Research, Colorado, US

Varicella zoster virus (VZV; human herpesvirus type 3) is a ubiquitous human pathogen that typically causes childhood varicella (chickenpox) on primary infection and zoster (shingles) following reactivation from decades of latent infection in neurons of the peripheral nervous system. This last year has seen significant advances in both basic and applied VZV research. An international collaboration has discovered the VZV latency transcript, a missing piece to the puzzle of VZV latency that culminates more than 3 decades of work. Shingrix, the first subunit herpesvirus vaccine was approved in the US after a Phase III clinical trial evaluating efficacy, safety and immunogenicity in more than 38,000 people. This amazingly efficacious vaccine (>90% across all age groups) adds to our arsenal of live attenuated VZV vaccines that have been in use for over a decade. For potential therapeutic use, a recombinant antibody raised *in vivo* and constructed *in vitro* is available. This talk will describe these advances; ones that may ultimately help eradicate the scourge of shingles in the human population.

One girl, two duplications

Anna Lengyel, Eva Pinti, Zsuzsa Toth, Eszter Kiss, Gyorgy Fekete and Iren Haltrich
Semmelweis University, Budapest, HU

Introduction

Chromosomal abnormalities are responsible for approximately 15% of major developmental anomalies and 18% of neonatal mortality worldwide. Less common and less understood are the structural aberrations of autosomes. Here we report the case of a young girl who carries two duplicated segments within the long arm of chromosome 5 (5q).

Case Description

The child was directed to us with multiplex developmental abnormalities at 6 years of age. She was born to non-consanguineous parents after 38 weeks of gestation by abdominal delivery due to fetal bradycardia and weighed 1920 grams. Chorionic villus sampling previously showed 46,XX karyotype. She had a ventricular septal defect, closed at 15 months. She presented with muscle hypotonia, high-arched palate, low-set ears, clinodactyly, syndactyly of 2nd and 3rd toes and hyperextendable joints. Movement and speech development were delayed: she started walking at

18 months and talking at 3 years. She is being treated for strabism and asthma bronchiale.

Results

Giemsa-staining, fluorescent *in situ* hybridization and array comparative genomic hybridization showed duplications of 5q13.3–q14.1 (3,15 Mb) and 5q23.2–q31.1 (11,04 Mb), where Online Mendelian Inheritance in Man catalogues 8 disease causing genes. Potentially relevant are *PR domain-containing protein 6* (associated with patent ductus arteriosus) and *Lamin B1* (duplication causes adult-onset demyelinating leukodystrophy). Pure 5q duplications present with wide phenotypic variety. Most common symptoms are also non-specific. Our patient shares minor anomalies, ventricular septal defect, strabism, muscle hypotonia and developmental delay with patients carrying overlapping duplications. Asthma is unique to her, while otherwise common traits (microcephaly, urogenital problems) are missing.

Take Home Message/Conclusions

Researchers have been trying to associate specific syndromes with 5q duplications. This has proven problematic due to several factors, i.e. the duplicated segments vary in size and localization; many publications date back before higher definition diagnostic methods were available. Investigation with array comparative genomic hybridization and accumulation of data are necessary for more accurate genotype-phenotype correlation studies and to better understand this particular chromosome abnormality. Our patient's symptomatology adheres only partly with published cases. The combined effect of her duplications further complicates genotype-phenotype correlation. Regular screenings are important for early recognition and treatment of future medical problems.

Oncosurgical approach of unresectable hepatic metastases of colorectal cancer

Catarina Afonso, Jorge Pereira, Júlio Constantino and Carlos Casimiro
Centro Hospitalar Tondela-Viseu, Viseu, PT

Introduction

The term Oncosurgery was introduced by Henri Bismuth in the 1990s and referred to a multidisciplinary strategy that combined surgery with other methodologies capable of rendering resectable hepatic metastases of colorectal neoplasia primarily unresectable.

Case Description

73-year-old male patient who underwent segmental colon resection in July 2011, due to obstructive neoplasia of the transverse colon and bilateral hepatic metastasis, with T4 N2M1 staging. He started chemotherapy with a palliative purpose in August of 2011. After therapy, a significant reduction of metastatic disease was observed, and its resection was planned in 2 stages. In May 2014 the patient was submitted to resection of the left lobe metastases,

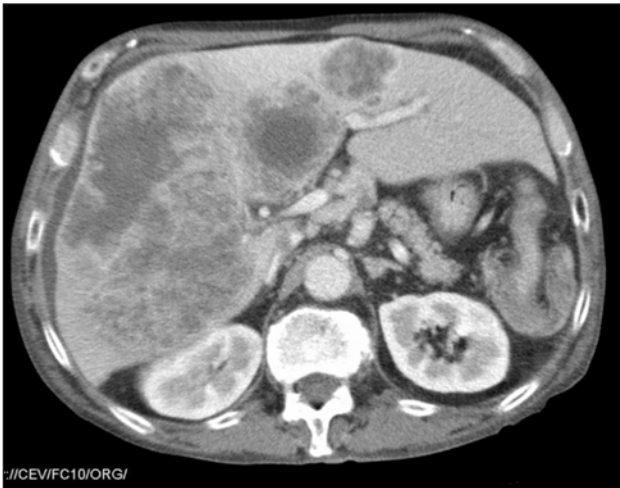

Figure 1.

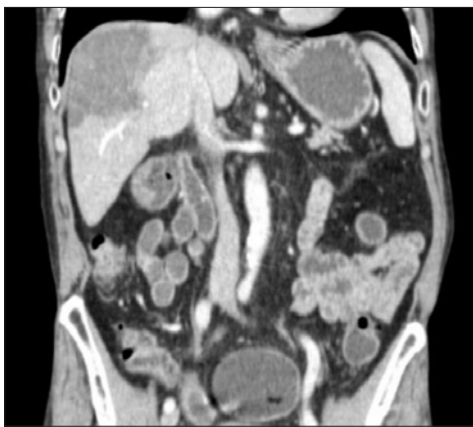


Figure 2.

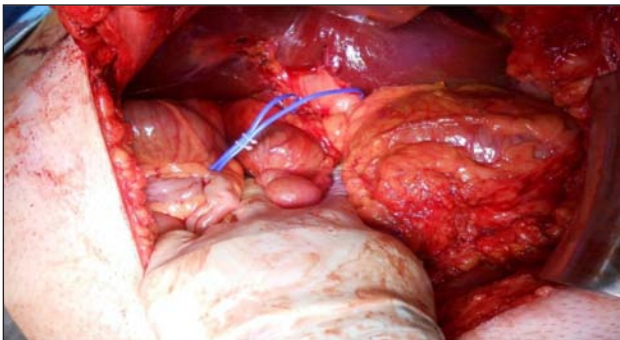


Figure 3.

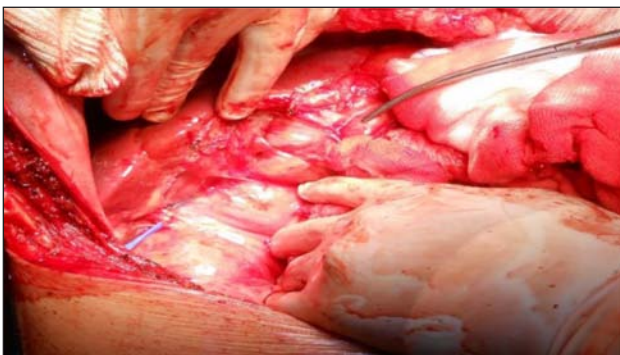


Figure 4.

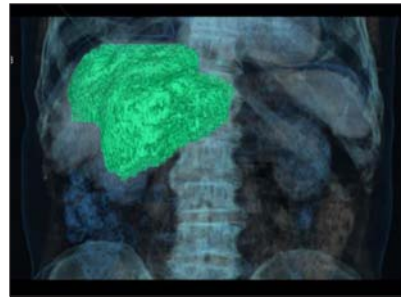


Figure 5.

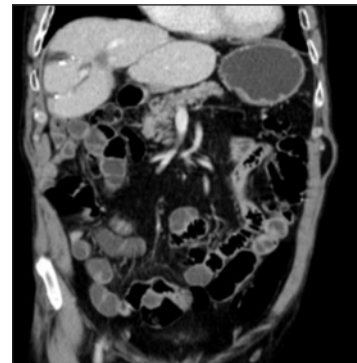


Figure 6.

radiofrequency ablation of a left lesion and right portal embolization. In July of the same year, he underwent right hepatectomy, with removal of the remaining disease.

Results

At follow-up after two years, he presented imaging without signs of hepatic disease again and with dimensional stability of the lesion undergoing ablation.

Take Home Message/Conclusions

The survival of patients with colorectal cancer with hepatic metastasis is determined by the possibility of primary tumor resection and metastasis. Currently patients who initially would not be candidates for curative resection may become eligible after systemic treatment with aggressive chemotherapy with or without addition of biological agents.

Endocrinology, full of surprises

Anton Luger

Medical University and General Hospital of Vienna, AT

Endocrinology has developed considerably in the last century. Whereas until a few decades ago the endocrine system has been considered to be restricted to endocrine glands secreting unidentified substances that would reach their target organs via the bloodstream it is now generally accepted that non-classical endocrine organs such as the skin, heart, lung and others can produce hormones and do not simply serve as target organs for hormones. In addition, the molecular mechanisms of hormone action have been elucidated and molecular genetics plays an increasingly important role for the diagnosis, counseling

and therapy of endocrine disorders. Furthermore it is now well known that hormones communicate with each other and the concept of bidirectional crosstalk between hormones, the immune and central nervous systems is generally accepted. Examples of discoveries of the last decades describing the crosstalk between the endocrine and immune systems as well as the communication between other organs that were considered to act independently from each other such as the gut-brain-axis and the heart-gut-brain-axis will be discussed.

T-Cell lymphoblastic leukemia recurrence in the breast

Naziya Samreen, Shahrukh Hashmi, Amy Connors and Katrina Glazebrook
Mayo Clinic, Rochester, US

Introduction

Leukemic involvement of the breast is extremely rare, described predominantly in case reports. It can occur as an isolated tumor or secondary to systemic involvement, however there is a paucity of literature on its presentation. This case report describes a case of mediastinal T-Cell lymphoblastic leukemia (T-ALL), status post hematopoietic stem cell transplant (HSCT), who had a recurrence in bilateral breasts.

Case Description

The patient is a 27 year old female who presented with symptoms of SVC obstruction secondary to a mediastinal

mass which was hypermetabolic on PET. A core biopsy demonstrated T-ALL, CD3 positive and BLC-2, and 80% Ki-67 positive. Bone marrow involvement was less than 5%. She was treated with chemotherapy and post treatment PET/CT demonstrated resolution of mediastinal mass, with no evidence of distant disease. She underwent allogeneic HSCT. Seven months later, the patient presented with a large area of tender swelling of both the breasts (initially left side) with biopsy demonstrating relapsed T cell ALL with cytogenetic abnormalities.

Results

Radiologic findings show bilateral breast masses on ultrasound and mammogram, which were hypermetabolic on PET/CT. The patient took two weeks off to travel, and when she returned, the masses had grown in size. No other sites of disease were noted with further workup. She was treated with multiple cycles of chemotherapy and achieved remission as confirmed by the bone marrow biopsy. Due to extramedullary isolated relapse in the breasts, she underwent radiation therapy. A second allogeneic HSCT was performed in remission. The patient has been disease free for two years.

Take Home Message/Conclusions

Breast involvement of leukemia, a very rare entity, can occur prior to marrow/blood involvement, secondary to metastatic disease from systemic involvement, or secondary to relapse after stem cell transplantation. Most patients present with a palpable mass. Mammographic findings in

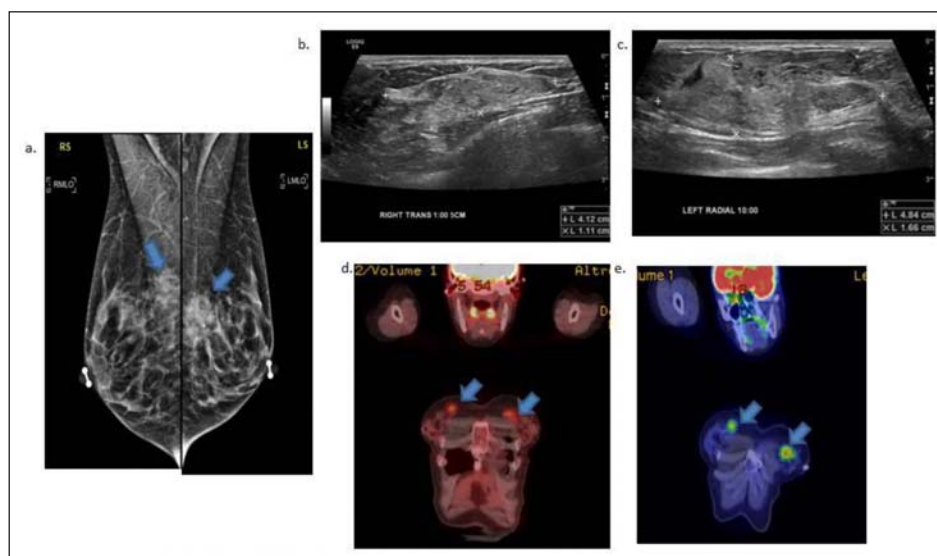


Figure 1: **a.** Mammogram: There was parenchymal asymmetry in the upper inner right breast posterior depth. There was an area of focal parenchymal asymmetry in the medial left breast middle/posterior depth, which contains a biopsy clip marking the known recurrent T-cell lymphoma. These were increased in size compared to mammogram two weeks ago. **b.** Ultrasound: Hyperechoic: irregular mass in the 1 o'clock position of the right breast 5 cm from the nipple measured 4.7 cm in largest dimension, increased from two weeks prior where it measured 3.3 cm. **c.** Ultrasound: Hyperechoic, heterogenous mass in the 10 o'clock position of the left breast 4 cm from the nipple measured 4.8 cm in largest dimension, increased from prior exam where it measured 4.1 cm in maximum dimension. There was internal vascularity within these masses. **d.** Initial PET CT: There was irregular soft tissue nodularity within the medial aspect of the left breast (SUV max 4.9) and medial aspect of the right breast (SUV max 3.0). Findings were in keeping with bilateral breast recurrence of lymphoblastic leukemia. **e.** Repeat PET/CT: Increased size and FDG activity within the bilateral breasts metastases.

leukemia can include masses or architectural distortion, and they are typically hyperdense on ultrasound. Unlike lymphoma, in leukemia, patients can have a marked PET response to chemotherapy without significant reduction in size, which can indicate persistent aggressive disease. Typically, the treatment is chemotherapy and/or radiation with allogeneic HSCT as a curative modality.

A 77-year-old woman with a rare tonsillar tumor: evidence of a stem cell tumor?

Maaïke Ramael¹, Marc Ramael^{2,3}, Tony Puls⁴, Lode Op DeBeek⁵ and Meyskens Jean⁶

¹ University of Antwerp, Antwerp, BE

² Laboratory of Cell Biology and Histology, University of Antwerp, Antwerp, BE

³ Department of Surgical and Molecular Pathology, AZ Herentals, Herentals, BE

⁴ Department of ENT, AZ Herentals, Herentals, BE

⁵ Department of Surgical and Molecular Pathology, AZ Herentals, Herentals, BE

⁶ Department of Radiotherapy, AZ Turnhout, Turnhout, BE

Introduction

Pure squamous cell carcinomas are the most common malignant tumors of the palatine tonsil followed by diffuse large B-cell Non-Hodgkin lymphoma and metastatic deposits of lung carcinoma, gastric carcinoma, melanoma, renal carcinoma and adenocarcinoma of the colon. Muco-epidermoid carcinoma of the palatine tonsil is an extremely rare tumor. A literature search revealed only three cases of muco-epidermoid carcinoma of the palatine tonsil. We describe another case and searched for markers indicating 'stemcellness' suggesting the possibility of 'stem cell tumor'.

Case Description

A 77 year old woman was referred for vague complaints of pharyngeal discomfort without dysphagia. There was no history of tobacco abuse nor alcohol abuse. Clinical investigation revealed a tumour in the right palatine tonsil with associated oedema of the right tonsillar arch. Tonsillectomy was performed. After two months the patient underwent right neck dissection for removal of suspicious lymph nodes. Post-operative radiotherapy was given (32 Gy). The patient is alive and well after one year follow up without any sign of disseminated disease.

Results

Histopathological examination showed a tonsil (3 × 2.5 × 1.5 cm) that was diffusely infiltrated by a malignant epithelial tumor with both squamous and mucinous differentiation suggesting muco-epidermoid carcinoma confirmed by PAS-after diastase stain. One of five lymph nodes was invaded by muco-epidermoid carcinoma. Immunoreactivity was found for cytokeratin 14 and focally for cytokeratin 7. No immunoreactivity was found for TTF-1, nor cytokeratin 20 thereby ruling out metastatic origin. Additional immunoreactivity was found for p16 and for stem cell associated markers CD44, CD133 and ALDH-1

but not for CD10. Real time PCR disclosed HPV 16 DNA confirming the immunoreactivity for p16 protein.

Take Home Message/Conclusions

Muco-epidermoid carcinoma of the palatine tonsil is an extremely rare tumor but has to be considered in the differential diagnosis of tonsillar tumors. Our case might be an example of a 'stem cell tumor'. There is immunoreactivity for several cancer stem cell markers (ALDH, CD44) which can be found in tumorigenic cancer stem cells of muco-epidermoid carcinoma. The oncogenic process is probably initiated by HPV 16 infection.

Problematic polypharmacy – A need for change

Amani Patel¹, Giulia Buckens¹ and Abu Shafi²

¹ University College London (UCL), London, UK

² Camden and Islington NHS Trust, London, UK

Introduction

Polypharmacy is an increasingly frequent phenomenon experienced by patients. Despite its potential to be beneficial, it can be problematic and lead to poor adherence. In a mental health setting, where numerous healthcare professionals are involved, we aim to look at who is responsible for the prescription of multiple medications, the reasons behind non-adherence and how this can be improved for the future. We describe the case of a patient with a long-standing mental health disorder and an extensive medication history, who stopped all medication without reason, with unexpected consequences.

Case Description

A 61-year-old female patient was seen by the psychiatric team having decided to stop taking all medications two weeks previously. She has an extensive history since the age of 16 of alcohol-related admissions, with varying diagnoses over time including alcohol dependence, schizophrenia, bipolar disorder, schizoaffective disorder and an avoidant and anxious personality. This history as well as other co-morbidities amounted to her being on lithium, amisulpride, procyclidine, pregabalin, propranolol, zopiclone and tiotropium. Her past history has shown several episodes of her stopping all medication, and at times her cognitive function improving when medications were simplified.

Results

When seen by the team, she was found to have improved cognition, memory, mood, mobility and engagement – an unexpected finding due to the abrupt stoppage of these medications. We concluded that polypharmacy may have played a significant role in the patient's cognitive decline and behavioural changes, but more importantly that it could have been avoided. The responsibility does not lie with one person, but the complex history meant that the patient's case was transferred through various services, leading to an experimental

build up of medications. Additionally, gaps in the notes have lead to uncertainty behind why medications have been prescribed.

Take Home Message/Conclusions

We have seen a complex interaction of trial and error of every anti-psychotic, mood stabiliser and anti-depressant, increased doses despite a lack of improvement, with further medications prescribed to counteract side effects, leading to addiction, erratic compliance, a lack of improvement or deterioration in the patient. The improvement in symptoms after termination of all medications suggests that the risks of polypharmacy may have outweighed the benefits. We conclude that medications should be constantly reviewed with alternative treatments sought after when significant side effects are present. Over-prescribing leads to probable harm, and further actions need to be taken to prevent this.

Atrial myxoma presenting as infective endocarditis

Gerald Fitzgerald¹, Zahir Satti¹, J. J. Coughlan¹, Arnous Samer¹, John Hinchion² and Tom Kiernan³

¹ University Hospital Limerick, Limerick, IE

² Cork University Hospital, Cork, IE

³ University Hospital Limerick, Limerick, IE

Introduction

The presenting complaint of general malaise, fever, weight loss and night sweats are concerning for a number of serious pathologies including malignancy, tuberculosis and infective endocarditis. Classically, cardiac neoplasms present with one or more of the triad of constitutional, obstructive and embolic symptoms. For cardiac myxoma to present as infective endocarditis is a rare occurrence, with limited cases reported in the literature.

Case Description

A 23 year old Asian student presented to our service with a one month history of fever, weight loss of 10 kg, night

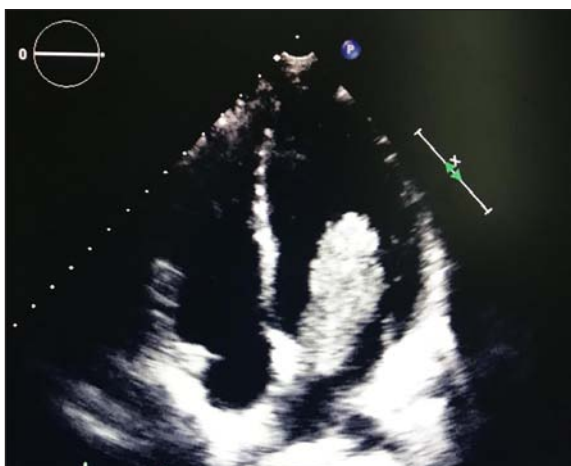

Figure 1: Transthoracic echo, apical 4 chamber view.

sweats, fatigue and general malaise. He was previously well with no significant past medical or family history. He had a low grade pyrexia and cardiac auscultation revealed a diastolic murmur consistent with “tumor plop”. He had no sequelae of endocarditis. He had low grade pyrexia of 37.7°, and ECG showed sinus tachycardia at 130 bpm. He had raised inflammatory markers and was started on broad spectrum antibiotics. Blood cultures grew *Streptococci viridans* twice.

Results

Trans-thoracic and trans-oesophageal echocardiography revealed a large mobile mass attached to the intra-atrial septum, suspicious for atrial myxoma, flopping into the left ventricle but not causing LVOT obstruction. All valves looked normal in appearance (**Figure 1**). He was treated with antibiotics for 2 weeks until inflammatory markers normalised. The patient was referred for cardiothoracic surgery where a large atrial myxoma (5 cm × 3 cm) was excised just superior to the mitral valve. It had areas of necrosis and was colonised with *Streptococci viridans*. He had an unremarkable postoperative course and made a complete recovery.

Take Home Message/Conclusions

Cardiac neoplasms (of which atrial myxoma is the most common) can present with vague constitutional symptoms. Prompt echocardiography is required to make a definitive diagnosis and facilitate referral to cardiothoracic surgery for definitive treatment. Atrial myxomas can rarely become necrosed and infected and mimic infective endocarditis.

A rare case of right sided endocarditis of the Eustachian valve

Saad Ahmad and Waqas Khan

Lancashire Teaching Hospitals NHS Trust, Preston, UK

Introduction

Right sided infective endocarditis is often associated with tricuspid valve infection in a cohort of patients who are intravenous drug users or those that have indwelling catheters or wires. Eustachian valve endocarditis is a much rarer occurrence, particularly because the remnant that is the Eustachian valve is uncommon in adults. Thought to be a rudimentary structure, this is an embryological vestige of the sinus venosus. Its role is in fetal blood circulation and though there is a natural disintegration post-partum, a small minority of 4% of people have a redundant Eustachian valve.

Case Description

The colonisation of the valve by organisms such as *Staphylococcus Aureus*, *Klebsiella*, *E. Coli* and *Actinomyces* has been described. We discuss a challenging case determined on trans-oesophageal echocardiography. Such cases have been reported few and far between in medical literature.

Results

Findings of a vegetation on a Eustachian valve on TOE representing a rare case of right sided endocarditis (supported by clinical, biochemical and microbiological evidence).

Take Home Message/Conclusions

The importance of thorough ultrasonic/echocardiographic assessment in determining infective endocarditis and Eustachian Valve endocarditis. It is imperative to combine clinical, radiological and microbiological aspects in concluding such a diagnosis. Such is the essence of a multi-disciplinary approach and holistic patient care. No conflict of interest declared.

How do you die in the middle of the night with a normal chest X-ray, a normal ECG and normal cardiac enzymes?

Thomas Derrick Wilton
Specialist Physician, Johannesburg, ZA

Introduction

This is the case of a *congenital hemi-non-development of the pericardium*. The patient presented with a normal ECG, a normal chest X-ray, normal enzymes and a normal cardiac sonar.

Case Description

A forty year old woman woke up at 2 a.m. with severe chest pains. She was immediately brought to hospital, where a chest X-ray and an ECG were taken and immediate clinical attention was given.

Results

The findings were:

1. normal ECG
2. normal Chest X-ray
3. normal blood tests
4. full normal cardiac sonar

In view of minute abnormality of the right cardiac silhouette and suspicion of congenital abnormality of the pericardium, a CT of the heart was conducted. A *congenital hemi-non-development of the pericardium* was diagnosed and the patient was put on a low dose of beta blocker. Four years later she continues well and asymptomatic.

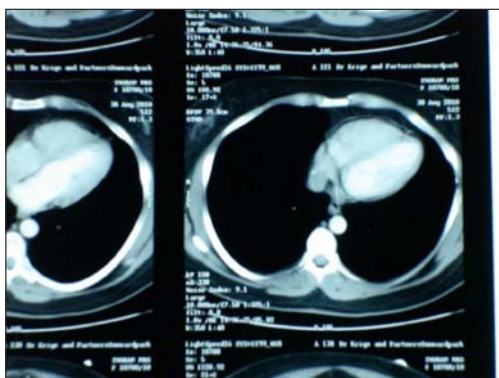


Figure 1.

Take Home Message/Conclusions

An amazing case – 2 cases in 50 years. Cardiologists and physicians should be on alert for any deviation of the cardiac silhouette. Before settling on the diagnosis of a hiatus hernia, a congenital hemi-non-development of the pericardium should be considered in order to prevent a cardiac herniation as a result of this condition.

The Doctor, the Patient and the Learning – Transforming Healthcare through Personalised Learning

Mairi Scott
Centre for Medical Education, School of Medicine
University of Dundee, Dundee, UK

Transforming Health Care to meet the ever-increasing demands of complex co-morbidity and complexity is a challenge that many countries' healthcare system need to address. It seems clear to all that there must be a fundamental re-think about the shape of models of health care delivery as doing 'more of the same' is not sustainable. One approach to this re-think is to increasingly collaborate across the disciplines however doing that is not always as easy as it might seem. Different disciplines have different values, priorities, skills, relationships and even approaches to professional learning and training and all these need to be understood for enhanced collaboration.

One way of understanding these differences is through regular multi-disciplinary (team based) learning based on the collaborative review of individual patient's journeys. Whilst this tried and tested approach helps bridge the gap among clinical disciplines it is only when experienced professionals are enabled to access the personalised learning opportunities available that they can then embed that learning into their own practice.

Reflective Practice is the key to personalised learning as it creates a culture of continuous reflection that enables professionals to become not just agents of change but also what Zohar and Marshall (2004) describe as masters of their craft able to "draw on their craft's collective pool of wisdom and skills ... through a system of shared understanding distinctive of some wider thinking or shared vision." They "see opportunities and possible innovations where others don't" which is an essential part of being able to fundamentally re-think patient care and an absolute guarantee that they will never again settle for doing 'more of the same'!

References

Zohar, D and Marshall, L. 2004. *Spiritual Capital Wealth we can live by*. Berrett-Koehler Publishers Inc.

Enhancing clinical case reporting by case-based learning vignettes

Harm Peters¹ and Gunver Kienle²

¹ Charité – Universitätsmedizin Berlin, Berlin, DE

² Institut für angewandte Erkenntnistheorie und medizinische Methodologie an der Universität Witten/Herdecke, Freiburg, DE

Background

Clinical case reports substantially contribute to the generation of new knowledge and understanding in the presentation, diagnosis and treatment of many disease entities. CARE Reporting (CARE) guidelines support transparency and accuracy in the publication of case reports and encourage clinicians to systematically report information from the point of care. The readership of individual clinical case reports is often small and their educational value and dissemination is limited. Goal of this workshop is to introduce to a new concept how the educational impact of clinical case reporting can be facilitated by using the learning and teaching through formal case-based learning. Case-based learning is a teaching format that allows the learner to go through the clinical reasoning process in a structured, transparent manner from initial problem presentation to finding a solution to the individual patient case.

Structure of Workshop

The workshop moderators will introduce the concept and implementation of both state-of-the-art clinical case reporting according to the CARE guidelines and designing case-based learning vignettes. Participants in small groups will be provided with existing clinical case reports and will be guided step-by-step in the process that converts a clinical case report into case-based learning vignette. Whole group discussion of results will generate key principles for this process and develop approaches that can be applied to participant's varying clinical contexts.

Intended outcomes

Participants will learn about the key principles of enhancing clinical case reporting by case-based learning vignettes and how this can be applied in practice to their clinical contexts. In addition, they will have opportunities to share and learn from each other's perspectives and clinical context-specific experiences while exploring a new educational approach to increase the utility and dissemination of reported clinical cases.

References

Riley, DS, et al. 2017a. CARE guidelines for case reports: Explanation and elaboration document. *Journal of Clinical Epidemiology*, 89: 218–235. DOI: <https://doi.org/10.1016/J.JCLINEPI.2017.04.026>

Diagnostic Utility of Cardiac Electrical Biomarker (CEB™) in predicting myocardial Injury in patients presenting with Chest pain to the Emergency Department (ED); VECTRA-CEB study

Felicia Adjei^{1,2} and Attila Kardos¹

¹ Milton Keynes University Hospital NHS Foundation Trust, Buckinghamshire, UK

² University of Buckingham, Buckinghamshire, UK

Introduction

Presentations with chest pain (CP) to the ED accounts for over six percent of all attendances. Although, more than 80 percent of these patients require admission, only about a quarter are finally diagnosed with Myocardial Infarction (MI). Current guidelines for diagnosis of acute coronary syndromes (ACS) involve clinical assessment, acquisition of a 12-lead Electrocardiogram (ECG) and serum biomarkers, such as Troponin (TN). The Cardiac Electrical Biomarker (CEB™) derived instantaneously from the acquired ECG, has been shown to have high positive and negative predictive value in diagnosis of Acute STEMI compared with ST segment analysis on conventional ECG.

Case Description

The diagnostic accuracy and utility of the CEB in predicting myocardial injury in comparison to high sensitivity TN (hsTN) is uncertain. In this prospective, multi-centre study, we aim to define the performance characteristics of the CEB in predicting acute myocardial injury in consecutive patients presenting with chest pain. 450–500 patients presenting to the ED with CP will be recruited to assess the performance of CEB compared to serum hsTN. Patients will have ECG recorded and CEB derived in parallel with serum hsTN. Baseline patient characteristics, cardiovascular risk factors, and cardiovascular endpoints of fatal/non-fatal MI, death will be recorded.

Results

The performance characteristics of the CEB will be calculated using metrics of positive predictive value (PPV), negative predictive value (NPV), sensitivity & specificity, and receiver-operating-characteristic (ROC) curves to assess the diagnostic accuracy for the diagnosis ACS. The primary outcome will be the diagnosis of myocardial injury/myocardial infarction by the conventional hs-TN and the CEB based diagnostics.

Secondary outcome will be derived from modelling the difference between standard clinical care and CEB guided management on 30 days and 12 months cardiovascular mortality, the composite of fatal and nonfatal MI, readmission with progressive angina, and need for unplanned revascularisation.

Take Home Message/Conclusions

Once the diagnostic accuracy of the CEB has been determined, its utility could reduce the waiting time in ED, facilitate timely diagnosis of ACS and prevent unnecessary admissions. In addition, the study will be able to assess the long-term stratification power of the CEB in patients presented with CP to the ED. Thus this could lead to early discharge and/or intervention if needed. The potential clinical benefits to patients and cost effectiveness to healthcare providers could be significant.

Latest developments in regenerative medicine

Bruna Corradetti

Department of Nanomedicine, Houston Methodist Research Institute, Houston, TX, US

The wound healing process develops along three main phases: inflammation, regeneration and remodeling. When tissue engineering approaches are required, they are usually applied during the inflammatory phase, to recruit and stimulate resident and circulating cells for a successful tissue regeneration. As such, an implanted material can positively or negatively modulate this cascade of events, culminating in a constructive remodeling response, a persistent inflammatory response, a foreign body response, or an adaptive immune response. Endogenous cell stimulation can be achieved by applying bioactive cell-therapy, as in the case of stem cell manipulation, or by developing smart biomimetic materials able to guide tissue regeneration at multiple levels. Understanding the fundamental steps occurring during tissue homeostasis and wound healing is the starting point to develop materials that can efficiently provide: i) tissue structure and mechanical properties, ii) bioactive cues to the residing cells for migration, attachment, proliferation, and differentiation, iii) the regeneration-permissive environment able to initiate the natural body's healing potential, thus avoiding robust and often chronic immunologic response by host tissue that is currently a pervasive threat for infectious or functional complications. The translation of such approaches to the clinic provides an alternative solution to the therapies and surgical procedures currently used to rescue tissues' loss of function.

Replacing the azygos vein over bronchial anastomoses contributes the rapid postoperative recovery

Mertay Boran¹ and Ertay Boran²

¹ Duzce University, Faculty of Medicine, Department of Toracic Surgery, Duzce, TR

² Duzce University, Faculty of Medicine, Department of Anesthesiology, Duzce, TR

Introduction

Carcinoid tumors are the second most common tumor type arising in the tracheobronchial tree and account for 0.5–1.0% of all tumors of bronchial origin. Pulmonary parenchymal-saving procedures are usually preferred in patients with carcinoid tumor. We revealed a bronchial sleeve resection in which bronchial anastomosis is protected with azygos vein in a patient with right intermedial carcinoid tumor.

Case Description

Smooth-edged endobronchial lesion in the upper part of the intermediate bronchus was detected (Thoracic CT – **Figure 1**) at a 35-year-old male patient with complaints of short-term bloody sputum occasionally for 3 years. Bronchoscopic biopsy revealed a tumor with end-stage neuroendocrine differentiation. Right thoracotomy was performed and the intermediar bronchus was cut immediately beneath the bronchial upper lobe entrance and just above the medial and lower lobe openings. After negative reporting of surgical margins with frozen examination, anastomosis was completed with continuous stitch tech-

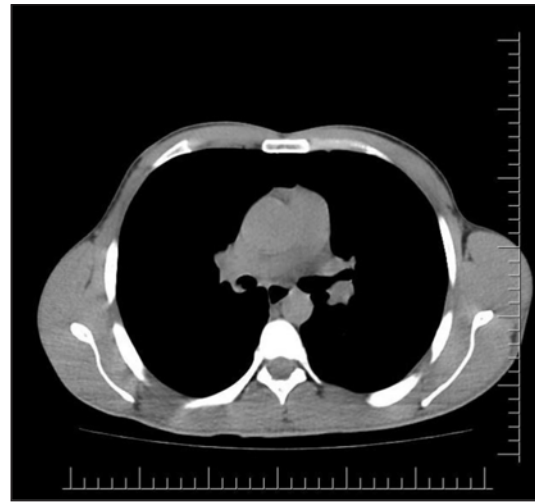


Figure 1: Intraoperative view.

nique with 4/0 prolene. After the vena azygos was partially liberated at the level of the parietal pleura it was placed on the anastomosis. Thoracic CT and bronchoscopy performed at the control of the second year showed no pathological findings.

Results

We recommend the continuous suture technique and replacing the azygos vein over bronchial anastomosis. This technique contributes the rapid postoperative recovery and long-term follow-up without complications.

Take Home Message/Conclusions

The continuous suture technique and replacing the azygos vein over bronchial anastomosis contributes the rapid postoperative recovery and long-term follow-up without complications.

References

- Belak, J, Kudlac, M, Zak, V, et al.** 2010. Surgical management of bronchopulmonary carcinoid tumors: Experience over 8 years and review of the literature. *Tumori*, 96: 84–89. DOI: <https://doi.org/10.1177/030089161009600114>
- Maurizi, G, D'Andrilli, A, Venuta, F and Rendina, EA.** 2016. Reconstruction of the bronchus and pulmonary artery. *J Thorac Dis*, 8(2): 168–180.
- Venuta, F, Diso, D, Anile, M and Erino, A.** 2016. Rendina Techniques of protection and revascularization of the bronchial anastomosis. *J Thorac Dis*, 8(2): 181–185.

A different endoscopic technique in Morgagni hernia repair

Derya Yayla¹, Ertay Boran² and Mertay Boran³

¹ Samsun Education and Research Hospital, Department of Pediatric Surgery, Samsun, TR

² Duzce University, Faculty of Medicine, Department of Anesthesiology, Duzce, TR

³ Duzce University Faculty of Medicine, Department of Toracic Surgery, Duzce, TR

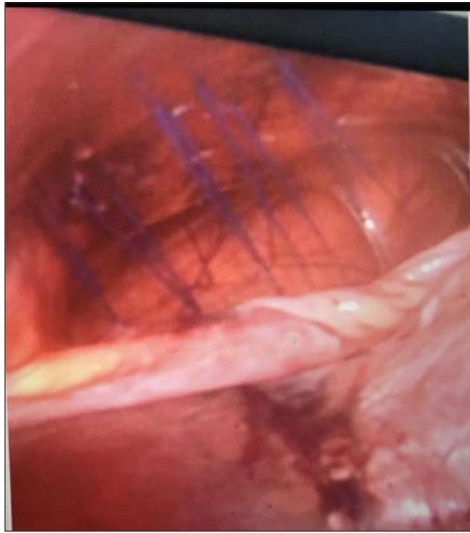


Figure 1: Intraoperative view of the sutures.

Introduction

Morgagni hernia is rarely seen among congenital hernias. In all diaphragmatic hernias, it is 3–4%. It is usually asymptomatic and is detected incidentally during routine radiological examinations. It may cause respiratory or gastrointestinal symptoms. Currently, endoscopic treatment approaches are preferred in the treatment of Morgagni hernia. In pediatric patients, laparoscopic single primer repair with single stitches is often done. In this case report, we present a 15-year-old patient diagnosed with Morgagni hernia and treated with a different endoscopic method.

Case Description

Morgagni hernia was found on the PA chest X-ray and thorax tomography of the 15 years aged and 80 kg male patient who had recurrent dry cough for 1 month. Three trocars with 5 mm in diameter were placed on the middle, on the right side and on the left side. After the laparoscopic exploration, the small intestines passing through the 8 × 5 cm defect in the anterior part of the diaphragm were decapitated by forceps. The 6 round needle 2/0 prolene passed through the skin were sutured to 6 U of the opposite sides of the diaphragm defect (Intraoperative view of the sutures- **Figure 1**). The 2nd year control was uneventful.

Results

An endoscopic approach should be preferred for the repair of Morgagni hernia because of low morbidity rate. We recommend the quick and safe laparoscopic technique of fastening sutures under the skin after passed them from the side of the defect.

Take Home Message/Conclusions

We recommend the quick and safe laparoscopic technique of fastening sutures under the skin after passed them from the side of the Morgagni hernia defect.

References

Esposito, C, Escolino, M, Varlet, F, et al. 2017 Aug. Technical standardization of laparoscopic repair of Morgagni diaphragmatic hernia in children: Results

of a multicentric survey on 43 patients. *Surg Endosc*, 31(8): 3320–3325. DOI: <https://doi.org/10.1007/s00464-016-5365-0>

Hoyos, DA. 2009. Foramen of morgagni hernia. In: Shields, TW, Locicero, J, III, Reed, CE and Feins, RH (eds.), *General Thoracic Surgery*, 719–24. 7th ed. Philadelphia: Lippincott Williams and Wilkins.

Zouari, M, Jallouli, M, Bendhaou, M, Zitouni, H and Mhiri, R. 2015. Percutaneous suturing technique and single-site umbilical laparoscopic repair of a Morgagni hernia: Review of three cases. *Arch Pediatr*, 22(12): 1272–5. DOI: <https://doi.org/10.1016/j.arcped.2015.09.017>

Spa session and neck massage at birthday party leading to serious brain bleeding

Mohamed Eltayeb and Sarin Kuruvath

Queen Elizabeth-University Hospital of Birmingham, Birmingham, UK

Introduction

Intense cervical manipulation is known to cause vertebral arteries dissection and subsequent stroke is the most common presentation. In rare cases, SAH would be the presentation of vertebral artery dissection (VAD) especially with unknown comorbidities. In this report, we present the case of a female who is generally fit and well with SAH after spending a day at a spa and after having intense neck massage. As far to our knowledge, this could be the first reported case in the U.K. with this unusual aetiology.

Case Description

A 54 year old female without any chronic illnesses presented to the A&E department with complaint of severe headache and blurring of vision. The patient vomited twice and suffered from nausea. The patient was a non-smoker, unmarried without children and on no oral

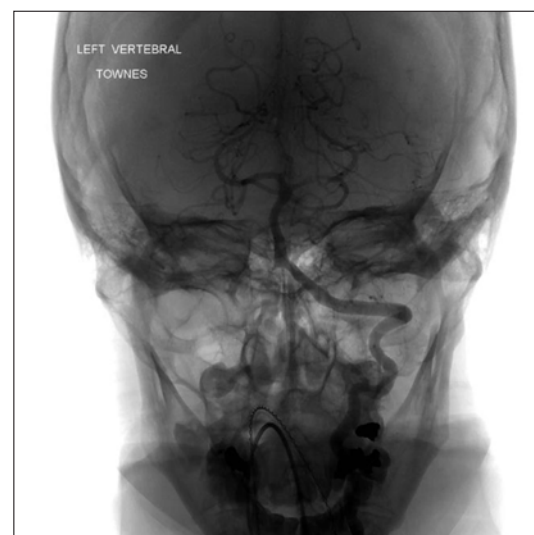


Figure 1.

contraceptives. Two days prior to admission, the patient had an intense neck massage at a spa. The clinical exam revealed no neurological deficit. A head CT was obtained for further assessment of the headache. Radiological findings lead to the decision of taking a digital subtracted angiogram (DSA).

Results

The head CT showed a subarachnoid haemorrhage (SAH) with an early hydrocephalus. The digital Subtracted Angiogram (DSA) 12 hours later showed a right vertebral artery dissection (V4) distribution which was treated with embolization and occlusion. The patient has been followed up at the neurovascular clinic within the first year after the incidence and with other investigation including MR angiogram. No congenital vascular anomaly was found and the patient did not experience any further complications.

Take Home Message/Conclusions

Despite its recreational purposes, some habits and activities can affect us seriously, as this case of an otherwise healthy woman shows. Our conclusion is that we have to take any case on its own merit and not jump to conclusions if the aetiology is not convincing.

Atypical presentation of recurrent jejunojejunal intussusception due to ectopic pancreas in a young male

Hugo Bonatti

University of Maryland Community Medical Group, Easton, MD, US

Introduction

Intussusception may be caused by a variety of conditions and more commonly involves the ileum. Jujunojejunal intussusception is a rare condition and may originate from intramural tumors. Ectopic pancreatic tissue may be found throughout the entire gastrointestinal track causing no symptoms.

Case Description

A 29 year old African American male presented with abdominal pain to the emergency room. As a child he had multiple trips to the ER for abdominal pain without definite diagnosis. An exploratory laparotomy five years ago, when an intussusception was found on CT-scan, did not reveal a diagnosis. Until 3 months prior to the new episode of recurrent pain, cramping, and nausea he had been asymptomatic. The CT-scan showed recurrent proximal small bowel intussusception. An extensive work-up did not reveal any diagnosis. After multiple readmissions an indication for exploratory laparotomy was made.

Results

During surgery, no intussusceptions was found but a small yellowish lesion at 10 cm past the ligament of Treitz was detected (**Figure 1**); the small bowel proximal to the

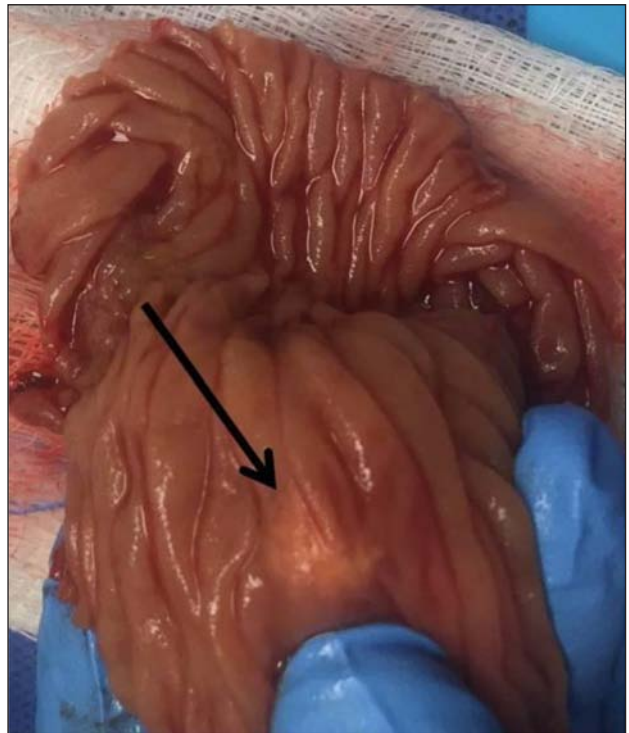


Figure 1: 1 cm yellow lesion in proximal jejunum (arrow).

lesion was dilated. A segment jejunal resection containing the 1.5 cm lesion was performed. Pathology revealed a transmural lesion consistent with ectopic pancreatic tissue. The immediate postoperative course was uneventful and the patient improved; however, he continued to have episodes of abdominal cramping but further workup was negative; we believe he had developed a chronic motility disorder due to the repeated dilatation of the duodenum and proximal jejunum associated with the recurrent intussusceptions.

Take Home Message/Conclusions

We present a rare case of ectopic pancreas causing recurrent jejunojejunal intussusceptions in an adult; these small lesions may be difficult to find and should be surgically removed as the recurrent obstructions may cause long term damage to the proximal intestinal segments.

Penile metastasis as an unusual presentation of testicular non-seminomatous germ cell tumor (NSGCT)

Stefania Pipitone¹, Annalisa Guida¹, Maria Giuseppa Vitale², Vittoria Tarantino¹, Davide Cerioli¹, Maria Elisabetta Filieri³, Roberto Sabbatini² and Stefano Cascinu¹

¹ University of Modena and Reggio Emilia, Modena, IT

² Policlinico di Modena, Modena, IT

³ Arcispedale S. Maria Nuova, Reggio Emilia, IT

Introduction

Penile metastasis from testicular cancer is a rare condition.

Case Description

A 45-year-old man patient presented to the clinic with palpable thickening of the penis appeared three months before. He had negative personal medical history and no sexually transmitted disease history. A fixed, hard, erythematous nodule (2.5 cm) was observed on the proximal third of the penis. The patient exhibited an ultrasound and a magnetic resonance imaging (MRI) showing a malignant lesion (3.5 cm) of both corpora cavernosum. A fine-needle aspiration biopsy of penile nodule diagnosed metastasis from germinal carcinoma. Further evaluations included testis ultrasound and measurement of alpha-fetoprotein (AFP), beta-human chorionic gonadotropin (β CGH) and lactate dehydrogenase (LDH).

Results

Right testis lesion was found and the patient underwent standard orchiectomy. Tumour was composed of embryonal carcinoma (60%), yolk sac tumour (30%) and teratomas (10%). Post-orchiectomy AFP was 267.5,5 ng/mL, β CGH was 6529 mUI/mL and LDH was 360 U/L (230–460). Only three of the four planned courses of BEP (cisplatin, etoposide, bleomicine) were administered, because of persistent penile infection. After systemic treatment serum markers were normalized with residual mass of the penis (2.3 cm). A close monitoring was performed. After 40 months from diagnosis the patients is still followed.

Take Home Message/Conclusions

Penile metastasis from testicular cancer is uncommon. To our knowledge, only 11 cases have been described in literature. Patients with non-pulmonary visceral metastases should be considered poor risk, based on the International Germ Cell Cancer Collaborative Group classification. It is debated whether penis lesion is a visceral site. The option of surgical removal of residual penis disease was discussed. Patient's desire and lesion dimension (less than 3 cm) were both taken in account. With this clinical case we report our experience with a rare condition, focusing on its unusual clinical presentation, difficult prognostic assessment and identification of the best therapeutic approach.

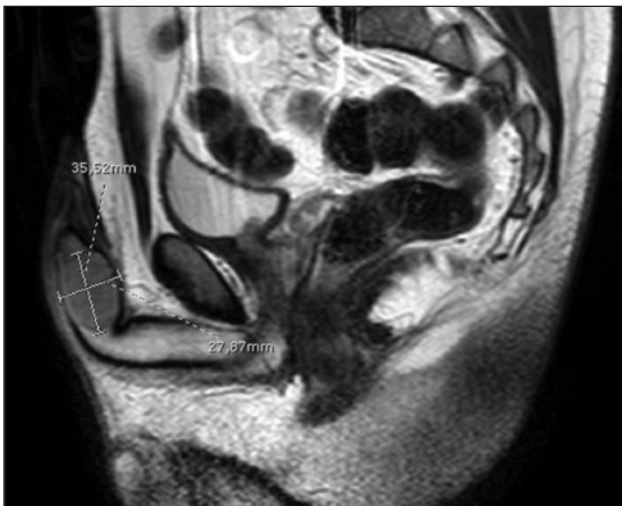

Figure 1.

Poster Abstracts

Hard to swallow

Guilherme Piovezani Ramos, Matthew Hardman, Nikhil Kolluri, Muneeb Rehman and Thomas Poterucha
Mayo Clinic, Rochester, US

Introduction

Dysphagia is a relatively common symptom, occurring in approximately 3% of the general population. Depending on which stage of deglutition is affected, it can be characterized as oropharyngeal or esophageal. Prevalence increases with age and, in the elderly, it is primarily associated with an oropharyngeal component. In younger populations, the epidemiology is uncertain, but has been more commonly associated with esophageal dysfunctions. Here, we report an unusual cause of dysphagia in a young female.

Case Description

A 38-year-old female with history of depression, presented for evaluation of recurrent dysphagia for the past 6 months. Symptoms started with difficulty with liquids and progressed to both liquids and solids. She endorsed choking, coughing and a sensation of food stuck in her throat. There were no focal neurologic signs on physical examination and her abdomen was benign. Video-swallow evaluation demonstrated marked pharyngeal-esophageal dysphagia with impaired relaxation of the cricopharyngeus muscle with possible neurogenic etiology. Neurology evaluation including lumbar puncture, auto-immune panel and an MRI of the head was negative. ENT evaluation due to concomitant hoarseness, demonstrated vocal cord paralysis and she underwent vocal cord tissue matrix injection without improvement. The upper endoscopy demonstrated normal esophagus without pharyngeal abnormalities. Therapeutic dilation of the cricopharyngeus muscle was also performed during endoscopy without improvement on symptoms. Esophageal manometry was unsuccessful due to pharyngeal hypersensitivity and inability of drinking boluses of fluid. Given the significant weight loss and the persistence of symptoms, a percutaneous gastrostomy tube was placed for initiation of enteral nutrition. Psychiatry was consulted and proposed the patient's symptoms were exacerbated due to uncontrolled anxiety and fear of swallowing ('phagophobia'). She was ultimately diagnosed with psychogenic dysphagia and initiated on pharmacologic anxiety management.

Results

'Phagophobia', a fear of swallowing, is a form of psychogenic dysphagia. It is characterized by various significant swallowing complaints with normal physical examination and laboratory findings. Only sparse case series have been reported in the literature, but it can result in significant weight loss and malnutrition. Although it can be commonly associated with depression and anxiety symptoms, most patients do not actually have a formal psychiatric diagnosis. The patient's history, physical examination, laboratory and radiologic evaluation are important to

distinguish psychogenic dysphagia from organic dysphagia, as performed in the present case. Other psychiatric disorders such as conversion disorder, anorexia nervosa and bulimia nervosa should also be ruled out. It has been proposed that phagophobia is most often the result of a direct conditioning experience. The present patient had a significant history of abuse that preceded the initial presentation by a few months.

Take Home Message/Conclusions

By reporting an unusual cause of dysphagia in a young female, we describe a systematic approach evaluation of patients presenting with dysphagia in addition to describing specific characteristics of phagophobia as a cause of psychogenic dysphagia.

HSV-1 encephalitis: Is the insight of the clinician still crucial for the outcome? A report of two cases

Dimitrios Patoulas, Georgios Gavriiloglou, Mairi Tzakri, Angeliki Sevastoudi, Konstantinos Kontotasios, Petros Keryttopoulos and Christos Koutras
Department of Internal Medicine, General Hospital of Veria, Veria, GR

Introduction

HSV encephalitis is an acute infectious disease of the central nervous system, usually affecting the limbic structures, the median temporal cortex and the orbitofrontal regions. Its annual incidence has significantly increased over the last 20 years and the mortality rate is 7% if early diagnosed and treated, while it reaches up to 70%, if left untreated.

Case Description

We present the cases of HSV-1 encephalitis in two women, 76 and 56 years old, respectively. The main clinical manifestations in both patients were: fever and mental status alteration. The neurologic examination revealed: anomic aphasia, sentence repetition, disorientation in time and space in the first patient and aphasic disturbances and right central facial nerve paralysis in the second patient. Before the completion of diagnostic documentation of HSV encephalitis (brain MRI scan and CSF PCR analysis), we administered early after the patients' admission treatment with acyclovir, due to high index of clinical suspicion, without further delay.

Results

CSF PCR analysis and brain MRI scan documented the clinical diagnosis of HSV-1 encephalitis in both patients. After the completion of the therapeutic regimen with acyclovir, they were discharged home in good general condition, without neurologic deficits.

Take Home Message/Conclusions

We believe that the diagnostic and therapeutic strategy of the clinician should be based upon the parameter of

economy of time, as there is absolute indication for early administration of acyclovir in highly suspected cases. However, even when a CSF analysis is within normal limits, imaging studies are not specific and a PCR test is negative, diagnosis of HSV encephalitis cannot be ruled out, if the clinical presentation is highly indicative.

Unexpected finding of left ventricular clots by transesophageal echocardiography during cardiac massage after resuscitative thoracotomy on a trauma patient

Arthur Hill¹ and Julin Tang²

¹ UCSF/ZSFG, San Francisco, US

² UCSF/ZSFGH, San Francisco, US

Introduction

Close-chest cardiac massage is currently the routine practice for cardiac arrest. Despite lacking clinical evidence for improvement of mortality, the open-chest direct and rhythmic cardiac massage has regained its popularity during the cardiac arrest in severely injured traumatic patients. We are presenting a case with unexpected intraoperative transesophageal echocardiographic finding and are speculating on the potential harmfulness of open cardiac massage with multiple intracardiac injections of vasoactive medications.

Case Description

A 35-year-old male presented to the emergency department after an unwitnessed pedestrian versus automobile injury. GCS was 3 with SBP in the 70s. FAST exam revealed positive for intraperitoneal blood. The left chest was decompressed with angiocath after eFAST showing absent lung-sliding sign. Massive blood transfusion started through a right femoral venous catheter and the patient was emergently transferred to OR for damage control. The patient was induced and intubated. Exploratory laparotomy was performed and abdominal packs were placed in all four quadrants. The patient continued to have low BP in the 70's. A very large right-sided liver crush injury was noted.

Results

The patient had persistent metabolic acidosis with a PH of 7.09. The TEE monitoring progressively showed that his heart started to fail. Left thoracotomy was performed and cardiac massage was initiated. Epinephrine and vasopressin were also injected directly to the left ventricle. PT was 21.8, INR 1.9, PTT 60. He had also received 15 joules × 3 defibrillation for ventricular fibrillation. Unexpectedly, TEE began to reveal the formation of multiple blood clots in the left ventricle despite of INR 1.9 at the end of the last five minutes of resuscitation. The patient had ongoing profound hypotension and acidosis. Ultimately, he became asystolic and was pronounced death.

Take Home Message/Conclusions

We are presenting a case to emphasize the potential harmfulness of vigorous direct cardiac massage plus multiple

intracardiac injections during cardiac arrest. The damaged sub-epithelial cells and fibroblasts of myocardium in the left ventricle might have triggered the release of tissue factor for which the clot formation ensued. Finally, we still are unable to completely rule out the contribution of direct intracardiac defibrillation, only 15 joules \times 3, in the clot formation of the left ventricle.

Emergency c-section in systemic sclerosis (Ss): multidisciplinary management

V. La Rosa¹, G. Scarpinati², S. Scollo¹, P. Murabito¹ and M. Astuto¹

¹ Department of Anaesthesia and Intensive Care, Policlinico Universitario 'G. Rodolico', Catania, IT

² Department of Anaesthesia and Intensive Care, Ospedale Santo Bambino, Catania, IT

Introduction

Systemic sclerosis (Ss) is an autoimmune disease, characterized by deposition of extracellular collagen in multiple organs; it is associated to vascular dysfunction and connective tissue fibrosis. We present the case of a 36-year-old nulliparous woman affected by Ss who underwent emergency caesarean section for non-reassuring fetal heart rate (NRFHR). Our patient was diagnosed with Ss at 16 years old, following Raynaud's phenomenon and digital ulcers. She presented typical Mausekopf Facies, she had multiple telangiectasias, microstomy, thin lips and a pinched nose; she showed Mallampati IV secondary to poor oral aperture; she also presented sclerodactyly and digital ankylosis.

Case Description

Due to the rapid progression and severity of the disease, the patient underwent an autologous transplant, an off label treatment for Ss. Her clinical situation remained stable, HRCT showed no progression in pulmonary fibrosis and the echocardiography did not show any sign of pulmonary hypertension. She was admitted to hospital at 26 week of gestational age for oligohydramnios. Conservative therapy with bed rest and hydration were performed. The paediatrician and obstetrician considered 32 week as an acceptable gestational age to perform elective caesarean section. Considering a difficult airway management, we planned rendez-vous with thoracic surgeon in order to perform endotracheal intubation with flexible intubation scope.

Results

We also placed an ultrasound-guided central venous catheter in the internal jugular vein because peripheral access was difficult to obtain due to skin thickness. During her hospital stay, the patient developed gestational hypertension; she then showed preeclamptic signs such as worsening proteinuria, peripheral oedema and therapy-resistant hypertension. At 30 weeks gestational age, emergency caesarean section was performed for NRFHR. As many scientific papers suggest, we planned epidural anaesthesia as first treatment option for the caesarean section, spinal anaesthesia was a second line option and, as previously

cited, general anaesthesia with fiberoptic intubation would have been the last extreme choice.

Take Home Message/Conclusions.

Standard monitoring was used throughout surgery including NIBP, SpO₂ and ECG. An experienced anaesthetist performed 4 attempts to place an epidural catheter but there was difficulty of advancement in various interspaces. Spinal anaesthesia with Hyperbaric Bupivacaine 0.5% 12 mg and Fentanyl 20 μ g was performed after 3 attempts. The patient was stable during surgery. A female baby (1450 grams) was born with Apgar score 8 and 9 at 1 and 5 minutes. The caesarean section was uneventful and she also had a good response to oxytocin. The motor block level regressed after 4 hours. Her post-operative period was uneventful; she was discharged after 5 days.

Severe babesiosis with intravascular hemolysis in a patient with asplenia – The importance of RBC exchange transfusion

Emily Klug¹, Baharath Raj Palraj² and Ala Dababneh²

¹ Mayo Clinic Health System, La Crosse, US

² Mayo Clinic, Rochester, US

Introduction

Babesiosis is a tick borne illness with a wide array of symptoms depending on the host's immune status. Those with immunosuppression from asplenia, HIV, or certain cancer or transplant medications are at high risk of developing severe illness and complications. Complications are seen more frequently with a hemoglobin <10 g/dL and high parasite load (>10 percent). We report a rare case of babesiosis in an asplenic patient causing intravascular hemolysis and requiring RBC exchange transfusion.

Case Description

A 64-year-old male with a history of Hodgkins lymphoma in remission and asplenia presented with a 4-day history of fevers, chills, night sweats and darkening urine. He was initially febrile to 39.3°C with no obvious source of infection on admission. Urinalysis showed 3–10 red blood cells and 4–10 white blood cells. The CT of the chest, abdomen and pelvis to evaluate for recurrence of lymphoma showed no acute infectious process and no obvious recurrence of lymphoma. Lumbar puncture did not indicate meningitis or meningioencephalitis. The labs showed a hemoglobin of 10.0 g/dL, AST of 254 U/L, ALT of 88 U/L, total bilirubin of 3.4 mg/dL, LDH of 1645 U/L, haptoglobin of <14 mg/dL and a lactic acid of 3.7 mmol/L.

Results

The patients labs showing indirect bilirubinemia, elevated LDH, low haptoglobin, hematuria, anemia, elevated reticulocytosis and elevated lactate was strongly suggestive of intravascular hemolysis. Given known tick and mosquito exposure this was concerning for severe babesiosis. Babesia smear came back showing 16.6% parasitemia. The patient was started on oral quinine 650 mg twice daily,

Intravenous Clindamycin 600 mg every 6 hours and Doxycycline 100 mg twice daily. The spleen needs to be filtered and red blood cells which are infected with parasites such as babesia and malaria need to be removed. Given his high level of parasitemia as well as anemia in the setting of asplenia, he received a red blood cell exchange transfusion twice lowering his parasite load to 10.1 and 3.27, respectively. The hospital course was complicated by respiratory failure requiring intubation and hypotension requiring multiple vasopressors. After a protracted hospital course, the patient made full recovery. His Quinine was transitioned to Azithromycin and Atovaquone for 6 weeks of therapy. He also received 3 weeks of Ceftriaxone for possible concurrent Lyme carditis. His babesia smear trended down to <0.01% parasitemia after four weeks of therapy.

Take Home Message/Conclusions

Babesiosis can cause significant morbidity and mortality in the setting of an immunosuppressed host. A high index of clinical suspicion should be had in any patient presenting hemolysis in tick endemic areas. In those with risk factors specifically asplenia early exchange transfusion therapy is critical for improved outcomes.

Incomplete masculinisation of two 46,XX SRY-negative male brothers with SOX-9 regulatory element duplication

Éva Pinti, Anna Lengyel, Andrea Luczay, György Fekete, Irén Haltrich, Eszter Kiss and Zsuzsa Tóth
Department of Pediatric, Semmelweis University of Medicine, Budapest, HU

Introduction

The sex-determining region on chromosome Y (SRY) is the critical gene that initiates male sex determination in humans. The role of SRY is the regulation of SOX-9 which is a crucial downstream target gene. Recent studies have shown that high expression of SOX-9 is sufficient to trigger male development in the absence of SRY and can lead to incomplete masculinisation despite a 46,XX karyotype.

Case Description

Two brothers were born with incomplete masculine phenotypes. They had bilaterally palpable gonads and hypospadias. The older brother's MRI and histological examination revealed a normal sized prostate, a scrotal ovotestis on the right side and an atrophic testis with decreased Sertoli and Leydig cells and germinal cell aplasia on the left side. Hormone levels showed increased free and total testosterone with low estradiol. The younger boy had bilateral scrotal ovaries and a closed tubular structure behind the bladder that may be a Müllerian duct remnant. He had increased estradiol levels and a negligible quantity of testosterone.

Results

Giemsa-staining showed that both children had 46,XX karyotypes. Fluorescence in situ hybridization (FISH) analysis did not identify the presence of SRY gene on either

X chromosome. Array comparative genomic hybridization (array-CGH) analysis of the older brother identified a 143 kb duplication 540 kb upstream of SOX-9. Molecular genetic examination of the younger child and his healthy 46,XY father showed a very similar 155 kb duplication 605 kb upstream of SOX-9. Both children inherited the abnormal chromosome 17 with the duplicated SOX-9 regulatory element from their father. The mother was healthy and had a normal female karyotype.

Take Home Message/Conclusions

Over the past decades most efforts have been focused on disease-related candidate genes. New-throughput technologies such as array-CGH have revealed the importance of non-coding DNA in the process of gene regulation. The presented cases are new evidence that remote cis-acting enhancer elements may affect SOX-9 gene regulation by gain of function resulting in gene overexpression. Therefore the regulatory landscape of the genome should be included in research for disease-causing CNVs. Our findings are also important from a family planning perspective: of future potential children born to these parents half of the girls will be healthy.

Arteriovenous malformation pulmonary (AVM) in a post-cesarean woman: intensive care and urgent surgery operation

Francesco Oliveri¹, Christian Bonsignore¹, Ilenia Musumeci¹, Alberto Terminella², Giacomo Cusumano², Vito Sofia³ and Marinella Astuto¹

¹ Department of Anesthesia, University Hospital 'Policlinico – Vittorio Emanuele', Catania, IT

² Department of Thoracic Surgery, University Hospital 'Policlinico – Vittorio Emanuele', Catania, IT

³ Department of Neurology, University Hospital 'Policlinico – Vittorio Emanuele', Catania, IT

Introduction

Arteriovenous Malformations (AVMs) are malformations of the vascular system where the arteries, usually hypertrophic, discharge directly into one or more veins bypassing the capillary system. This process puts veins at higher pressures than the normal and increases the chance of a break with consequence hemorrhage. AVMs are rare, congenital, and often tardy disorders; they usually involve the brain, and rarely affect other organs as lungs, liver or the digestive tract.

Case Description

We are presenting the case of a 33-year-old woman at the 39th week of gestation. In her anamnesis there was no former notable condition, except for a hormonal stimulation for infertility problems for 1 year. The patient came to our observation from another hospital after an urgent caesarean section, because she displayed severe dyspnea, hypoxia, and a significant chest pain on arrival at the ER; those symptoms led colleagues to suspect pulmonary embolism and to treat her using heparin infusion. After she was transferred to our hospital, we performed a chest

CT which highlighted hemotorax with a subtotal atelectasia of the left lung, for breakdown of a pulmonary AVM of the basal area. Furthermore, we performed embolization procedure on AVMs arteries and alerted the thoracic surgery unit to position a chest drain, which resulted in an evacuation of approximately 1300 cc of blood. However, during her hospitalization in intensive care she started to bleed again from the chest drain, which resulted in a hemodynamic instability. According to the clinical presentation, chest surgeons immediately performed emergency thoracotomy in intensive care in order to produce hemostasis, and then an atypical resection of the left-lung lower lobe was performed in the operating room. Unfortunately, clonic-tonic crisis related to an altered EEG complicated the post-operative hospitalization in intensive care, and is likely to be a consequence of the initial hypoxia in ER.

Results

We were finally able to transfer the patient, who showed a total neurologic recovery, to the neurology ward after 26 days of intensive care hospitalization. Therefore, on a clinical basis, neurologists hypothesized a Rendu-Osler-Weber Syndrome, which is in an ongoing process of assessment in a specialized center.

Take Home Message/Conclusions

To which extent did the heparin infusion negatively impact the case? Due to the lack of literature of similar case studies of lung AVMs related to hormone therapy and heparin infusion, we are not able to ascertain how these procedures impacted the evolution of the clinical presentation, neither how this can be a result of the physiological changes which occurred during the pregnancy. However, we are able to claim that collaboration among different disciplines is pivotal in order to reach a solution connected to the surgical treatment of AVMs.

Chronic inflammation: immune system over-activity or deficiency?

Omar Yasin, Muneeb Rehman, Ryan Khodadadi, Alina Bridges and John Bundrick
Mayo Clinic, Rochester, US

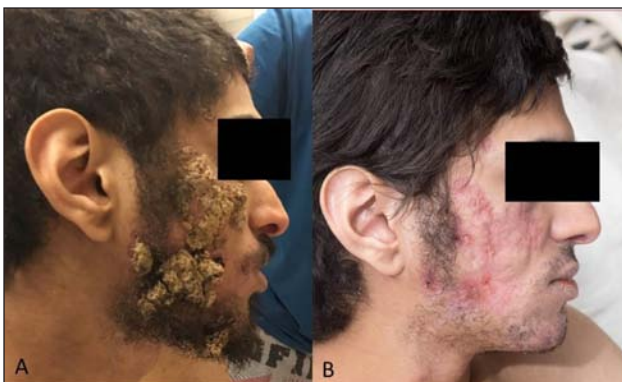

Figure 1: Facial lesions on presentation (A) and follow up (B) after treatment with IFN- γ , Trimethoprim-sulfamethoxazole, itraconazole and aggressive wound care.

Introduction

Chronic inflammatory conditions in adulthood are presumed to be secondary to infections or autoimmune disease. When immunodeficiency is considered, acquired conditions such as HIV are highest on the differential. We present a case of a 21-year-old gentleman with chronic inflammation causing non-healing skin ulcerations, who was diagnosed with chronic granulomatous disease (CGD), an inherited immunodeficiency secondary to neutrophil dysfunction.

Case Description

A 21-year-old male presented with a five-year history of skin ulcerations. He developed a raised, erythematous blister on his thigh productive of purulent material. The lesion ulcerated, crusted over, and was covered with dry, purulent material. These lesions spread to the rest of his body. Other than a 2 pack-year smoking history, he had no significant personal, social, or family history. The physical examination showed a cachectic male with purulent, crusted-over abscesses, punched-out ulcers, and draining sinuses in various stages of healing on his cheeks, axilla, lower extremities, back, and scrotum. These did not involve the oral mucosa, palms, or soles.

Results

A complete blood count showed microcytic anemia consistent with anemia of chronic disease, thrombocytosis consistent with acute inflammation, leukocytosis with differential of monocytes at 1.8 and eosinophils at 0.62. The infectious workup was negative for HIV, syphilis, tuberculosis, leprosy, leishmaniasis, HSV, CMV, and VZV. The immunologic workup was negative for autoimmune mucocutaneous blistering disorder. The skin biopsy showed dermal neutrophilic inflammation with pigmented macrophages, cicatricle fibrosis, and lymphoplasmacytic inflammation. Testing for neutrophil function showed a moderate decrease in dihydrorhodamine positive cells and profound decrease in mean fluorescence intensity after stimulation with Phorbol Myristate Acetate and N-formyl-L-methionyl-L-leucyl-L-phenylalanine (FMLP); compatible with CGD.

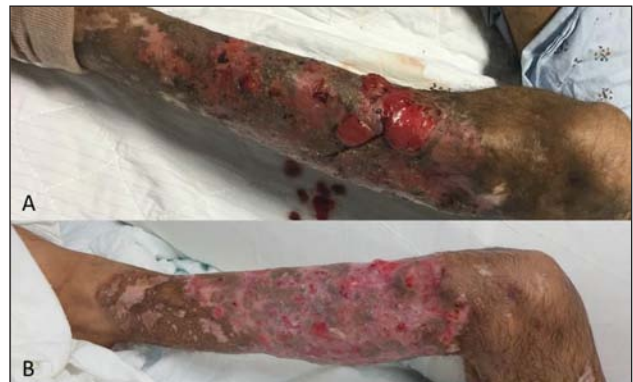

Figure 2: Left lower extremity lesions on presentation (A) and follow up (B) after treatment with IFN- γ , Trimethoprim-sulfamethoxazole, itraconazole and aggressive wound care.

Take Home Message/Conclusions

CGD is an inherited immunodeficiency caused by the impairment of the NADPH oxidase complex in neutrophils and monocytes, which results in the defective reactive oxygen species production needed to kill bacteria and fungi. Infections are mainly with catalase-positive microorganisms. Dysregulated inflammation is commonly seen, presenting with autoimmune conditions. The majority of cases are transmitted on the X-chromosome. The management with IFN- γ decreases the number and severity of infections in addition to lifelong antibiotics and antifungal prophylaxis. Despite prophylaxis, infection rates are \sim 0.3/year. Inflammatory syndromes are treated with corticosteroids. Allogeneic hematopoietic stem cell transplantation can reverse both the infectious and inflammatory complications.

The role of case reports in introducing novel concepts in a train the trainer course

Harm Peters, Gunver Kienle, Alta Smit

¹ Charité – Universitätsmedizin Berlin, DE

² Institut für angewandte Erkenntnistheorie und medizinische Methodologie an der Universität Witten/Herdecke, Freiburg, DE

³ Biologische Heilmittel Heel GmbH, Baden-Baden, DE

Introduction

Case reports have gained increasing interest in the last years. However, their dissemination has been concentrated in published journals. Structured case reports tend to be useful for various forms of teaching and offer an opportunity to bring new concepts in medicine into practice.

Methods

Case reports were adapted for “blended learning” as interactive online teaching cases and as learning vignettes in a face-to-face case based learning session, based on adult learning principles. A group of 78 medical doctors from 19 countries were trained in novel medical concepts, such as Systems Medicine and bioregulation.

Online training: the case reports were adjusted to an interactive case format interspersed with exercises, videos and webcasts to expand on the treatment or indication and to introduce the new concepts. After two months to complete the on-demand e-Learning, the participants were required to pass a final test to qualify for the face to face training.

Face to face skills training (2.5 days): the participants received a lecture on the structure, compilation and pitfalls around writing case reports and on the CARE guidelines. This was followed by a lecture on the structure of a case-based learning session, and a role play to demonstrate this. A case report of metabolic syndrome was prepared into learning vignettes and the participants practiced the technique in 5 working groups in four languages.

Results

The level of participation was high in all groups. Already during the training, the relevance and appli-

cability of case-based learning was appreciated on the audience response system. This was confirmed by an additional online survey: Of the 59 responders, 55% of the participants felt very confident to implement the achieved skills, 41% moderately confident and only 4% slightly confident.

Conclusions

Structured case reports have been successfully adapted for use in an interactive online training and as learning vignettes in a case-based learning fashion to introduce novel concepts to a group of trainers. In this way, theoretical concepts of a Systems Medicine approach were clearly brought into practice.

References

Riley, DS, et al. 2017b. CARE guidelines for case reports: Explanation and elaboration document. *Journal of Clinical Epidemiology*, 89: 218–235. DOI: <https://doi.org/10.1016/J.JCLINEPI.2017.04.026>

Quadricuspid aortic valve with aortic insufficiency

Zahir Satti, Abdalla Ibrahim and Peter Kelly
Cork University Hospital, Cork, IE

Introduction

Quadricuspid aortic valve (QAV) is a rare cardiac valvular anomaly with four cusps, instead of the usual three cusps, in the aortic valve. It is an uncommon clinical finding, as its prevalence ranges between 0.013% and 0.043%. Some reports have suggested that this anomaly may occur in up to 1% of individuals who present for aortic valve surgery. QAV is a rare congenital heart defect detected by echocardiography or at the time of aortic valve surgery, aortography or during autopsy.

Case Description

A 60-year-old female with dyspnoea on exertion for a few months and no noteworthy past medical or family history was referred to the cardiology clinic. She was a lifelong non-smoker. On examination, she had a pulse rate of 82 beats per minute with collapsing character and a blood pressure of 110/44 mmHg. She had no raised jugular venous pressure and no pedal oedema. On auscultation, an early diastolic murmur at the aortic area and a soft second heart sound were detected.

Results

The transesophageal echo showed a normal size left ventricle with normal systolic function and QAV with malcoaptation. Severe central aortic incompetence was observed. Effacement of the sinuses with mild mid aorta dilatation of 4 cm was also detected. The mitral valve was structurally and functionally normal with an intact intra atrial septum. The patient then had a preoperative cardiac catheterisation, which showed normal coronary arteries. She was then referred to cardiothoracic surgery and had successful aortic valve replacement with a bioprosthetic valve.

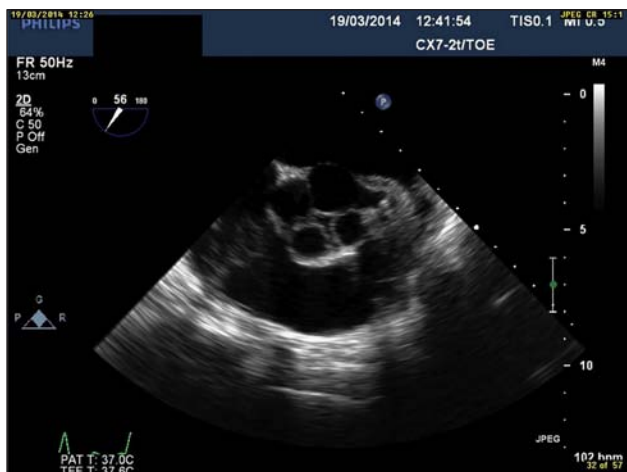


Figure 1: Image of an upper position transesophageal echocardiography view showing a quadricuspid.

Take Home Message/Conclusions

It is important to consider such a rare, but possible, anomaly in individuals presenting with symptoms and signs suggestive of valvular regurgitation. QAV predominantly causes aortic regurgitation. We should regularly follow up patients with QAV, as most patients may require valve replacement with worsening aortic regurgitation in their 5th or 6th decade of life.

Left atrial appendage stenosis – clinically relevant?

Jonas Fischer¹, Tilo Niemann¹ and Cornelia Joha²

¹ Cantonal Hospital, Radiology, Baden, CH

² Cantonal Hospital, Cardiology, Baden, CH

Introduction

The left atrial appendage is a cardiac structure adjacent to the left atrium positioned to the sternocostal surface and in contact to the pulmonary trunk. There is a wide variety of its morphological and anatomical appearance and it has functional and structural properties different to the left atrium. Its clinical relevance often correlates with a diagnosed thrombus in cardiac arrhythmias, especially atrial fibrillation. Nevertheless, there are some more rare pathologies.

Case Description

In our case we describe a 70 year old patient who was electively admitted to hospital to undergo biologic valve replacement due to aortic valve insufficiency. Furthermore, there was a known history of persistent atrial fibrillation. Clinical symptoms were a stable dyspnea NYHA III and increasing fatigue but no signs of angina pectoris or dizziness. A preoperative check-up was performed with an incidental finding of suspected stenosis of the left atrial appendage in the transesophageal echocardiography.

Results

As a marker for present cardiac stress, a blood test showed an increased NT-Pro-BNP. The echocardiography revealed an increased pulmonary arterial pressure and an eccen-

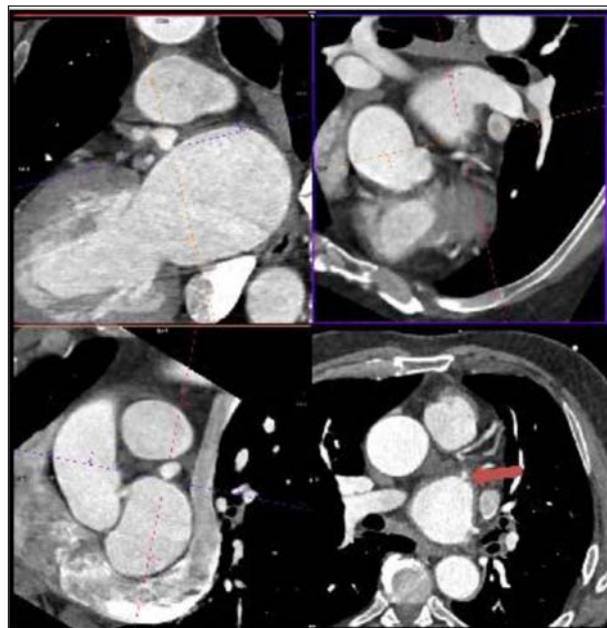


Figure 1: Computed tomography of the heart with the left atrial appendage in three planes.

tric hypertrophy. Besides, at the orifice of the left atrial appendage was as a secondary finding a thin membrane with no visible opening. For further diagnostics cardiac computed tomography was performed, which confirmed and nicely delineated a stenosis of the left atrial appendage.

Take Home Message/Conclusions

Aetiology of stenosis of the left atrial appendage and its clinical relevance for the patient are unclear. It is a rare entity in cardiac imaging and hard to visualize for the unexperienced physician. Cardiac computed tomography can demonstrate cardiac anatomic anomalies in all planes and has become a helpful tool in the workup of suspected cardiac abnormalities. In this case report we demonstrate the features and findings of left atrial appendage stenosis both in ultrasound and computed tomography.

Atypical hemolytic uremic syndrome complicating myeloma treatment

Cristina Chiodi¹, Scott Tetreault² and Dara Wakefield³

¹ Florida State University, Tallahassee, US

² Florida Cancer Specialist, Tallahassee, US

³ University of Florida College of Medicine, Department of Pathology, Immunology and Laboratory Medicine, Gainesville, US

Introduction

Proteasome inhibitors are effective and widely utilized treatments for multiple myeloma. They inhibit the ubiquitin proteasome pathway in a specific and sustained manner, thereby disrupting key cell cycle functions and cell survival. Both drugs have been reported infrequently to result in thrombotic microangiopathy (TMA): thrombotic thrombocytopenic purpura (TTP) and atypical hemolytic uremic syndrome (aHUS). The diagnosis in a myeloma

patient is challenging, and treatment strategies may not address the underlying pathologic process. Here we describe the first reported case of CFZ-associated aHUS, confirmed by kidney biopsy, and successfully treated with eculizumab (Soliris, Alexion Pharmaceuticals).

Case Description

A 71-year old female, with known IgG kappa multiple myeloma, presented to the hospital with a cough, low-grade fever, low platelet count, and right upper lobe infiltrate. The myeloma FISH panel on diagnosis was normal. Prior treatments included cytoxan, bortezomib, dexamethasone (CyBorD), and bortezomib maintenance. She started CFZ five months prior to hospital admission on standard dose and schedule, resulting in biochemical remission. The working diagnosis included mild anemia, thrombocytopenia, and renal failure. Daily plasma exchange resulted in no improvement in hematologic parameters. ADAMTS13 was drawn on hospital day one, and reported on day seven at greater than 50%.

nia, and renal failure. Daily plasma exchange resulted in no improvement in hematologic parameters. ADAMTS13 was drawn on hospital day one, and reported on day seven at greater than 50%.

Results

After reported ADAMTS13 value on hospital day 7, the plasma exchange was stopped, and eculizumab was administered. Eculizumab resulted in improvement in hematologic parameters within 48 hours. By day 28, she was no longer requiring dialysis and hematologic parameters were normal (**Figure 1**). She remains on eculizumab on an outpatient basis and feels well. Kidney biopsy was obtained and showed findings comparable with thrombotic microangiopathy along with hypertensive nephropathy. (**Figures 2–4**).

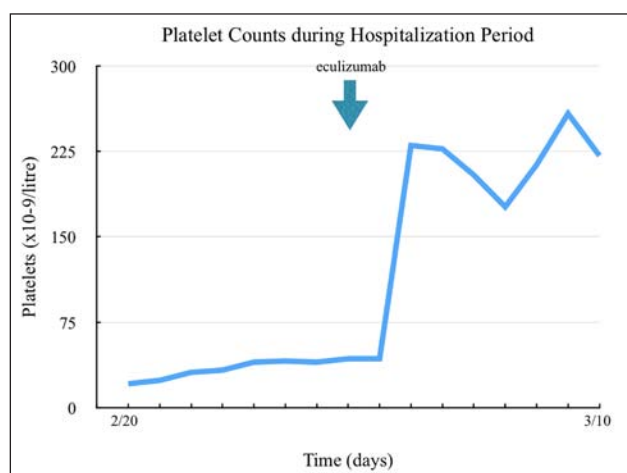


Figure 1: Platelet counts before and after administration of eculizumab during hospitalization period.

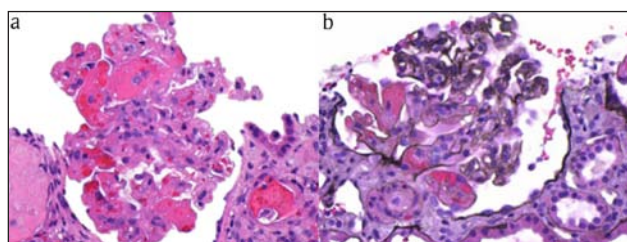


Figure 2: Some of the glomeruli showed marked congestion with crenated RB4Cs, focal fibrinoid necrosis, and resultant FSGS – these changes were most common at the hilar poles; **(a)** Haematoxylin and Eosin (H&E) stain at 40x magnification. **(b)** Silver stain at 40x magnification.

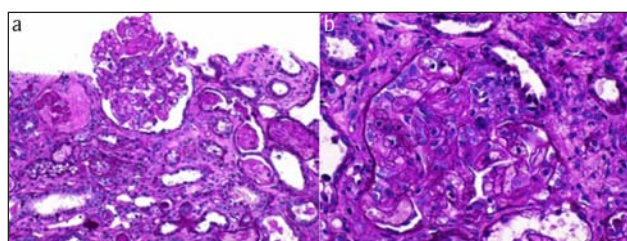


Figure 3: The FSGS and damaged GBM were also highlighted on the Periodic acid–Schiff (PAS) stain. **(a)** 20x magnification and **(b)** 40x magnification.

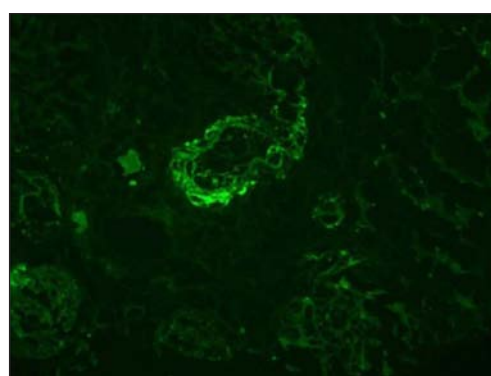


Figure 4: C3 DIF (Direct Immunofluorescence) was positive in the arterioles and portions of glomeruli with TMA changes.

Table 1: Hematologic parameters recorded over the patient's hospitalization.

Date	LDH (U/L)	Platelets ($\times 10^9$ /litre)
2/20	4300	21
2/21		24
2/22		31
2/23		33
2/24	3897	40
2/25		41
2/26	4300	40
2/27		43
2/28		42
3/1		230
3/2	2717	227
3/3		204
3/4		176
3/5		213
3/8		258
3/10		221

Take Home Message/Conclusions

This case highlights the challenges of accurate diagnosis and effective treatment for a rare complication of proteasome-inhibitor treatment of multiple myeloma. Presentation may not immediately suggest TTP or aHUS. The experienced clinician would list infectious and myeloma complications as the etiology of her presenting disease process. Later, when more common diagnoses fail to explain the full picture, the TMA family of diseases is entertained. The first appropriate intervention is plasma exchange, but ADAMTS13 must be assessed before initiating the plasma exchange. In this case, eculizumab was administered when ADAMTS13 was known to be incompatible with a diagnosis other than aHUS.

An unusual case of transpelvic impalement injury

Mushreq Ayesh Alani, Saeed Mahmood, Ayman El-Menyar, Sajid Atique, Hassan Al-Thani and Ruben Peralta Hamad General Hospital, Doha, QA

Introduction

Impalement injury is a rare type of mechanical injury following forceful insertion of a projecting object into the body. This injury is typically accidental but in some cases it is homicidal. The management of impalement injury poses a major challenge. It is widely agreed that the impaling object should be left in situ until the initiation of management at a tertiary trauma center. Careful planning for removal of the impaling object is crucial to minimize blood loss and preserve the involved organ function. However, time is important when evaluating and resuscitating such patients. Herein, we present a case of transpelvic impalement injury.

Case Description

A 27 year-old male fell from 4 meters height over a U-shaped metallic bar with the ends facing upwards. The bar penetrated the left side of the pelvis and traversed through the left iliac bone causing a comminuted fracture in the supra-acetabular region extending to the left psoas muscle, injuring the viscera and causing fracture of the right femur.

Results

After a computerized tomography (CT) scan of the abdomen and pelvis, an exploratory laparotomy was performed and the metallic bar was pulled out from the sigmoid colon through the inlet of the injury. Intramedullary nailing was performed for femur fracture. The patient developed infection (methicillin-sensitive staphylococcus aureus and escherichia coli) during the post-operative course, which was successfully managed with antibiotic therapy. Finally the patient was sent home after a week in a good health condition.

Take Home Message/Conclusions

Impalement injury is a serious and complicated injury which needs a multidisciplinary team with a coordinated

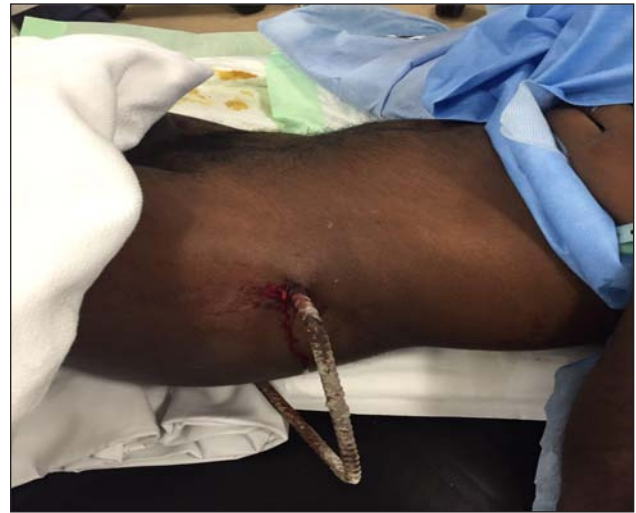

Figure 1: The impaling U shape metallic bar penetrated the left side of the pelvis.

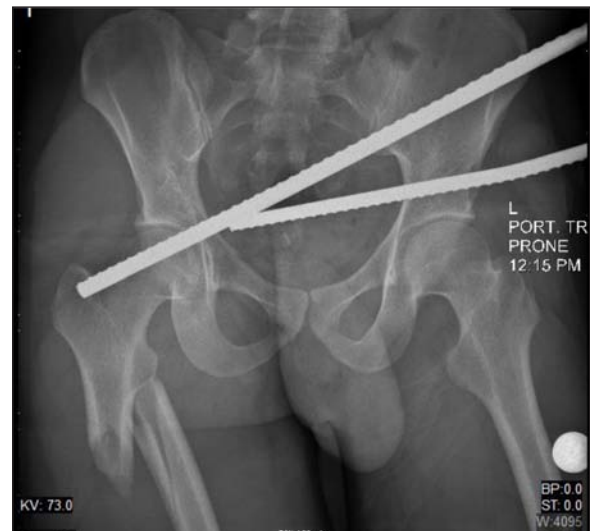


Figure 2: Anteroposterior view X-ray in the Trauma Resuscitation unit showing the U shape metallic bar with the right femur fracture.

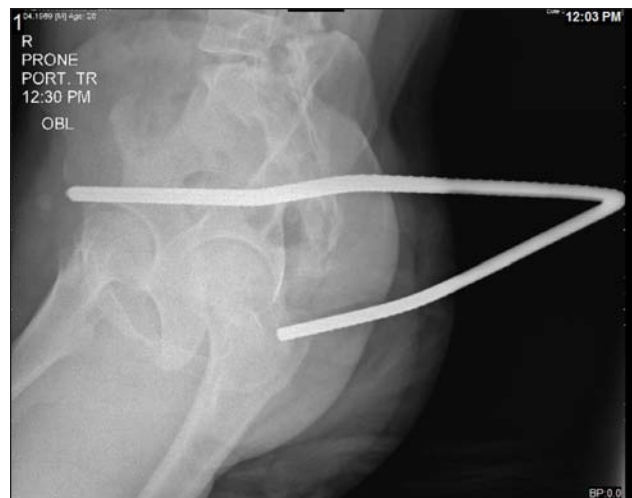

Figure 3: Lateral view X-ray in the Trauma resuscitation unit showing the relation of the metallic bar to the pelvic cavity.

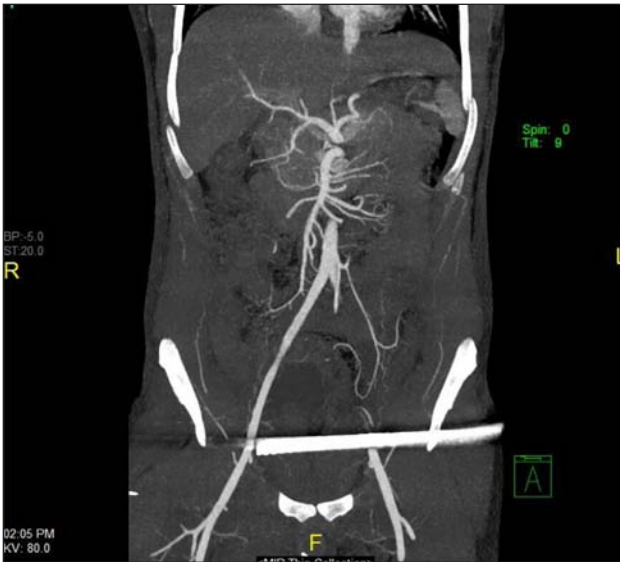

Figure 4: The computerized tomography (CT) scan of abdomen and pelvis demonstrating the anatomy and the injuries related to the impalement.

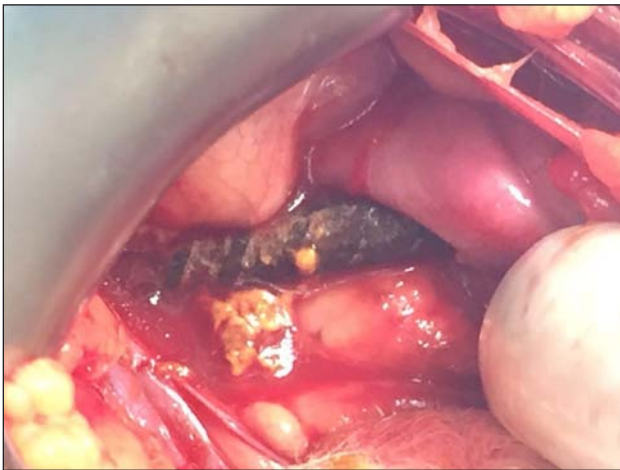

Figure 5: The impaling metallic bar passing through the sigmoid colon.

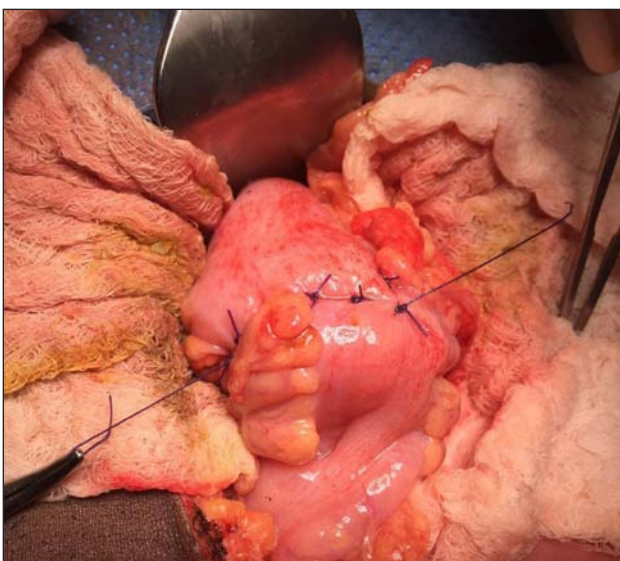


Figure 6: Suturing of the perforation sites in the sigmoid colon.

approach and early imaging studies to facilitate the appropriate management and to achieve a favorable outcome.

Gemcitabine-induced radiation recall myositis

Matthew Alcasid, Erica Lin, Luke Law and Paul Daniels
Mayo Clinic, Rochester, US

Introduction

Radiation recall, a well-studied but poorly understood phenomenon, refers to an acute inflammatory reaction in previously irradiated tissue that develops after exposure to an inciting agent. Various medications have been implicated, including chemotherapeutic agents such as gemcitabine.

Case Description


An 80-year-old female with metastatic urothelial cancer status-post radiation and on chemotherapy with gemcitabine presented with an intractable left pelvic and hip pain. On physical exam, there was LLQ and left pelvic tenderness with proximal weakness of the LLE. Laboratories were notable for CRP 95.4, ESR 62 and CK 247. A CT of the abdomen and pelvis showed signs of possible necrotizing fasciitis of the pelvic muscles. First, broad spectrum antibiotics were initiated, but given an LRINEC score of 2, it was felt this was unlikely infectious. She was initiated on empiric steroids; further gemcitabine was withheld. The symptoms significantly improved.

Results

Radiation recall is a well-studied but poorly understood phenomenon with most of its literature presented in case reports. The pathophysiology is still unknown. It is characterized by its unpredictable nature and can occur hours to days after exposure to the inciting agent and within days to years after the radiation itself. The diagnosis here was determined by clinical presentation and radiologic imaging. The differential includes infectious etiologies such as necrotizing fasciitis or pyomyositis, non-infectious myositis such as polymyositis, radiation reactions such as radiosensitization and diabetic myonecrosis. The management includes withdrawal of the inciting agent and corticosteroids are often administered to suppress inflammation.

Take Home Message/Conclusions

With the increasing use of certain chemotherapy agents, providers who routinely care for patients with malignancies should be familiar with uncommon complications including gemcitabine-induced radiation recall. Additionally, this case highlights that even in the setting of an immunocompromised host, it is important to keep drug reactions in the differential for inflammation in what would otherwise be assumed to be an infectious process. Awareness of the features of this condition will facilitate early diagnosis and appropriate management, as the management is drastically different from other leading diagnoses.



MAYO CLINIC

Gemcitabine-induced Radiation Recall Myositis

Matthew Alcasid, M.D., Erica Lin, M.D., Luke Law, M.D., Paul Daniels, M.D.
Department of Internal Medicine
Mayo Clinic, Rochester, MN

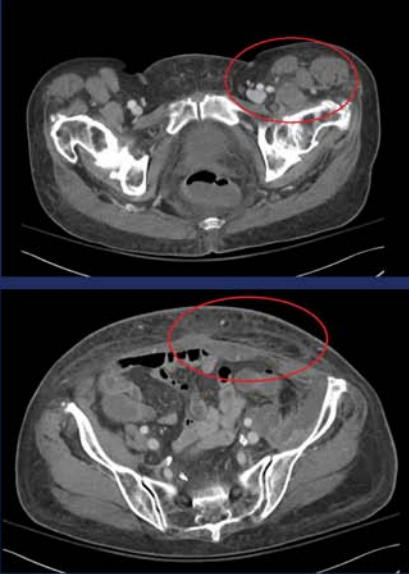
Learning Objectives	Images	Discussion
<ul style="list-style-type: none"> •Recognize radiation recall as a potential drug reaction. •Recognize myositis as a manifestation of possible radiation recall. •Learn to distinguish between potential infection vs. radiation recall. •Describe management strategies. 	 <p style="font-size: x-small; margin-top: 5px;">*Hypoenhancement of the left rectus abdominis, psoas, iliacus, iliopsoas, and sartorius muscles consistent with myositis and/or myonecrosis. Diffuse subcutaneous inflammatory changes.</p>	<ul style="list-style-type: none"> •Radiation recall is a well-studied but poorly understood phenomenon with most of its literature presented in case reports. The pathophysiology is still unknown. •Radiation recall is characterized by its unpredictable nature. It can occur hours to days after exposure to inciting agent and within days to years after the radiation itself. •The diagnosis of radiation recall myositis was determined by clinical presentation and radiologic imaging. Differential includes infectious etiologies such as necrotizing fasciitis or pyomyositis; non-infectious myositis such as polymyositis; radiation reactions such as radiosensitization; diabetic myonecrosis. •Management includes withdrawal of the inciting agent and close observation. Nonsteroidal anti-inflammatory drugs and corticosteroids are often administered to suppress inflammation
<p style="text-align: center; font-weight: bold; font-size: small; margin: 0;">Case Presentation</p> <ul style="list-style-type: none"> • An 80 year-old female with metastatic urothelial cancer status-post radiation and on current chemotherapy with gemcitabine presented with intractable left pelvic and hip pain with weakness. •On physical exam, abdomen was tender in the left lower quadrant without peritoneal signs, there was tenderness in the left inguinal area and she had proximal weakness of the left lower extremity. •Laboratory studies were notable for elevated CRP 95.4, ESR 62 and CK 247 in addition to mild leukocytosis. •A CT of the abdomen and pelvis showed signs of possible necrotizing fasciitis of the pelvic muscles concerning for possible necrotizing fasciitis. Initially initiated on broad spectrum antibiotics, but given LRINEC score of 2, it was felt this was unlikely infectious. •She was initiated on empiric IV steroids with eventual transition to oral prednisone; further gemcitabine was withheld. Symptoms significantly improved. 		<p style="text-align: center; font-weight: bold; margin: 0;">Take Home Points</p> <ul style="list-style-type: none"> • Providers who routinely care for patients with malignancies should be familiar with uncommon complications including gemcitabine-induced radiation recall. • Even in the setting of an immunocompromised host, it is important to keep drug reactions in the differential for inflammation in what would otherwise be assumed to be an infectious process.
		<p style="text-align: center; font-weight: bold; margin: 0;">References</p> <ol style="list-style-type: none"> 1. Bhasin J, Dutta S, Sharma S, Choudhury KB. Gemcitabine-induced radiation recall phenomenon in a postoperative and post-radiotherapy case of penile squamous carcinoma during adjuvant chemotherapy. <i>J Cancer Res Ther</i> 2012; 8(3):439-441. 2. Fricoliander PA, Bansal R, Schwartz L, Wagman R, Pomeroy J, Katsenoy N. Gemcitabine-related radiation recall preferentially involves internal tissue and organs. <i>Cancer</i> 2004; 103(9):1793-1799.

Figure 1.

Acquired angioedema of the glottis, larynx and neck in a patient affected by SLE

Stefano Scollo¹, Giuseppina La Camera¹, Sergio Neri², Chiara Grasso¹, Rosetta Cubisino¹ and Marinella Astuto¹

¹ Department of Anesthesia and Intensive Care, University Hospital 'Policlinico – Vittorio Emanuele', Catania, IT

² Department of Internal Medicine, University Hospital 'Policlinico Vittorio Emanuele', Catania, IT

Introduction

SLE is an autoimmune disease of unknown etiology, characterized by a variable course and prognosis with clinical and laboratory manifestation which can involve any organ system (Wallace and Metzger, 1997). Angioedema, secondary to C1-inhibitor deficiency, has rarely been reported to be associated with SLE (Koide et al., 2002).

Case Description

We describe a 27-year-old woman affected by SLE admitted to our ICU because of a remarkable swelling of the right parotid and submandibular region, extending progressively towards the basal region of the neck with worsening dysphagia and dyspnea, so she required intubation through fiber optic guided laryngoscopy, sedation and mechanical ventilation. Steroids and antibiotic therapies were started. An urgent TC-scan (**Figure 1**) revealed prevalent edema in the right region of the neck involving the soft tissues, tongue and jugulodigastric nodules,

with oropharyngeal and ipopharyngeal mucosal edema up to contralateral subcutaneous tissues. Under suspicion of acquired angioedema secondary to SLE, 1500 UI of C1-INH was administered. A control TC-scan revealed the reduction of edema but at the same time the presence of multiple lung parenchymal spots, so she remained on steroids and antibiotics. When the airway obstruction was resolved; she was extubated, dismissed from the ICU and moved to the internal medicine unit where she remained on steroids and antibiotics until the complete resolution of the clinical pattern.

Results

In few cases of patients with SLE, acquired angioedema caused upper airway obstruction requiring orotracheal intubation and admission in ICU (Markovic et al., 2000). Acquired angioedema with C1 inhibitor deficiency can be caused by autoantibodies neutralizing C1-INH activity and generally a swelling of the face, limbs, tongue, pharynx and larynx when an episode occurs – even if cutaneous and mucosal tissues in any part of the body may be involved (Cicardi and Zanichelli, 2010). In our case, acute clinical symptoms, upper airway involvement and SLE in the patient's medical history steered the diagnosis towards an acquired angioedema.

Take Home Message/Conclusions

Life-threatening airway involvement requiring orotracheal intubation in patients affected by SLE is rare but

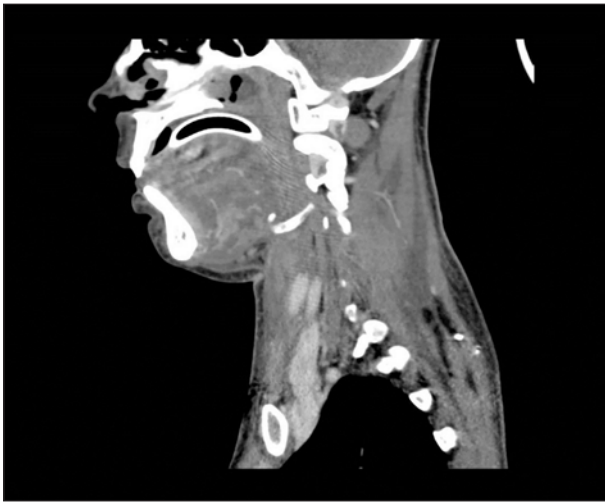


Figure 1: A CT scan of head and neck showing soft tissue swelling and airway obstruction.

potentially fatal. An acquired angioedema is a possible cause in this kind of patients. Early airway management and therapeutic treatment are essential for a positive resolution of the disease.

References

- Cicardi, M** and **Zanichelli, A.** 2010. The acquired deficiency of C1-inhibitor: Lymphoproliferation and angioedema. *Curr Mol Med*, 10: 354–360. DOI: <https://doi.org/10.2174/156652410791317066>
- Koide, M, Shirahama, S, Tokura, Y, Takigawa, M, Hayakawa, M** and **Furakawa, F.** 2002. Lupus erythematosus associated with C1 inhibitor deficiency. *J Dermatol*, 29(8): 503–507. DOI: <https://doi.org/10.1111/j.1346-8138.2002.tb00316.x>
- Markovic, SN, Inwards, DJ, Frigas, EA** and **Phyliky, RP.** 2000. Acquired C1 esterase inhibitor deficiency. *Ann Intern Med*, 132: 144–150. PubMed PMID: 10644276. DOI: <https://doi.org/10.7326/0003-4819-133-10-200011210-00025>
- Wallace, DJ** and **Metzger, AL.** 1997. Systemic lupus erythematosus: Clinical aspects and treatment. In: Koopman, WJ (ed.), *Arthritis and Allied Conditions*, 1319–1345. Baltimore, MD: Williams & Wilkins.

Incidental finding of an undiagnosed coarctation of the aorta causing dilated cardiomyopathy in an adult

Abdalla Ibrahim, Zahir Satti and Ronan Curtin
Cork University Hospital, Cork, IE

Introduction

Aortic coarctation is observed in about 6–8% of all congenital heart defects either as an isolated anomaly or associated with other defects. A greater proportion of aortic coarctation cases are identified either in childhood due to the development of congestive cardiac failure or during adulthood due to treatment-refractory hypertension. In this report, we demonstrate a case of aortic coarctation

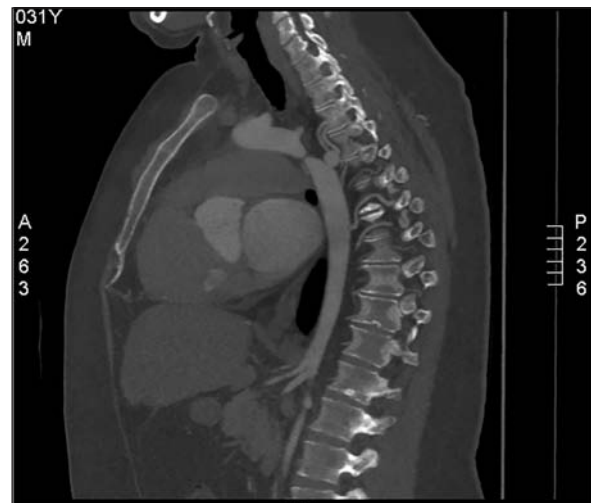


Figure 1: CT of the left upper limb showing coarctation of the aorta at the isthmus.

that remained undiagnosed until the development of congestive heart failure in adulthood.

Case Description

A 31-year-old male without medical history apart from high blood pressure noted one week before admission. He presented with symptoms of heart failure with severe global left ventricular dilation and dysfunction on transthoracic echocardiography (TTE). Two weeks following the admission he complained of left arm pain, and a CT of the upper limb confirmed the embolic occlusion of the left brachial artery and the incidental severe coarctation of the proximal descending aorta after the beginning of the left subclavian artery (**Figure 1**). His heart failure and blood pressure responded well to the treatment, and he has been referred for surgical correction of his aortic coarctation.

Results

Initial investigations included an electrocardiography (ECG) which showed sinus tachycardia with a left ventricular hypertrophy. High sensitivity troponin-T was elevated at 55 ng/L (upper limit 14 ng/L), no rise on serial testing. A chest X-ray revealed marked cardiomegaly and pulmonary congestion, but there was no rib notching. TTE confirmed a severely dilated left ventricle (left ventricular internal dimension-diastole of 6.9 cm) with severe global systolic dysfunction. The CT of the left upper limb confirmed an embolic occlusion of the left brachial artery at the level of the distal third of the humerus and the incidental coarctation of the aorta at the isthmus.

Take Home Message/Conclusions

A coarctation of the aorta should always be considered in young hypertensive adults. Patients with de novo acute heart failure should have careful evaluation to cover all possible underlying etiologies including hypertensive cardiomyopathy secondary to coarctation of the aorta. All the standard TTE views should be performed to ensure that pathology is not missed, thus enabling the comparison with previous examinations.

An unusual presentation of systemic lupus erythematosus as Evan syndrome: A Case Report and a literature review

Ali Al Bshabshe¹, Ali Assiri², Hamdan Al-Shehri² and Abdulmoneim Jamil³

¹ King Khalid University, Abha, SA

² Najran University, Najran, SA

³ King Khalid University, Abha, SA

Introduction

Evan syndrome, is an autoimmune disorder characterized by the simultaneous or sequent development of autoimmune hemolytic anemia and immune thrombocytopenia, sometimes accompanied by immune neutropenia in the absence of any underlying cause. ES is considered an idiopathic condition and is mainly diagnosed based on exclusion of other diseases, ES may be associated with or diagnosed along with conditions such as systemic lupus erythematosus (SLE), lymphoproliferative disorders, or primary immunodeficiency. Whereas ES relies on antibody-mediated AIHA and ITP, the combination of AIHA and ITP can also be observed in patients with SLE, suggesting a link to other inflammatory mechanisms.

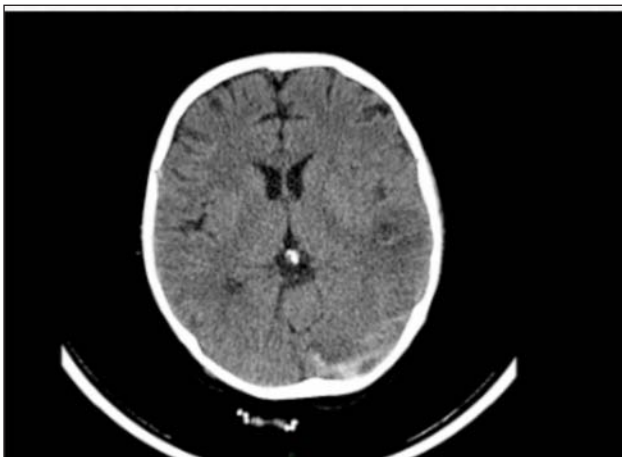

Figure 1: Picture of the left transverse sinus thrombosis associated with left temporal lobe venous haemorrhagic infarction.

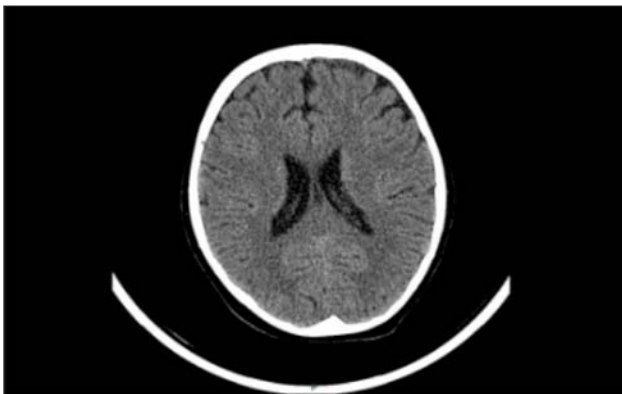


Figure 2: Picture of the left transverse sinus thrombosis resolution after 10 days of treatment.

Case Description

A 32-year-old woman, having been treated for EVAN syndrome for the past 5 years, was admitted to our hospital with severe headache and blurred vision. She had a remote history of malar rash and polyarthralgia. These symptoms progressively deteriorated, prompting her hospital visit. A physical examination indicated that she was vitally stable and afebrile but mildly confused. She was dehydrated with pallor, mild jaundice, and a bilateral extensor plantar reflex but was able to move all four limbs and had bilaterally reactive pupils. Her fundus examination showed papilledema. A small purpuric rash was scattered over her arms and legs. Other physical examinations were normal.

Results

A brainCT with contrast showed a hydrocephalus with a cerebral venous thrombosis (**Figure 1**). Laboratory investigations revealed a moderate bicytopenia bone marrow aspiration, a revealed active marrow with erythroid hyperplasia and a mild increase in megakaryocytes while all other bone marrow series were normal. Immunological investigations showed a positive antinuclear antibody together with positivity for anti-dsDNA and anticardiolipin antibodies. According to the collective clinical and laboratory findings, the patient fulfilled the criteria for SLE she was treated steroid and azathioprine and hydroxychloroquine together with therapeutic anticoagulation. A follow up CT scan of her brain showed a resolution of the transverse sinus clot (**Figure 2**).

Take Home Message/Conclusions

In cases of Evan syndrome among adults, investigations for any associated conditions, with special consideration of SLE, LPD, and autoimmune disorders are needed. The diagnosis of associated conditions will help to improve management plans and to make a more favorable prognosis. However, further research is needed to help clarify the pathophysiology and obtain better therapeutic strategies for Evan syndrome associated with or complicated by SLE in adults.

Staphylococcus aureus endocarditis complicated by pulmonary septic emboli, thyroiditis with thyrotoxicosis and septic arthritis

Hongfei Fang and Daniel DeSimone
Mayo Clinic, Rochester, US

Introduction

Staphylococcus aureus accounts for approximately 20% of blood stream infections in the United States, with the majority being health care associated. The presence of bacteremia is associated with complications including endocarditis, septic arthritis, complicated pneumonia, and toxic shock syndrome, with mortality rates 20–40%. In community acquired *S. aureus* bacteremia, intravenous drug users are a high risk group. We present a case of a patient who presented with cavitary pulmonary lesions and subsequently developed tricuspid endocarditis, thyroiditis with thyrotoxicosis, and septic arthritis.

Case Description

A 23-year-old woman was admitted to the intensive care unit for sepsis in the setting of recent intravenous methamphetamine use. On assessment she was tachycardic, hypotensive, febrile, and tachypneic. Labs were significant for leukocytosis, undetectable TSH, and elevated T4. Blood cultures grew Methicillin Resistant Staphylococcus Aureus (MRSA). A CT of the chest revealed cavitory pulmonary nodules and ultrasound imaging revealed a right thyroid lobe inflammation. Her initial transesophageal echocardiogram (TEE) was negative, however a repeat TEE one week later revealed 1.5 × 0.8 cm vegetation on the tricuspid valve. An aspiration of her right hip and left calf grew MRSA.

Results

She was initiated on vancomycin under the guidance of the infectious disease service for a 6 week course. Blood cultures were persistently positive until day 9 of antibiotics. She underwent irrigation and debridement of the right hip due to concerns of septic arthritis. Serial aspirations were performed on the fluid collection in the calf to provide drainage. A thoracic drain was placed in the left lingula to treat her pulmonary abscess. Her hospital course was complicated by septic shock, which she slowly recovered from and she was able to be discharged after three weeks of hospitalization.

Take Home Message/Conclusions

S. aureus bacteremia is associated with multiple complications and a high risk of mortality. This case is unique in that the patient experienced multiple complications including thyroiditis, septic arthritis, cavitory pneumonia, and tricuspid valve endocarditis. This case also highlights the delay in valvular vegetations seen during the initial transesophageal echocardiography in early stages of endocarditis. Having a high clinical suspicion is important in identifying and intervening on any possible complications associated with this condition.

Massive postpartum pulmonary embolism successfully treated with VA-ECMO

Greta Balčiūnienė^{1,2}, Lukas Balčiūnas^{1,3}, Lina Morozovaitė¹, Diana Ramašauskaitė^{1,2}, Mindaugas Šerpytis^{1,3} and Lina Gumbienė⁴

¹ Vilnius University, Faculty of Medicine, Vilnius, LT

² Vilnius University Hospital Santaros Klinikos, Centre of Obstetrics and Gynecology, Vilnius, LT

³ Vilnius University Hospital Santaros Klinikos, Centre of Anesthesiology, Intensive Therapy and Pain Management, Vilnius, LT

⁴ Vilnius University Hospital Santaros Klinikos, Centre of Cardiology and Angiology, Vilnius, LT

Introduction

Pulmonary embolism is a life-threatening condition, which occurs in 1 of 3000 pregnancies. In developed countries all thromboembolic events comprise 14.9% of

all maternal deaths. In most cases pulmonary embolism during pregnancy and post-partum is treated with thrombolysis along or without embolectomy. However, some authors consider pregnancy as relative contraindication for thrombolysis, because it can lead to massive maternal bleeding. Extracorporeal membrane oxygenation with anticoagulation therapy is also mentioned as possible method for the treatment of pulmonary embolism. However, in the absence of clinical recommendations, it remains unclear how to deal with these severe cases in order to achieve best maternal outcomes.

Case Description

A 28-year-old female patient presented with general weakness, shortness of breath, hypotension (78/50 mmHg), tachycardia (116 beats/min) two hours after cesarean section. The echocardiography and a computed tomography showed signs of massive pulmonary embolism. The status was deteriorating and cardiorespiratory failure developed (PaO₂ 34 mmHg, respiratory rate 35 times/min, SaO₂ 60%). Extracorporeal membrane oxygenation (ECMO) was preferred for treatment rather than thrombolysis due to the bleeding risk. A veno-arterial-venous ECMO was established with additional venous cannula into internal jugular vein to prevent secondary brain hypoxia. The patient was cooled to a 35°C core temperature for 24 hours after 5 cycles of cardiopulmonary resuscitation.

Results

The heart contraction was inspected everyday, some pericardial fluid was observed. The cannulation could cause the accumulation of pericardial fluid along with heparin infusions, which maintained slow bleeding. On the 8th day cardiac tamponade with heart compression developed, 1200 ml of arterial blood was drained. On the 10th day the arterial cannula was removed following one day with veno-venous ECMO system. The next day the patient had failed extubation because of insufficient breathing, low muscle tone and increased salivation. Also, a sensorimotor aphasia was recognized. According to signs in the computed tomography, a diagnosis of posterior reversible encephalopathy syndrome was considered. The patient became fully cooperative on the 40th day.

Take Home Message/Conclusions

Our presented case demonstrates that extracorporeal membrane oxygenation without thrombolysis is a conceivable treatment method for pulmonary embolism especially in the post-partum period. This treatment could prevent massive bleeding. Although our case had a sufficient outcome, it is necessary to perform further studies in order to prove its superiority against other treatment methods.

Acute disseminated encephalomyelitis linked to rotavirus infection – novel insight from a prospective surveillance program

Patrick Obermeier^{1,2,3}, Eric Delwart⁴ and Barbara Rath^{1,2,3,5}

¹ Vienna Vaccine Safety Initiative, Berlin, DE

² UMC Chrono-Environnement, Université de Bourgogne Franche-Comté, Besançon, FR

³ Charité University Medical Center, Berlin, DE

⁴ Blood Systems Research Institute, San Francisco, US

⁵ University of Nottingham, Nottingham, UK

Introduction

Acute disseminated encephalomyelitis (ADEM) is an immune-mediated, demyelinating disease of the central nervous system (CNS) accounting for a considerable disease burden in infants and children. In most instances, a virus infection will precede neurological symptoms and thus it has been difficult to identify viral triggers. Currently, we may know only a small fraction of viral pathogens that may be associated with para-/postinfectious ADEM. To explore potential links between viral infections and ADEM or other neuroinflammatory conditions, we established a prospective syndromic surveillance program at the Charité Department of Pediatrics, assessing all patients hospitalized with signs and symptoms of CNS infection/inflammation.

Case Description

A mobile application (The VACC-Tool™) was used to ascertain clinical presentations at the point-of-care and to classify cases according to pre-defined clinical case definitions. Between November 2010 and December 2013, a total of 100 stool samples were collected from pediatric patients with confirmed encephalitis and/or ADEM (mean age 11 years, range 0.15–17.85 years, 49% male). The samples were tested using a viral metagenomics sequencing approach. Of 71 cases of ADEM, one was shown to be linked to rotavirus infection.

Results

The patient was a 2-year-old female who had experienced an afebrile convulsive seizure requiring hospitalization. No diarrhea was reported. Upon clinical examination, the patient suffered from ataxia. A maximum body temperature of 38.8°C was measured on hospital day 7. On hospital day 9, the patient had fully recovered and could be discharged to home. Laboratory analysis of the cerebrospinal fluid (CSF) revealed cytoalbuminologic dissociation. CSF bacterial cultures, gram stain, and CSF testing for *Mycoplasma pneumoniae*, *Borrelia*, herpes-, and enteroviruses were negative. A stool sample tested positive for rotavirus by viral metagenomics and confirmatory real-time RT-PCR testing of the same sample.

Take Home Message/Conclusions

Based on the patient history, cerebellar dysfunction, and paraclinical findings, ADEM case criteria were met. To our knowledge, this is the first report of confirmed ADEM associated with a rotavirus infection. A standardized case ascertainment and unbiased pathogen detection may facilitate translational research, exploring complex disease presentations and associated pathogens with minimal selection bias. However, large-scale prospective surveillance programs with paired CSF and stool sam-

pling are warranted to further investigate the incidence of ADEM in the context of rotavirus infection.

Extranodal nasal type natural killer (NK)/T cell lymphoma of the palate – the utility of deep tissue biopsy

Stephanie Williams and Christopher Hook
Mayo Clinic, Rochester, US

Introduction

Lymphoma is defined as a malignant disease of the lymphatic system, characterized by abnormal proliferation of lymphocytes. By the World Health Organization (WHO) categorization system, lymphomas are divided into two subtypes- Hodgkin's lymphoma (HL) and non-Hodgkin's lymphoma (NHL). HL occurs mainly in the lymph nodes (>90%). However, it has been cited that anywhere from 25–40% of NHL's arise from extranodal sites. The following is a case involving a type of NHL called extranodal natural killer (NK)/T cell lymphoma. This is an aggressive rare NHL which develops from natural killer or T lymphocytes and is commonly associated with Epstein-Barr virus (EBV).

Case Description

Mr. S is a 58-year-old farmer with a history of hypertension and tobacco use. He presented with a three week history of a large necrotic soft palate ulceration and subsequent odynophagia. The ulcer started approximately one week after being intubated for a rotator cuff tear procedure. 3 months prior to presentation, he noted 40 pounds of unintentional weight loss and issues with chronic sinusitis despite multiple outpatient antibiotic regimens. On presentation, the physical exam was consistent with a 3.5 × 3.5 superficial ulcer with serrated borders and central necrosis. No submandibular adenopathy was noted.

Results

In evaluation of the palate ulcer, he had a local evaluation with ear/nose/throat (ENT), dermatology, gastroenterology (GI), and rheumatology. Laboratory studies including rheumatologic serologies and an infectious workup (EBV) were widely unremarkable. The CT scan of the sinuses showed chronic sinusitis but was otherwise normal. Two biopsies of the ulcer, performed on separate occasions, were non-diagnostic. Given a unifying diagnosis could not be established, Mr. S was ultimately admitted to the hospital for deep tissue biopsy under anesthesia. This third biopsy revealed a focal atypical lymphoid infiltrate consistent with an extranodal NK/T cell lymphoma.

Take Home Message/Conclusions

Palate ulcers can be due to numerous etiologies. From benign processes like necrotizing sialometaplasia, to autoimmune diseases like inflammatory bowel disease or Behcet's, vasculitic processes like granulomatosis with polyangiitis, infections like histoplasmosis, to malignant conditions like nasopharyngeal lymphoma. This case specifically highlights the need for deep tissue biopsy in

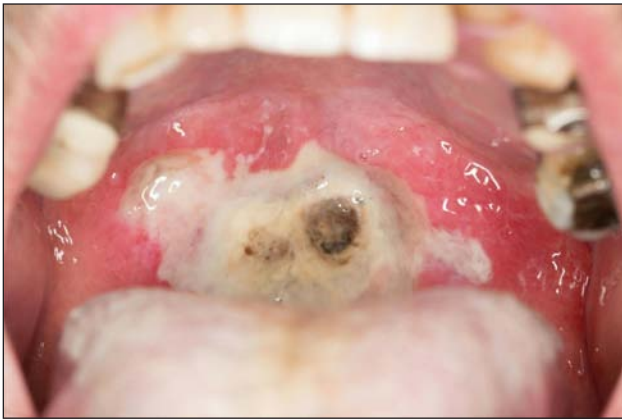

Figure 1.

the setting of an NK/T cell lymphoma as initial superficial biopsies can be normal. The management of NK lymphoma focuses on combined locoregional radiotherapy with chemotherapy. Autologous hematopoietic stem cell transplantation has been shown to offer a survival benefit in patients who have reached complete remission after consolidative chemotherapy.

Axillary artery dissection and secondary thrombosis after closed proximal humerus fracture – a rare interdisciplinary challenge

Sam Razaean¹, Saad Rustum¹, Dafang Zhang², Christian Krettek¹, Rupert Meller¹ and Nael Hawi¹

¹ Hannover Medical School, Hannover, DE

² Massachusetts General Hospital, Boston, US

Introduction

Proximal humerus fractures account for 4–6% of all fractures and are a common result of low-energy trauma in the elderly. Concomitant neurovascular injury of the neighboring axillary artery and brachial plexus is a rarity, but has enormous impact on therapy, rehabilitation and prognosis. The diagnosis of an axillary artery injury may be delayed due to its varied clinical presentation and may lead to prolonged ischemia, distal necrosis and even the loss of the limb. A thorough clinical examination, high suspicion and identification of known predictors can be helpful in early diagnosis of this rare injury.

Case Description

An intoxicated 76-year-old male sustained a dislocated proximal humerus fracture, resulting in concomitant brachial plexopathy and axillary artery dissection with secondary thrombosis after a low-energy fall from standing height. Due to mistriage as a neurological emergency the somnolent patient presented under delayed circumstances at our traumatological emergency department, demonstrating pain, paleness, paralysis, paresthesia and non-palpable wrist pulses. A diagnosis was made through high suspicion after clinical examination with the aid of CT angiography. Emergent open reduction and anatomic shoulder hemiarthroplasty was performed followed by axillobrachial interposition grafting, using a reversed saphenous vein graft and brachial plexus exploration.

Results

The surgical treatments were uncomplicated. The affected limb remains viable at 6-weeks follow-up; however, active shoulder function is limited due to residual brachial plexopathy.

Take Home Message/Conclusions

Despite early diagnosis and management of this rare injury, the prognosis for functional recovery is guarded and largely dictated by the extent of the neurological injury in the setting of concomitant brachial plexopathy. Brachial plexopathy is highly associated with axillary artery injury and its impact is often underestimated in comparison due to its non-limb-threatening nature in the acute setting. Future studies should focus on the long-term prognosis for functional recovery in patients with this rare injury pattern.

Recurrent pneumothorax secondary to Birt-Hogg-Dubé syndrome

Don Codipilly, Cole Laber and Tony Chon
Mayo Clinic, Rochester, US

Introduction

Birt-Hogg-Dubé syndrome is a rare, autosomal dominant disorder involving germline mutations in the folliculin gene (FLCN). Manifestations include benign skin hamartomas, cystic pulmonary lesions, and increased risk of renal cancer. We present the case of a young female with recurrent pneumothorax who was ultimately diagnosed with this syndrome after revealing a strong family history of the disease.

Case Description

A 20-year-old female university student presented with the sudden onset of shortness of breath and chest pain while in class. Apart from an increased respiratory rate and hypoxia requiring oxygen by nasal cannula, vital signs were within normal limits. The physical examination was notable for increased tympany and diminished breath sounds in the left lung field. A chest X-ray revealed a large left sided pneumothorax. Basic laboratories, including a complete blood count and a comprehensive metabolic panel, were unremarkable. A left sided chest tube was placed and the patient was admitted to the medical ward for further monitoring.

Results

Further history was obtained and the patient stated that she had been hospitalized thrice in the last month for multiple episodes of pneumothorax. She mentioned that an aunt carried a diagnosis of Birt-Hogg-Dubé syndrome, but it was unclear if this aunt had recurrent pulmonary issues. FLCN (folliculin) gene testing was obtained and revealed a heterozygous amino acid alteration (c.1285dupC [p.H429Pfs*27]), which is pathogenic for the disease. The patient underwent a renal ultrasound revealing no abnormalities, and a CT chest revealed cystic changes in the left lung fissure (see image). She ultimately

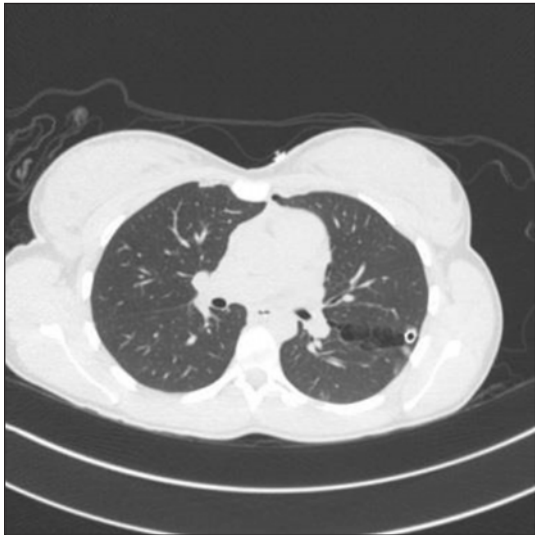


Figure 1: Cystic change along left lung fissure.

underwent mechanical pleurodesis with the aim of preventing a future pneumothorax.

Take Home Message/Conclusions

Birt-Hogg-Dubè syndrome was first described in 1977 in a family with benign fibrofolliculomas of the face. The further study of this rare, autosomal disease noted an increased propensity of pneumothorax due to cystic changes in the lungs, as well as an increased risk of renal cancer. The exact function of the folliculin gene is uncertain, but it is hypothesized to play a role in the mTOR pathway, which may, in part, explain the increased risk of renal cancer. The management of these patients includes active surveillance for renal masses, and possible pleurodesis if prone to recurrent episodes of pneumothorax.

Reemergence of paracoccidioidomycosis in Honduras

Efrain Bu¹, Diana Varela², Sandra Montoya², Alexa Caballero², Daniel Aguilar², Miguel Osejo², Alexis Rivas², Incia Orellana², Alberto Corea², Irma de Vicente², Ricardo Matute² and Erick Silva²

¹ Hospital Escuela Universitario, Tegucigalpa, HN

² Hospital Escuela Universitario, Tegucigalpa, HN

Introduction

Paracoccidioidomycosis is a systemic mycosis caused by fungus *paracoccidioides brasiliensis*. Uncommonly observed among the farmer population in Honduras, a reemergence of reported cases is being seen as migratory agriculture has increased in the last decades.

Case Description

We report four cases diagnosed between 2015 and 2017 in the capital city's university hospital (Hospital Escuela Universitario), the largest reference medical center in the country. The patients in reference were immunocompetent, male gender, ages 36–63 years old working in the rural areas with variable and rare clinical findings including papular, nodular, ulcerative and

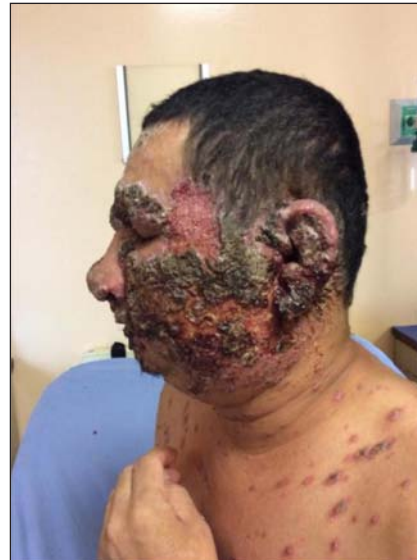

Figure 1: Papular, crust plaques, nodular and ulcerative skin lesions. Patient 1.

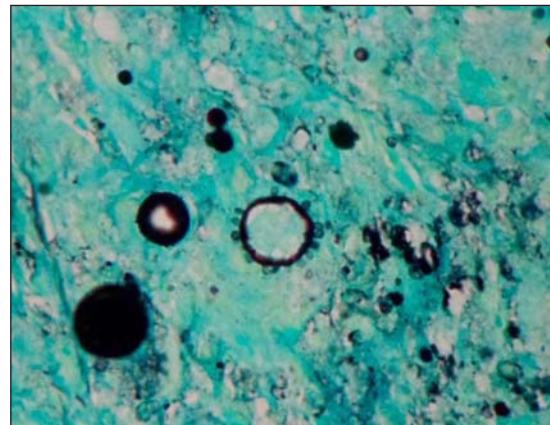


Figure 2: Skin biopsy. Grocott stain 100x. Patient 1.

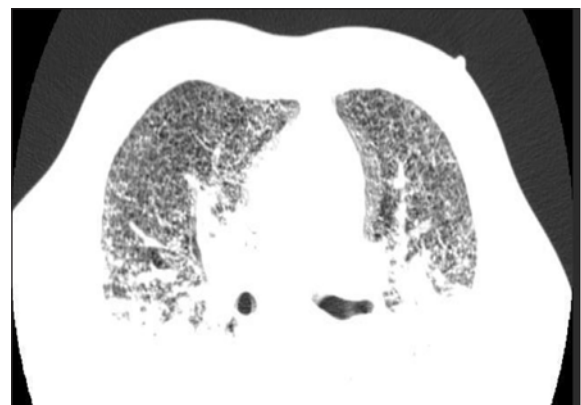


Figure 3: CT of thorax of patient 2.

mucocutaneous lesions with pulmonary manifestations or dysphonia, an isolated and unique symptom. One case presented as a mixed infection with pulmonary histoplasmosis.

Results

The cases were documented with radiological studies and the etiology was confirmed through tissue biopsies and/or the culture of bronchoalveolar lavage. The patients were

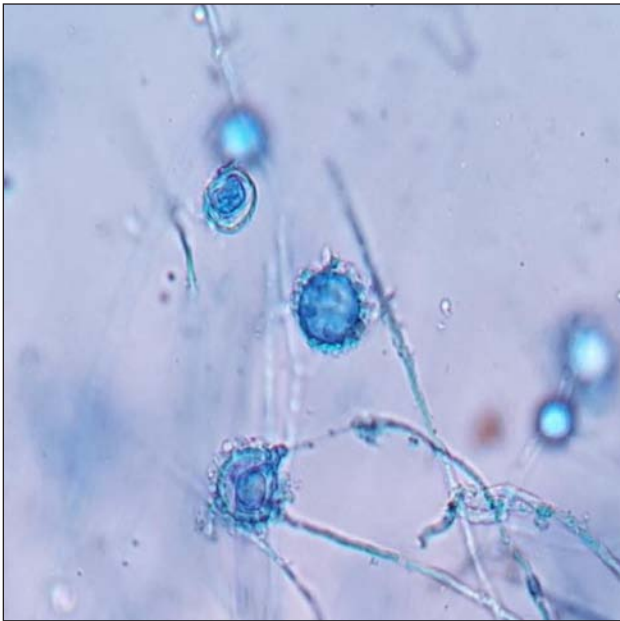

Figure 4: Microphotography of *Histoplasma capsulatum*. Filamentous shape with macroconidias, thin micelio. Blue lactofenol stain. Patient 2.

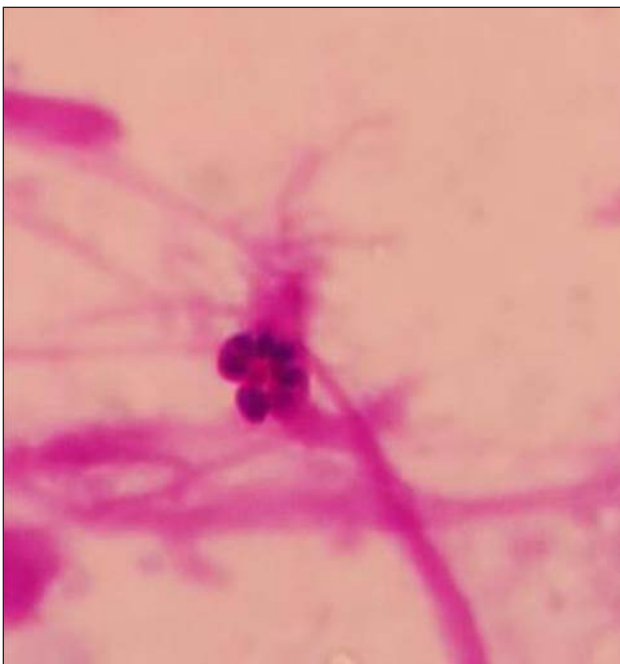


Figure 5: Microphotography of *Paraccoccidioides brasiliensis*, giemsa stain 100x. Yeast, with with pilot wheel appearance. Patient 2.

treated with amphotericin B deoxicolate and/or itraconazole with satisfactory evolution.

Take Home Message/Conclusions

Paraccoccidioidomycosis is a reemergent disease in Honduras. As compared to the general population it seems to be more frequent among farmer workers. The most common clinical manifestations are mucocutaneous lesions and lower respiratory symptoms. Dysphonia is a rare clinical symptom, but in the case of farm workers the infection with *paraccoccidioides brasiliensis* should be suspected.

Hirudotherapy in the treatment of chronic bilateral maxillary sinusitis

Konstantin Sukhov

World Hirudotherapy Organization, Moscow, RU

Introduction

Chronic sinusitis is an inflammation of the paranasal sinuses and its most common variation is chronic maxillary sinusitis. Most treatments of this condition include mechanical clearance and saline irrigation, drug therapy (antibiotics, antihistamines, decongestants, nasal steroids and/or oral steroids) and surgical treatment (removal of thickened mucous membranes, polyps, and sinus drainage). The effectiveness of such treatment is questionable, as the incidences in all countries of the world continue to be high. In my clinical practice we apply the hirudotherapy (medicinal leech therapy), which effectively eliminates the inflammatory process and allows you to avoid surgery. In this report I present the most typical clinical example.

Case Description

Boy, 12 years old. Chronic catarrhal bilateral maxillary sinusitis, acute stage. Enlargement of adenoids 2–3 degree. Deviation of the nasal septum. Sick for 8 years, several times a year. Treated regularly without any results. Recommended surgical treatment. The last exacerbation – within a month, treatment without effect. Objectively: state of moderate severity. Child is inhibited, sluggish (according to the mother). Nasal breathing is absent, nasal for the allocation of scarce, breathing through the mouth, lips all dry. Complaints of congestion and feeling of heaviness in the face and nasopharynx. Submandibular lymph nodes moderately enlarged, soft, moderately painful.

Results

The first session of hirudotherapy (11.12.2013, Pic.01): application of the one leech to under angle of mandible on both sides, until full saturation (right – 45 min; left – 90 min). Bleeding after application – scarce, for 6–7 hours. In the morning (12.12.2013) the patient's state of health became better – more active, began to depart mucous-purulent separated from the nasal cavity. The second session (13.12.2013, Pic.02) is application of the one leech – under angle of mandible and the vestibule of nose on the left side, until full saturation (nasal – 10 min, angle – 40 min). Bleeding: from the nose – small, duration about 60 min, from the jaw's angle – about 6–7 hours. By the evening, the health's state had improved significantly: the discharge from both nasal passages increased; there was a possibility of limited breathing through the left nasal passage. The third session (15.12.2013, Pic.03): one leech – under the angle of mandible and on vestibule of nose on the right side, until full saturation (nasal – 10 min, angle – 30 min). Bleeding: from the nose – small, about 60 minutes; from the angle – abundant until the evening. The health's state by the evening, the condition has improved significantly: the nasal congestion disappeared, the consistency of mucus from the nose became thicker, freely separated from both nasal passages; it became possible

to breathe through the right nasal passage. The next day (16.12.2013) – breathe through the nose freely, periodically there is a feeling of stuffiness in the nasal passages, but not expressed, and quickly. Held two sessions (22 and 29.12.2013) – the child is almost restored.

Take Home Message/Conclusions

In the future, a marked and severe exacerbation of the disease was through a month (26.01.2014). Asked for help, worked with him for a long time – the first two weeks of sessions conducted twice a week, good results after 3–4 sessions. Then over the next months, sessions are held once a week. The last session was on 07.05.2014. After this course of hirudotherapy, the patient received a stable remission until now.

A 56-year-old male with hypercalcemia and osteoporosis

Maaïke Ramael¹, Tony Puls², Hilde Van Steelandt³, Eveline Krznaric³, Toon Maes⁴ and Marc Ramael^{5,6}

¹ University of Antwerp, Antwerp, BE

² Department of ENT, AZ Herentals, Herentals, BE

³ Department of Nuclear Medicine, AZ Herentals, Herentals, BE

⁴ Department of Endocrinology, AZ Herentals, Herentals, BE

⁵ Department of Surgical and Molecular Pathology, Herentals, BE

⁶ Laboratory of Cell Biology and Histology, University of Antwerp, Antwerp, BE

Introduction

Primary hyperparathyroidism affects 22 per 100,000 people per year with a mean age onset of 56 years. Parathyroid adenomas account for 80 to 85% of cases of primary hyperparathyroidism. The median weight of parathyroid adenoma is 600 mg. In 5% of resected parathyroid adenomas the weight is more than 3500 mg and these are designated as giant parathyroid adenomas.

Case Description

A 56-year-old male patient was referred with complaints of anorexia, weight loss of 7 kg and fatigue since 7 months. Antecedents of nephrolithiasis were noted. The blood pressure, heart rate and ECG were normal. A blood analysis revealed hypercalcemia (3.11 mmol/l), Phosphor (0.67 mmol/l) and a high PTH level (333.6 ng/l). All other hormonal parameters including prolactin, LH, FSH, testosterone, cortisol, TSH, FT4, calcitonin and metanefrines were normal as well as the Vitamine D level and creatinin. BMC investigation in the L2–L4 region disclosed a T score of –1.3 SD indicating osteoporosis.

Results

An ultrasound investigation of thyroid and parathyroids was normal. The parathyroid scintigraphy with single photon emitted tomography (SPECT)/CT demonstrated a preferential MIBI-tracer accumulation after technetium subtraction infero-posterior to the right lobe of the thy-

roid. Surgical exploration revealed a tumoural mass lateral of the right N. Laryngeus recurrens and below the carotid artery. The mass was resected in toto and consisted of brown-dark yellow tissue 4.5 × 2.3 × 1.4 cm, weighing 6000 mg. A frozen section followed by conventional histology confirmed a large parathyroid adenoma, type giant parathyroid adenoma. Histology showed no signs of malignancy suggesting giant parathyroid adenoma.

Take Home Message/Conclusions

Patients with clinical signs of hypercalcemia and early onset osteoporosis should be extensively evaluated including parathyroid scintigraphy as classical ultra-sound investigation can be false negative even in the case of a giant parathyroid adenoma. SPECT-CT with MIBI-Technetium subtraction scintigraphy is an essential element for evaluating both the morphology of the parathyroid glands as well as the (patho)physiological function of the parathyroid glands.

Vascular Ehlers-Danlos Syndrome

Erica Lin and Paul Daniels

Mayo Clinic, Rochester, US

Introduction

Ehlers-Danlos syndrome (EDS) encompasses a group of connective tissue disorders characterized by joint hypermobility, skin extensibility, and tissue fragility. Of the 6 major subtypes outlined by the Villefranche classification, vascular EDS is one of the rarest.

Case Description

We herein describe a 45-year-old male who presented with abdominal pain. He reported a recent history of fevers, vomiting, diarrhea, arthralgias and myalgias. On

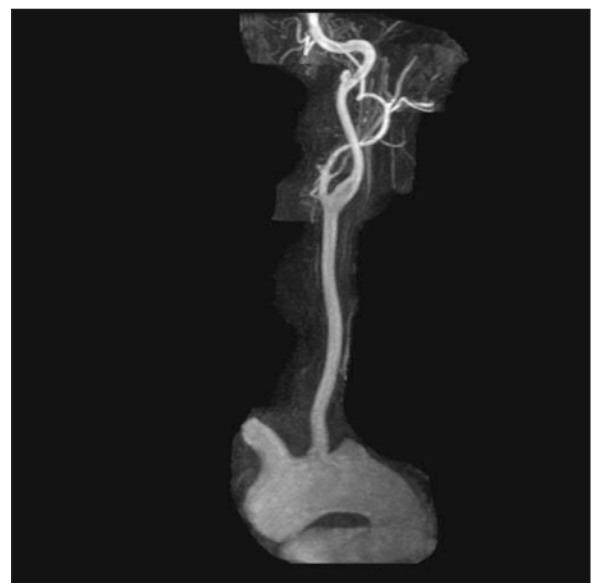

Figure 1: Magnetic resonance (MR) angiography shows a 5 × 6 mm aneurysm in the distal left internal carotid artery.

presentation, he was tall and overweight with pectus excavatum. There was no skin elasticity or joint hypermobility. The computed tomography (CT) angiogram of the chest and abdomen demonstrated superior mesenteric artery dissection with thrombus in the false lumen and celiac artery and left common iliac artery aneurysms. The magnetic resonance (MR) angiography of the head and neck demonstrated right posterior communicating artery and left internal carotid artery aneurysms. He was initiated on heparin and transitioned to warfarin.

Results

Genetics was consulted. Childhood history and detailed pedigree were obtained. He does not have easy bruising, easy bleeding, stretch marks, or poor wound healing. He denies a history of joint dislocation or pneumothorax. As a child, he had multiple traumatic fractures including right ankle, left lower extremity, right upper extremity, and left upper extremity. The family history included an ascending aortic aneurysm and groin aneurysm in his father and an aneurysm in his paternal uncle. Genetic testing showed a missense mutation: C to T substitution in exon 50 of the COL3 A1 gene. This mutation is consistent with vascular Ehlers-Danlos.

Take Home Message/Conclusions

Vascular EDS is an autosomal dominant condition caused by a mutation in the COL3 A1 gene, which disrupts the structural integrity of type III collagen. It is characterized by particular facial features, translucent skin with visible veins, easy bruising and rupture of blood vessels, uterus or intestines. An early diagnosis is critical, given the high incidence of life-threatening complications. The management focuses on genetic counseling, symptomatic therapy, and continual surveillance for complications. Healthcare providers should have a high level of suspicion for genetic connective tissue disorders in young patients with vascular abnormalities and suspicious family history.

Severe rhabdomyolysis after co-administration of fusidic acid and atorvastatin; report of a rare case

Dimitrios Patoulis¹, Theodoros Michailidis¹, Eleni Papchianou¹, Georgios Gavriiloglou¹, Maria Kalogirou², Anatoli Papadopoulos¹, Rafael Papadopoulos³ and Petros Keryttopoulos¹

¹ Department of Internal Medicine, General Hospital of Veria, Veria, GR

² General Hospital of Triakala, Trikala, GR

³ Department of Nephrology, General Hospital of Veria, Veria, GR

Introduction

Statins are among the most widely prescribed medications worldwide. Acute rhabdomyolysis is a life threatening complication, whether statins are administered alone or in combination with certain drug classes. Co-administration of a statin and fusidic acid is potentially fatal. Acute kidney injury is the most hazardous consequence of this drug to drug interaction. Only a few case reports and case series have been described in the literature. The exact mechanism of interaction remains unclear.

Case Description

A 79-year old woman presented to the emergency department with a one week history of limb weakness, myalgia and inability to stand and walk. She had a three month history of MSSA positive dermatitis of the right knee, which was initially treated with topical antibiotics. Due to inadequate response to treatment, she was prescribed a 3 week course of fusidic acid 250 mg four times daily and clindamycin 300 mg three times daily. She remained on her rest medication, which included atorvastatin 20 mg once daily. Physical examination was unremarkable, except for decrease in muscle strength in the proximal leg muscles.

Results

The clinical presentation of abnormal laboratory values (significant elevation of SGOT, SGPT, CK, CKMB and LDH levels), a deterioration of renal function and the presence of myoglobinuria were highly suggestive of acute rhabdomyolysis. The patient had no history of trauma, significant exertion or immobilization. A screening for autoimmune diseases (including ANA, anti-dsDNA, c-ANCA, p-ANCA, anti-Jo-1) was also negative. She did not give a written consent to perform a muscle biopsy, in order to confirm histologically the diagnosis. Finally, the diagnosis of acute rhabdomyolysis due to drug interaction between fusidic acid and atorvastatin was made.

Take Home Message/Conclusions

1. The mechanism of interaction between statins and fusidic acid is still under discussion. Further investigation is required.
2. Acute kidney injury is the main cause of morbid-

Table 1: The range of the main laboratory values of the patient during hospitalization.

	1 st day	2 nd day	4 th day	5 th day	6 th day	7 th day	8 th day	11 th day	14 th day	17 th day	21 st day
CPK (U/L)	17263	11632	12094	9835	13287	9104	4491	2231	987	556	227
Urea (mg/dl)	121	99	96	90	85	86	79	74	72	71	70
Crea (mg/dl)	2.6	1.86	1.4	1.69	1.58	1.58	1.58	1.53	1.51	1.52	1.51
SGOT (U/L)	635	541	552	524	574	440	251	117	94	65	44
SGPT (U/L)	317	284	318	356	401	391	322	163	123	87	57

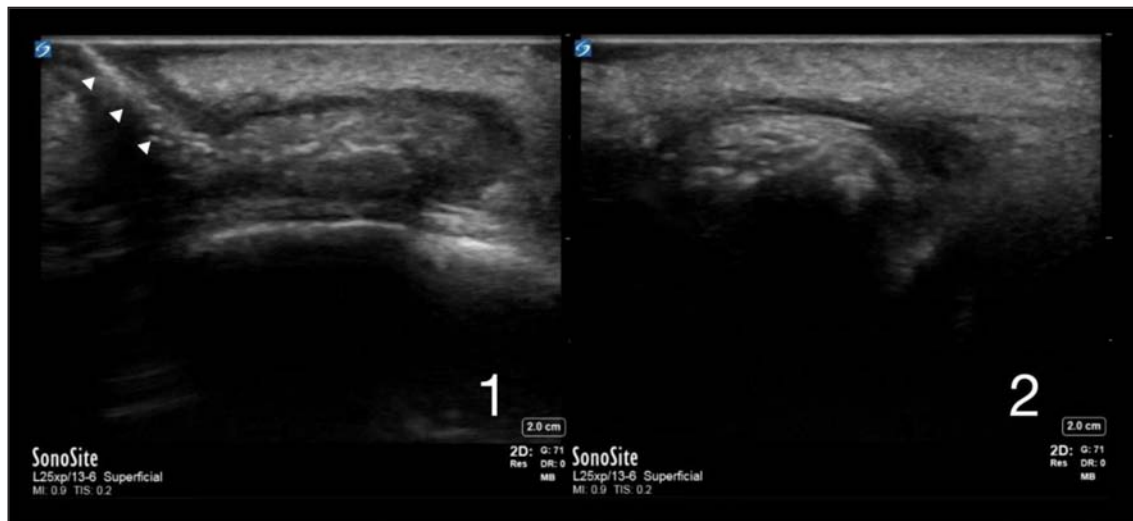


Figure 1: (1) Longitudinal view of larvae. Respiratory spiracle demarcated by arrows. (2) Transverse view of larvae with posterior acoustic shadowing.

ity and mortality in patients with rhabdomyolysis after co-administration of a statin and fusidic acid. Comorbidities and rest medication may worsen the clinical outcome.

3. Co-prescription of the two agents must be avoided in clinical practice. This drug to drug interaction is both predictable and preventable.

Ultrasound identification of cutaneous *dermatobia hominis* infestation presenting as non-healing abscess

Alan You and John Joyce
VCU Medical Center, Richmond, US

Introduction

Cutaneous myiasis, commonly caused by infestation of *Dermatobia hominis* larvae in humans, can produce furuncular lesions which are frequently mistaken for abscesses. Surges in international travel have led to an increased incidence of cutaneous myiasis cases in non-endemic countries, where it represents the fourth most common travel-associated skin disease. The utilization of point-of-care ultrasound (POCUS) provides direct and real-time visualization of the skin and underlying soft tissue which can be key to making an appropriate of cutaneous myiasis.

Case Description

Patient is a 15-year-old male who presented to the Emergency Department with a complaint of a non-healing abscess located on his right posterior shoulder one week after returning home from a family trip to Belize. He was evaluated by his primary care physician who provided a prescription for topical mupirocin ointment.

Due to the lack of improvement, the patient was seen again three weeks later. Wound cultures were sent and found to be positive for *Escherichia coli*. He was then started on a 14-day course of TMP-SMX. After continued lack of improvement, the patient presented to the ED for evaluation.

Results

In the ED, POCUS was performed which identified an anechoic cavity containing a hyperechoic lachrymiform structure with motion activity noted in its center. A linear incision was made longitudinally through the lesion revealing a 3 cm white, spiny organism. After careful dissection, the organism was removed with forceps and submitted to the pathology lab where it was confirmed to be *Dermatobia hominis*. The patient was discharged and seen one week later in the clinic where he was noted to have almost complete healing of the lesion.

Take Home Message/Conclusions

Cutaneous myiasis can have a non-specific appearance at the time of presentation and, therefore, is commonly mistaken for other skin abnormalities. The growth of international travel has resulted in more instances of myiasis in non-endemic regions. Emergency medicine physicians should have high clinical suspicion for cutaneous myiasis in cases of non-healing abscesses, particularly in patients with history of travel to high-risk countries. Furthermore, POCUS should be considered a mandatory component of the diagnostic evaluation of these cases as the presence of a motile, lachrymiform structure on ultrasound can be diagnostic of cutaneous myiasis.

Competing Interests

The authors have no competing interests to declare.

How to cite this article: Shahzad, A and Cohrs, RJ. 2018. Congress Abstracts: 2018-European Clinical Case Reports Congress (EUCCR-2018), 21–22 April 2018, Vienna, Austria. *European Journal of Molecular & Clinical Medicine*, 5(1), pp. 51–84, DOI: <https://doi.org/10.5334/ejmcm.258>

Accepted: 27 July 2018 **Published:** 22 August 2018

Copyright: © 2018 The Author(s). This is an open-access article distributed under the terms of the Creative Commons Attribution 4.0 International License (CC-BY 4.0), which permits unrestricted use, distribution, and reproduction in any medium, provided the original author and source are credited. See <http://creativecommons.org/licenses/by/4.0/>.

]u[

European Journal of Molecular & Clinical Medicine, is a peer-reviewed open access journal published by Ubiquity Press on behalf of The European Society for Translational Medicine.

OPEN ACCESS 