

Original article

Role of fine needle aspiration cytology in assessment of cervical lymphadenopathy in different age groups.

**Authors: Dr. Mamta Kannaujia (J.R)¹, Dr. Chandrakanta (Professor)²,
Dr. Prashant Singh * (Associate Professor)³, Dr. Pooja Nagayach (Associate
Professor)⁴, Dr. Dharmendra Kumar (Professor E.N.T Department)⁵.
Affiliation^(1,2,3,4): Department of Pathology, S.N. Medical College Agra (U.P.)**

* Corresponding Author Email id: drprashant4488@gmail.com.

ABSTRACT

Introduction: Cervical lymphadenopathy is very common presentation in clinical practice of our country. The cause of cervical lymphadenopathy can range from reactive lesion to tuberculosis to malignancy. Fine needle aspiration cytology (FNAC) has arose as a sensitive, specific, and cost-effective procedure to diagnose cervical lymphadenopathy.

Aim: The study was conducted to evaluate the role of FNAC in assessing various causes of cervical lymphadenopathy in different age groups based on different cytomorphological patterns.

Materials and methods: This cross-sectional and observational study conducted in Department of Pathology S.N Medical college Agra over a period of 18 month (from January 2021 to Jun 2022). Total 100 patients with cervical lymphadenopathy were selected in our study. Brief history and clinical examination was carried out .The patient made comfortable and palpable mass was made prominent and cleaned with 70% isopropyl alcohol and FNAC was done. The aspirated material was expressed on glass slide and smears were prepared. The smears air dried, fixed in Methanol and stained by May–Grunwal Giemsa stain and cytomorphology was studied. Ziehl-Neelsen staining was done in cases of cytological diagnosis of granulomatous diseases, necrotic and suppurative aspirates .

Results: Total 100 patient were taken in that study. 100 patient were divided in 0-15 years age group, 16-30 years age group, 31-45 years age group, 46-60 years age group and >60 year age group.

Patients with Reactive lymphadenitis 50% were in 0-15 years, 40% were in 16-30 years and 10% were in 46-60 years. Granulomatous lymphadenitis 25% in 0-15 years, 50% in 16-30 years and 25% in 31-45 years. Tubercular lymphadenitis 17.5% were in 0-15 years, 62.50% in 16-30 years and 12.5% in 31-45 years and 05% in 46-60 years . Only 2.5% were present in > 60 years of age group.

Nonspecific necrotizing lymphadenitis 16.66% in 0-15 years, 33.33% in 16-30 years, 25.00% in 31-45 years and 25.0% in 46-60 years. Suppurative lymphadenitis 100% in 0-15 years. Hodgkin's Lymphoma 33.33% in 0-15 years, 33.33% in 16-30 years and 33.33% in 31-45 years.

Non-Hodgkin's Lymphoma 100% in 46-60 years . In Metastatic carcinoma 37.5% in 46-60 years and 31.25% in >60 years and 25.00% in 31-45 years.

Conclusion: In our study we concluded that there were various etiological factors which play a major role in causing cervical lymphadenopathy in different age groups.

Key words: FNAC, Cervical lymphadenopathy, Cytomorphology.

INTRODUCTION

Cervical lymphadenopathy is very common presentation in clinical practice of our country. The cause of cervical lymphadenopathy can range from reactive lesion to tuberculosis to malignancy. The management of these various lesions is very different and hence the purpose of to find out the etiology is highly important. A rapid, cheap, and reliable investigative device is required from many years, pathologists have working with needles to obtain cell and tissue fragments to make the diagnosis of the lesions. Fine needle aspiration cytology (FNAC) has arose as a sensitive, specific, and cost-effective procedure to diagnose cervical lymphadenopathy.¹

In 1921, Guthrie tried to correlate lymph node aspiration cytology with various disease processes.^{2,3} FNAC is chiefly helpful in the work-up of cervical lymphadenopathy because biopsy of cervical lymphadenopathy should be evaded unless all other diagnostic modalities have failed to found a diagnosis.^{2,4}

FNAC is nowadays accepted as a rapid diagnostic method because of its simplicity, early accessibility of results, fewer traumas and complications.^{5,6}

Assessment of a patient with cervical lymphadenopathy should always begin with a detailed history, followed by a complete head and neck examination. If the physical examination does not clarify the neck mass, a fine needle aspiration (FNA) of the mass may be performed. The role of FNAC in lymphadenopathy has previously been established by a number of studies.⁷⁻¹¹

AIM-The study was conducted to evaluate the role of FNAC in assessing various causes of cervical lymphadenopathy in different age groups based on different cytomorphological patterns.

MATERIALS AND METHODS

In this cross-sectional and Observational study, the material for the study was collected from patient being referred to Cytology section of Department of Pathology, S.N. Medical Collage, Agra over a period of 18 months (From January 2021 to June 2022). Total 100 patients were included in our study.

INCLUSION CRITERIA

For the purpose of study following criteria was used.

All patients of different age groups coming with cervical lymphadenopathy in FNAC clinic of Pathology Department of S.N Medical College, Agra during the study period were included.

EXCLUSION CRITERIA

Aspirated material with inadequate cellularity.

Procedure

Patients with cervical lymphadenopathy were selected in the study. Brief history and meticulous clinical examination was carried out. The patient made comfortable and palpable mass was made prominent and cleaned with 70% isopropyl alcohol and FNAC was done aseptically using 22-23G needle of 1-1.5 inch with a 20 ml disposable syringe. After that needle was removed, pressure was applied to the area of aspiration to avoid hematoma formation. The aspirated material was expressed on glass slide and smears were prepared.

The smears air dried, fixed in Methanol and stained by May-Grunwal Giemsa stain and cytomorphology was studied.

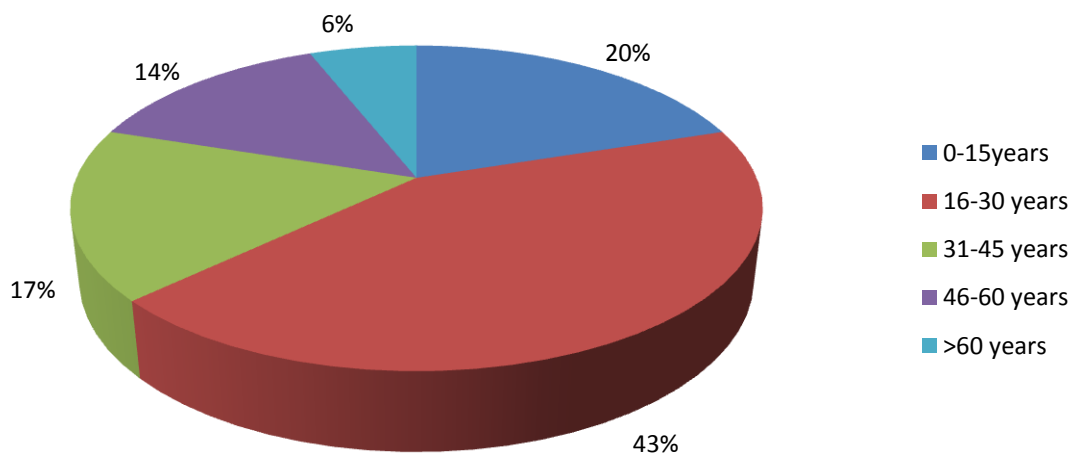
Ziehl-Neelsen staining was done in cases of cytological diagnosis of granulomatous diseases, necrotic and suppurative aspirates. In cases where fluid was aspirated, the fluid

was centrifuged and smear was prepared from sediment followed by the above staining method.

OBSERVATION AND RESULTS

In that study total 100 patient were included with complain of cervical lymphadenopathy and diagnosis was made on the basis of cytomorphological features of the diseases.100 patient were divided in five age groups.0-15 years age group,16-30 years age group,31-45 years age group,46-60year age group and >60year age group.In that study 20% of the patients of the cervical lymphadenopathy were seen in 0-15 years of age group. 43% subjects in the 16-30 years of age group, 17% in the 31-45 years of age group, 14% in the 46-60 years of age group and 6% of the patients were in more than 60 years age group.[Table/Fig-1]

Age Groups	Total number of cases	Percentages
0-15years	20	20%
16-30 years	43	43%
31-45 years	17	17%
46-60 years	14	14%
>60 years	06	06%
Total	100	100%



[Table/Fig-1]:AGE DISTRIBUTION OF STUDY SUBJECTS

Out of 10 patients with Reactive lymphadenitis 50% were in the age group of 0-15 years, 40% were in the age group of 16-30 years and only 10% were in the age group of 46-60 years. Out of 16 patients with Granulomatous lymphadenitis 25% were in the age group of 0-15 years, 50% were in the age group of 16-30 years and 25% were in the age group of 31-45 years .Out of 40 patients with Tubercular lymphadenitis 17.5% were in the age group of 0-15 years, 62.50% were in the age group of 16-30 years and 12.5% were in the age group of 31-45 years and 05% in the age group 46-60 years .Only 2.5% were present in more than 60 years of age group.

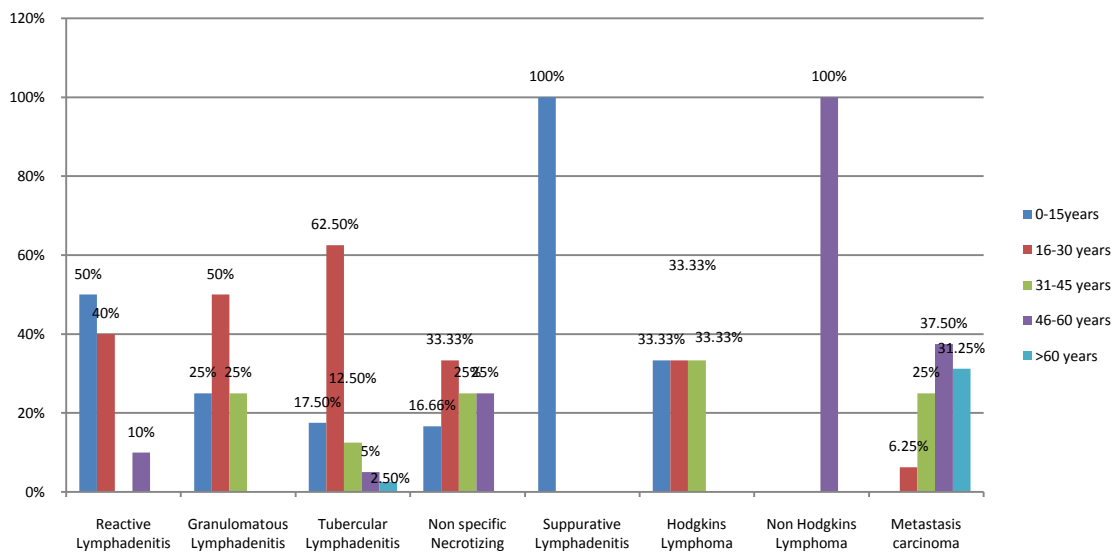
Out of 12 patients with Nonspecific necrotizing lymphadenitis 16.66% were in age group of 0-15 years, 33.33% were in the age group of 16-30 years, 25.00% were in the age group of 31-45 years and 25.0% were in the age group of 46-60 years. Only one case of Suppurative lymphadenitis was found that in the age group of 0-15 years (100%).Out of 03 patients with

Hodgkin's Lymphoma 33.33% were in the age group of 0-15 years, 33.33% were in the age group of 16-30 years and 33.33% were in the age group of 31-45 years .None of the patients were present in the age group of 46-60 years and more than 60 years of age group .

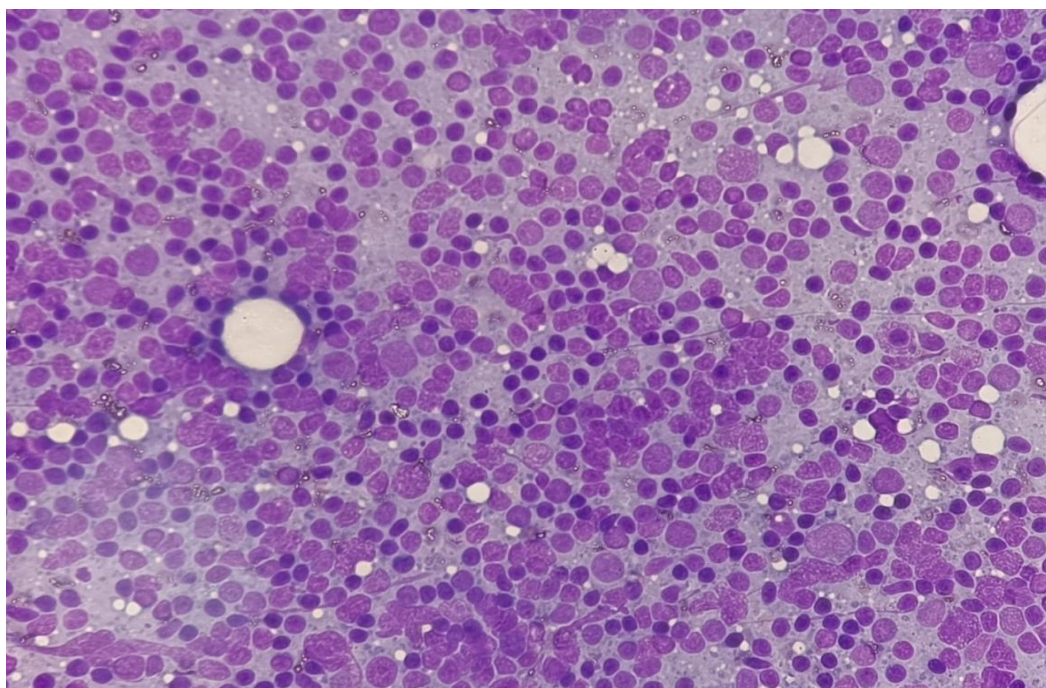
Out of 02 patients of Non-Hodgkin's Lymphoma 100% of the patients were present in 46-60 years age group .Out of 16 patients of Metastatic carcinoma 37.5% of the patients were in the 46-60 years of age and 31.25% were in the more than 60 years of age group and 25.00% were in the 31-45 years of age group.[Table/Fig.2-9]

Age groups	Reactive Lymphadenitis	Granulomatous Lymphadenitis	Tubercular Lymphadenitis	Non specific Necrotizing lymphadenitis	Suppurative Lymphadenitis	Hodgkins Lymphoma	Non Hodgkins Lymphoma	Meta stasis carcinoma	Others	Total
0-15years	05 (50%)	04 (25%)	07 (17.5%)	02 (16.66%)	01 (100%)	01 (33.3%)	0 (0%)	0 (0%)	0 (0%)	20
16-30 years	04 (40%)	08 (50%)	25 (62.5%)	04 (33.33%)	0 (0%)	01 (33.3%)	0 (0%)	01 (6.25%)	0 (0%)	43
31-45 years	0 (0%)	04 (25%)	05 (12.5%)	03 (25%)	0 (0%)	01 (33.3%)	0 (0%)	04 (25%)	0 (0%)	17
46-60 years	01 (10%)	0 (0%)	02 (5%)	03 (25%)	0 (0%)	0 (0%)	02 (100%)	06 (37.5%)	0 (0%)	14
>60 years	0 (0%)	0 (0%)	01 (2.5%)	0 (0%)	0 (0%)	0 (0%)	0 (0%)	05 (31.25%)	0 (0%)	06
Total	10	16	40	12	01	03	02	16	00	100

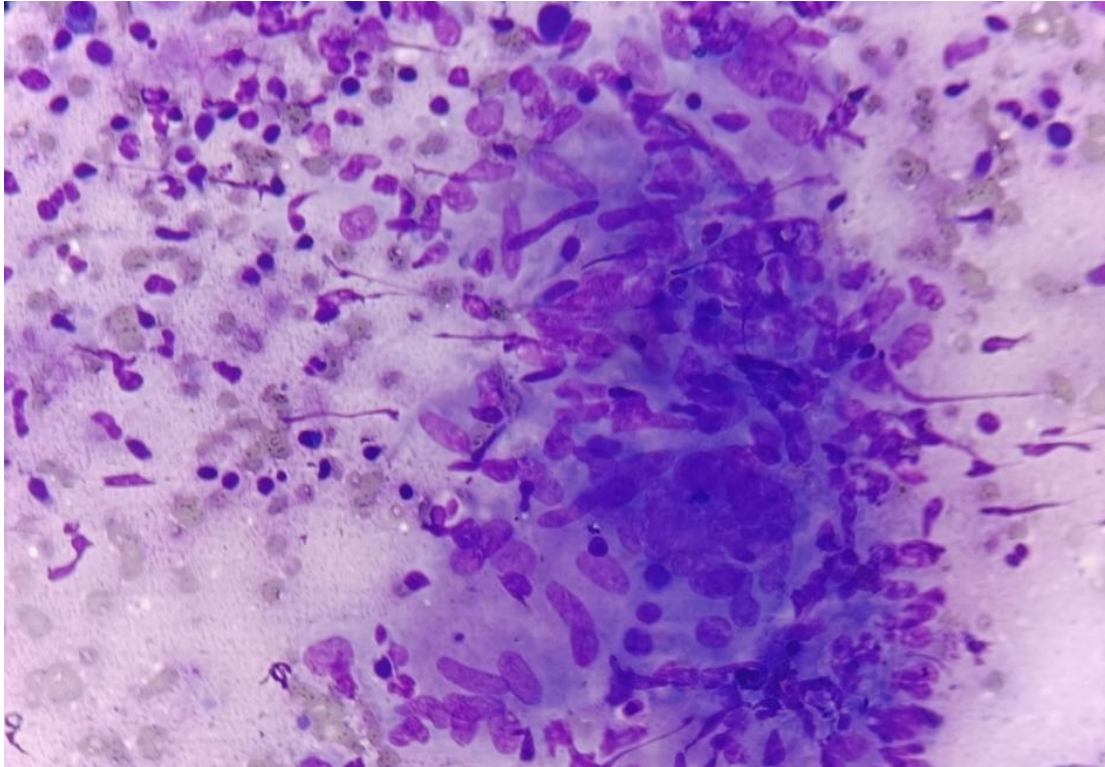
Chi square test with p value less than 0.05 is significant



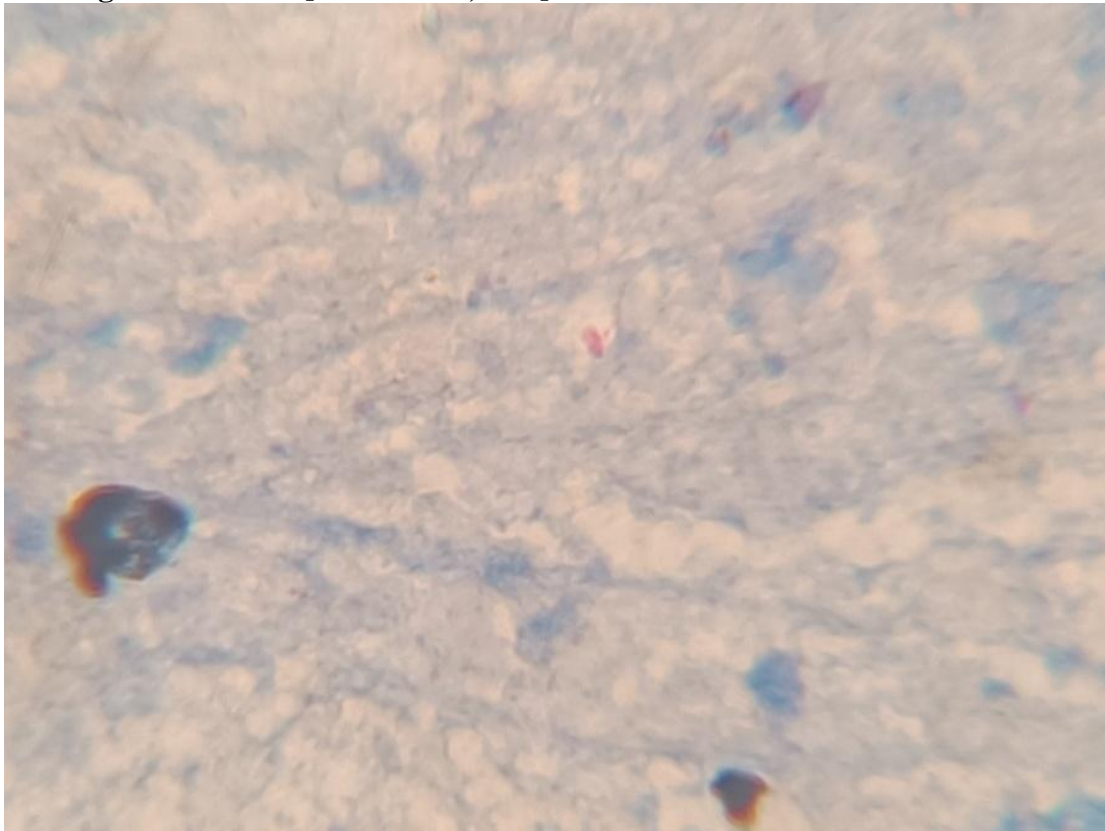
[Table/Fig-2]: Distribution of Lesions Based on Age Groups



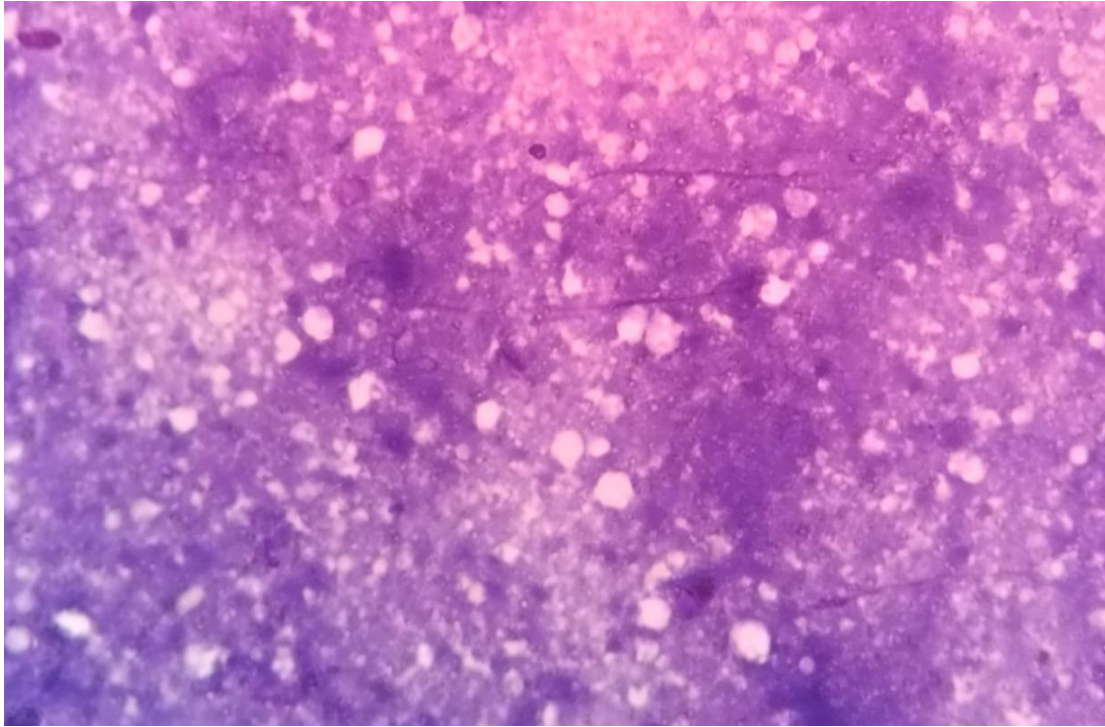
[Table/Fig.3]-Reactive lymphadenitis-Mixed population of lymphoid cells with centrocytes, centroblast and predominance of small lymphocytes. [MGG stain ,40X].



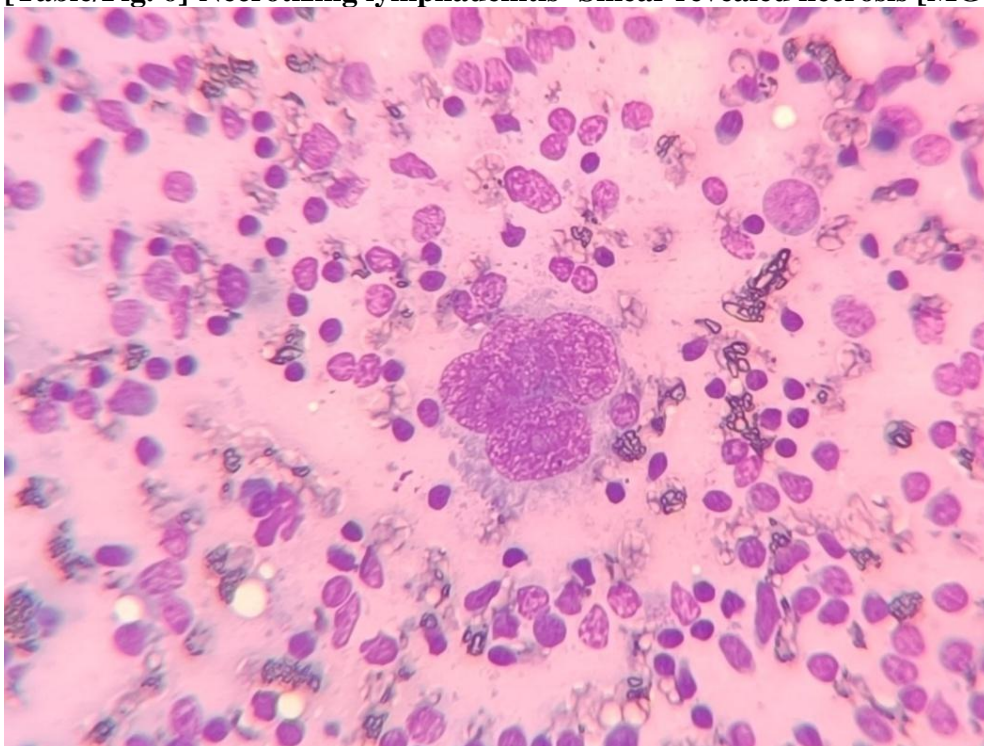
[Table/Fig. 4]-Granulomatous lymphadenitis-Group of epithelioid cells having elongated nuclei, the shape of which resembles the sole of shoe or boomerang, few lymphocytes forming Granuloma. [MGG stain, 40X].



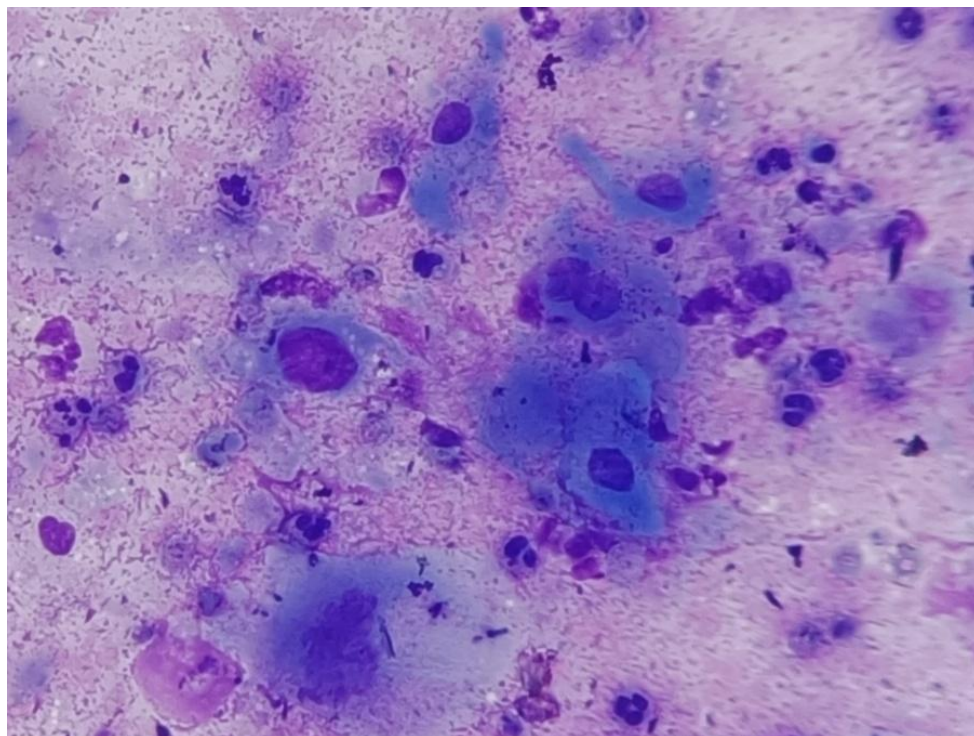
[Table/Fig.5]-Mycobacteria [acid fast bacilli] in ZN stain (Ziehl-Neelsen stain 100X).



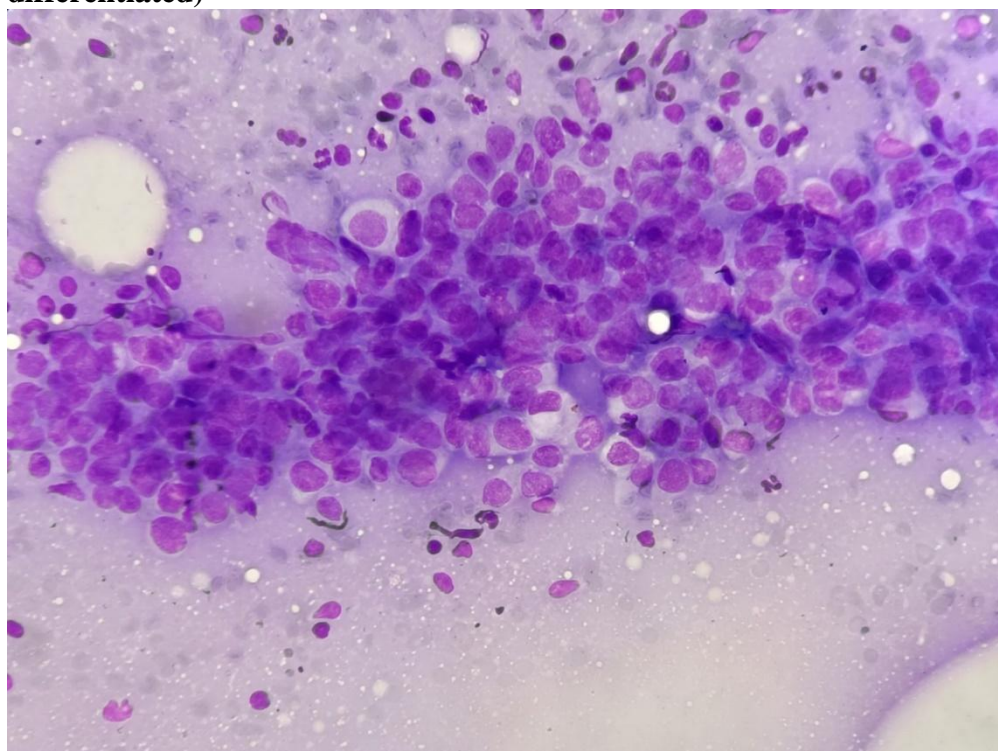
[Table/Fig. 6]-Necrotizing lymphadenitis -Smear revealed necrosis [MGG stain,40X].



[Table/Fig.7]-Hodgkin's lymphoma-Multinucleated Hodgkin cells scattered among the background of, lymphocytes, eosinophils, histiocytes and plasma cells [MGG stain, 40X]



[Table/Fig.8]: Metastatic squamous cell carcinoma-Numerous singly dispersed keratinized squamous cells with pleomorphic hyperchromatic nuclei [MGG stain,40X] (well differentiated)



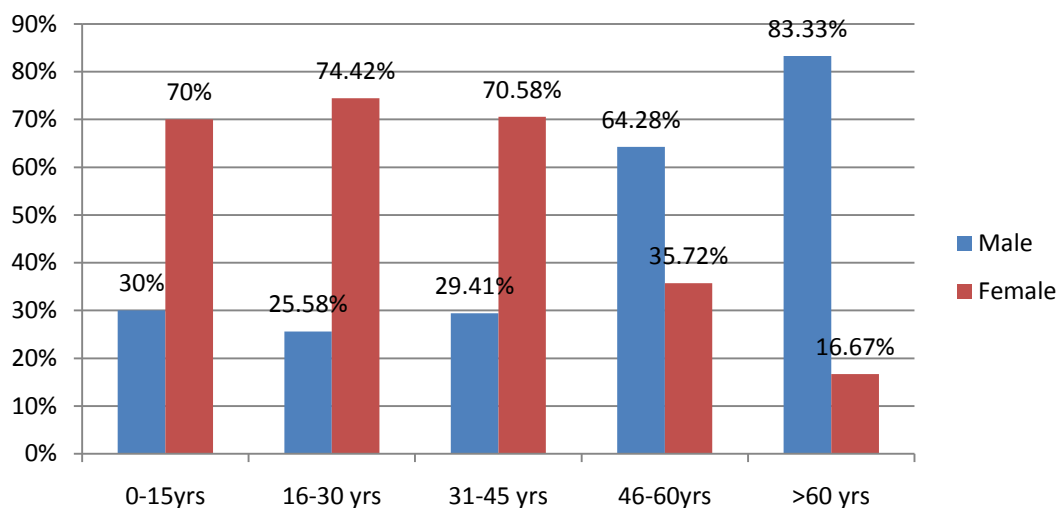
[Table/Fig.9]:Metastatic adenocarcinoma-disorganized sheet of malignant cells with nuclear crowding, overlapping and acini formation [MGG stain, 40X].

Out of 100 patients 36% were the males and 64% were the females.

In the age group of 0-15 years, 30% were the males and 70% were the females. In the age group of 16-30 years, 25.58% were the males and 74.42% were the females. In the age group of 31-45 years 29.41% were the males and 70.58% were the females. In the age group of 46-60 years

64.28% were the males and 35.72% were the females. In the age group of more than 60 years 83.33% were the males and 16.67% were the females.

[Table/Fig.10]

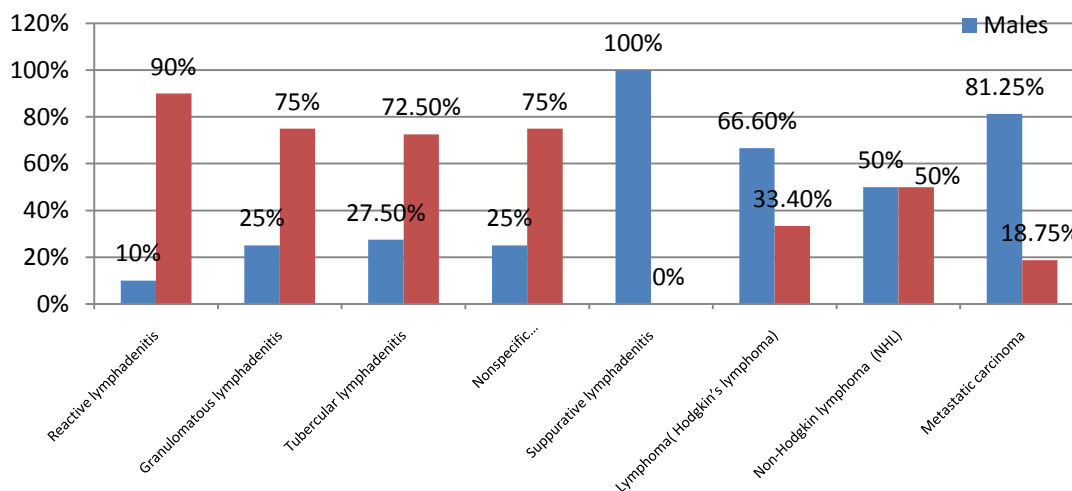


[Table/Fig.10]Distribution of patients based on Age Groups and Gender

Patients with reactive lymphadenitis 10% of the were the males and 90% were the females. Patients with Granulomatous Lymphadenitis 25% were the males and 75% were the females. Patients with Tubercular Lymphadenitis 27.50% were the males and 72.50% were the females. In thepatients with Nonspecific Necrotizing lymphadenitis 25.00% were the males and 75.00% were the females. In the suppurative lymphadenitis 100% of the patients were the males. In Hodgkin’s lymphoma, 66.6% were the males and 33.4% were the females. In the patients with Non- Hodgkin’s lymphoma 50% were the males and 50% were the females. In metastatic carcinoma 81.25% were the males and 18.75% were the females. [Table/Fig.11]

	Males	Females	Total %
Reactive lymphadenitis	01 (10%)	09 (90%)	10 (100%)
Granulomatous lymphadenitis	04 (25%)	12 (75%)	16 (100%)
Tubercular lymphadenitis	11 (27.5%)	29 (72.5%)	40 (100%)
Nonspecific necrotizing lymphdenitis	03 (25%)	09 (75%)	12 (100%)
Suppurative lymphadenitis	01 (100%)	0 (0%)	01(100%)
Lymphoma(Hodgkin’s lymphoma)	02 (66.6%)	01 (33.4%)	03 (100%)
Non-Hodgkin lymphoma (NHL)	01 (50%)	01 (50%)	02 (100%)
Metastatic carcinoma	13 (81.25%)	03 (18.75%)	16(100%)

Chi square test with p value less than 0.05 is significant



[Table/Fig.11]:Distribution of Lesions Based on Gender

STATISTICAL ANALYSIS

The data for the present study was entered in the Microsoft Excel 2007 and analyzed using the SPSS statistical software 19.0 Version. The descriptive statistics included frequency and percentages . The inferential statistics included the use of Chi square test.

Chi Square Test

Chi-square is a statistical test commonly used to compare observed data with data we would expect to obtain according to a specific hypothesis. When an analyst attempts to fit a statistical model to observed data, he or she may wonder how well the model actually reflects the data. How "close" are the observed values to those which would be expected under the fitted model? One statistical test that addresses this issue is the chi-square goodness of fit test. This test is commonly used to test association of variables in two-way tables, where the assumed model of independence is evaluated against the observed data. In general, the *chi-square test statistic* is of the form

$$X^2 = \sum \frac{(\text{observed} - \text{expected})^2}{\text{expected}}$$

If the computed test statistic is large, then the observed and expected values are not close and the model is a poor fit to the data.

DISCUSSION

Localized or regional lymphadenopathy is defined as the enlargement of lymph node within closed anatomic region. Enlarged cervical lymph nodes are always available for FNAC and therefore it play a major role in diagnosis of cervical lymph node diseases. FNAC also plays a major role in developing countries like India, because it is comparatively cheap, easy to perform and practically has little complications. A round, firm well defined lymph node that is present for more than 8 weeks, or a lymph node that is fixed to skin ,deep anatomic planes, or other lymph node should be considered for FNAC regardless of their location, patient age or symptoms.[12]

The diagnosis provided by FNAC has been shown to correlate very well histopathological diagnosis after biopsy.

Many times, an aspirated material may be the only tissue for making a diagnosis, as some time biopsy may not be possible for various reasons.

FNAC may often be the only tool for diagnosis for management of patients of metastatic carcinoma.[13]

The most common cause of benign cervical lymphadenopathy was either tubercular infection or viral or bacterial depending on country regions.[12]

Out of 100 patients, maximum number of cases (43 cases, 43%) were found in 16 -30 years age group followed by cases (20 cases,20%) in 0-15 years age group.Our study was found concordant with other studies. Agarwal D et al found 47.40%, 36.88%[14] and Amit KN et al found 40.37%,35.47%.[12],[Table/Fig.12].

Age	Agarwal D et al[14]	Amit KN et al[12]	Present study
16-30 years	47.40%	40.37%	43%
0-15 years	36.88%	35.47%	20%

[Table/Fig.12]:Comparing number of cases with other studies.

Female preponderance was seen in our study (64%).Our study was found concordant with Patel KR et al (53.57%)[15], Bhavani C et al(53.20%)[16], Amit K N et al (51.79%)[12], Agarwal N et al (54.31%)[17],[Table/Fig.13].

Gender	Patel KR et al[15]	Bhavani C et al[16]	Amit KN et al[12]	Agarwal N et al[17]	Present study
M	46.43%	46.8%	48.21%	45.31%	36%
F	53.57%	53.20%	51.79%	54.31%	64%
M:F	1:1.2	1:1.1	1:1.1	1:1.9	1:1.7

[Table/Fig.13]:Comparing number of cases gender wise with other studies.

In our study, 79 out of 100 cases were benign (79%) followed by malignant 21 cases (21%). Our study was in close proximity with studies done by Patel KR et al (88.26%,11.73%)[15], Bhavani C et al (87.52%,12.45%)[16],AmitKN et al (88.08%,11.91%)[12].

In our study among the benign cases of cervical lymphadenopathy, the most common cause was tuberculous lymphadenitis, accounting 40 cases (40%) , followed by granulomatous lymphadenitis accounting 16 cases (16%) , necrotizing lymphadenitis 12cases (12%), reactive lymphadenitis 10 cases (10%) and single (1%) case of suppurative lymphadenitis. The high incidence of TB in our study may be due to the endemicity of the disease in India. Moreover the most common form of extra-pulmonary tuberculosis is tuberculous lymphadenitis with cervical lymph nodes being the most commonly involved In our study out of 100 patients 69 shows necrotic material, or granuloma with necrosis or suppuration in witch 40 patients were positive for Ziehl-Neelsen staining, diagnosis of tuberculosis was made on basis of Z-N staining.Our study was in close proximity with Kumar H et al[13],Bhavani C et al[16], Amit KN et al[12],Agarwal N et al[17] and Hashmi AA et al[18].

In our study females were more commonly affected by Tuberculosis 29cases (72.5%) out of 40 cases which were found more or less concordant with Patel KR et al (55.61%)[15], Hashmi AA et al(38%)[18] and Kumar H et al(47.67%)[13],[Table/Fig.14]

Studies	Tubercular lymphadenitis	Granulomatous lymphadenitis	Necrotizing lymphadenitis	Reactive lymphadenitis
Kumar H et al[13]	47.67%	0.94%	-	44.39%
Bhavani C et al[16]	36.97%	9.8%	27.17%	35.47%
Amit KN et al[12]	39.70%	13.71%	25.99%	33.93%
Hashmi AA et al[18]	40.2%	-	1.1%	29.4%
Present study	40%	16%	12%	10%

[Table/Fig.14]Comparison of incidence wise commonest Benign lesions with other studies. In our study 21 cases out of 100 (21%) were malignant. Among the malignant cases of cervical lymphadenopathy lymphoma accounting 05 cases (05% of all cases and 23.80% of malignant cases) and metastatic carcinoma accounting 16 cases (16% of total cases and 76.19% of malignant cases).Our study was concordant with other studies Agarwal D et al[14],Bhavani C et al[16],Kadam SA et al[19] and was discordant with Kumar H et al(4.2% lymphoma,2.8% metastatic carcinoma)[13][Table/Fig15].

Studies	Lymphoma	Metastatic carcinoma
Agarwal D et al[14]	02%	11.85%
Bhavani C et al [16]	1.13%	11.32%
Kadam SA et al[19]	1.81%	14.54%
Present study	05%	16%

[Table/Fig.15] Comparison of Malignant lesions with other studies.

In our study most common cause of metastatic carcinoma was metastatic squamous cell carcinoma followed by metastatic adenocarcinoma.Our study was in close proximity of study done by Bhavani C et al[16], Amit KN et al[12], Kumar H et al[13], Kadam SA et al[19]. FNAC has accepted higher sensitivity in the diagnostic workup of metastatic malignancies.

Limitation(s):

Histopathological and other ancillary techniques for confirmation of cases was not done.

Conclusions

Fine needle aspiration cytology is safe, simple and rapid method for diagnosis of various cases of cervical lymphadenopathy. FNAC of lymph node is very simple and useful technique in the diagnosis of various cases of cervical lymphadenopathies. It is very easy and cheap method.

FNAC may be the only technique for the diagnosis of metastatic carcinoma in lymph node.

In our study we concluded that there were various etiological factors which play a major role in causing cervical lymphadenopathy in different age groups.

REFERENCES

1. Lau SK, Wei WI, Hsu C, Engzell UC. Fine needle aspiration biopsy of tuberculous cervical lymphadenopathy. *Aust N Z J Surg* 1988;58:947-50.
2. R.K. Narang, S. Pradhan, R.P. Singh And S. Chaturvedi. Place of fine needle aspiration cytology in the diagnosis of lymphadenopathy. *Ind. J. Tub.*, 1990, 37, 29.
3. Guthrie C.G. Gland puncture as a diagnostic measure. *Bull. Johns Hopkins Hosp.* 1921, 32, 266.
4. Layfield LJ. Fine-needle aspiration of the head and neck. *Pathology (Philadelphia, Pa.)*. 1996 Jan 1;4(2):409-38.
5. Khajuria R, Goswami KC, Singh K, Dubey VK. Pattern of lymphadenopathy on fine needle aspiration cytology in Jammu. *JK Sci.* 2006; vol;8(3):157-9.
6. Menon JM, Talpur AA, Solangi R, Qazi AR, Naqvi SQ, Akhund AA. An audit of peripheral lymphadenopathy. *Pak J Surg.* 2007;23:183-6.
7. Steel BL, Schwart MR, Ramzy I. Fine needle aspiration biopsy in the diagnosis of lymphadenopathy in 1103 patients. Role, limitations and analysis of diagnostic pitfalls. *Acta Cytol* 1995; 39:76-81.
8. Lioe TF, Elliott H, Allen DC, Spence RA. The role of fine needle aspiration cytology in the investigation of superficial lymphadenopathy: Uses and limitations of the technique. *CytoPathol* 1998;10:291-7.
9. Pandit AA, Candes FP, Khubchandani SR. Fine needle aspiration cytology of lymph nodes. *J Postgrad Med* 1987;33:134-6.
10. Prasad RR, Narasimhan R, Sankran V, Veliath AJ. Fine needle aspiration cytology in the diagnosis of superficial lymphadenopathy: An analysis of 2418 cases. *Diagn Cytol* 1993;15:382-6.
11. Paul PC, Goswami BK, Chakrabarty S, Giri A, Pramanik R. Fine needle aspiration cytology of lymph nodes-An institutional study of 1448 cases over a five year period. *J Cytol* 2004;21:187-90.
12. Amit KN, Kirti N, Jha J, Sudhir K. Role of fine needle aspiration cytology in assessment of cervical lymphadenopathy in variable age groups: A retrospective study. *International Journal of Medical Research & Health Sciences.* 2016;5(11):306-10.
13. Kumar H, Chandanwale SS, Gore CR, Buch AC, Satav VH, Pagaro PM. Role of fine needle aspiration cytology in assessment of cervical lymphadenopathy. *Medical Journal of Dr. DY Patil University.* 2013 Oct 1;6(4):400.
14. Agarwal D, Bansal P, Rani B, Sharma S, Chawla S, Bharat V, Sharma S. Evaluation of etiology of lymphadenopathy in different age groups using fine needle aspiration cytology: A retrospective study. *Internet J Pathol.* 2010;10(2).
15. Patel KR, Patel JM, Shah KJ, Patel NU. Role of FNAC in diagnosis of cervical lymphadenopathy.
16. Bhavani C, Neeraja M, Varalakshmi KP, Ramana Babu PV, Chaitanya B, Sravani P. Role of FNAC in the diagnosis of cervical lymphadenopathy. *Int J Med Res Rev.* 2014;2(6):599-603.
17. Agrawal N, Sharma HS, Hansrajani V, Samadhiya M, Raghuwanshi V, Khandelwal P, Tignath A. Study of Cervical Neck Masses and Role of Fine Needle Aspiration Cytology in Central India. *Annals of International Medical and Dental Research.* 2017;3(3):19.
18. Hashmi AA, Naz S, Ahmed O, Yaqeen SR, Irfan M, Kamal A, Faridi N. Utility of Fine Needle Aspiration Cytology in the Evaluation of Lymphadenopathy. *Cureus.* 2020 Dec 9;12(12).

19. Kadam SA, Miskin AT, Dombale VD. Role of FNAC in study of cytomorphological patterns in cervical lymph node. *Medica*. 2020 Jul;9(2):88.