

Original research article

Total hip arthroplasty in displaced neck of femur fracture: A radiological outcome assessment

Dr. Rohit Amar¹, Dr. G.N.Khare², Dr. Rupesh Jung Belbase³, Dr. Yogesh Kumar⁴

¹Junior Resident, Department of Orthopaedics, Institute of Medical Sciences, Banaras Hindu University, Varanasi, Uttar Pradesh, India

²Professor, Department of Orthopaedics, Institute of Medical Sciences, Banaras Hindu University, Varanasi, Uttar Pradesh, India

³Junior Resident, Department of Orthopaedics, Institute of Medical Sciences, Banaras Hindu University, Varanasi, Uttar Pradesh, India

⁴Junior Resident, Department of Orthopaedics, Institute of Medical Sciences, Banaras Hindu University, Varanasi, Uttar Pradesh, India

Corresponding Author: Dr. Rohit Amar

Abstract

Aim: The Purpose of this study is to assess the Radiological outcome of Total Hip Arthroplasty in Displaced fracture Neck of femur.

Materials and Methods: This prospective observational study was carried out in the Department of Orthopaedics, Institute of Medical Sciences, Banaras Hindu University, Varanasi, Uttar Pradesh, India, from November 2016 to January 2018. Total 120 patients were patients treated with total hip replacement. Radiographic evaluation includes Loosening of the acetabulum and femoral components, Inclination of Acetabular cup, Stem position of femoral component, Vertical subsidence, Migration of the Acetabular cup and Heterotopic Ossification. Modified Harris hip score was used for clinical and functional evaluation of patients. Plain X-ray pelvis with both hips and proximal femur-AP view and X-ray of the operated hip lateral view for radiological evaluation.

Results: Out of 120, 86 patients were male and 34 female, most of the patients in were above 50 year and followed by 40-50 year. Patients scored 54.17% excellent, 26.67 good, 8.33% fair and 10.83% patients scored poor. Observations and measurements were done on the AP radiograph of pelvis and AP/Lateral view of operated hip. The normal acetabular cup inclination is 30° to 45°. In our study 78.33% neutral, 11.67% vertical and 10% horizontal position were seen. The ideal position of stem of femoral component is central. In this study we had 76.67% central, 14.17% each in valgus and 9.16% varus position. Varus position of the stem may lead to complications such as anterior thigh pain and periprosthetic fractures. There were 3.33% subsidence and 1.67% migration seen and Class II heterotopic ossification was noted in 7 hip, i.e., 5.83 % incidence who underwent THA. Out of 120, 7 patient with class II heterotrophic ossification seen. The

Conclusion: we concluded that the total hip arthroplasty gave better results in displaced Intracapsular neck of femur fractures radiologically.

Keywords: hip arthroplasty, femur, fractures

Introduction

Intracapsular fractures of the proximal femur form a major share of fractures in the elderly.¹ Osteoporosis, co-morbidities, increased incidence of trivial trauma increases the incidence and complicates the treatment of these fractures. This high incidence is due to weak

bones and increased incidence of trivial trauma. People in this age group suffer from numerous illnesses that can aggravate the morbidity following fractures and complicate the treatment of these fractures. The treatment goal is to return the patient to his or her pre-morbid status of function. Increase in the average lifespan and improved medical facilities have greatly increased the incidence of these fractures.

Management of femoral neck fractures in elderly patients has been controversial. Femoral neck fractures have been considered 'unsolvable fractures' in the older era of orthopedics due to the high rate of associated complications, which include nonunion and avascular necrosis of the femoral head, among others. Presently, there are multiple surgical treatment options (cannulated screws, dynamic hip screw systems, blade plates, hemi and total hip arthroplasty) available. Intracapsular extent of the fracture, tenuous blood supply to the femoral head going through the neck and difficulty in maintaining fracture reduction have been cited as reasons for failure of fixation.²⁻⁴ Although treatment methods have been refined over the years, a consensus on the ideal treatment remains elusive.

Important factors to consider in choosing any treatment modality are intrinsic, viz. patient age, general medical condition, type of fracture; and extrinsic, viz. availability of facilities and socio-economic status.

Though non-operative treatment of these fractures has been documented,¹ there are currently very few indications for the same (being limited to terminally ill patients or those who are bedridden and non-ambulatory). Surgical treatment has been established as the gold standard; however, the surgical option remains a dilemma. Open reduction and internal fixation has been shown to have a high rate of revision surgery due to nonunion and avascular necrosis.²⁻⁶ Hip replacement arthroplasty (partial or total) is emerging as the most viable treatment option.⁷⁻¹⁰ Total hip replacement (THR) is established in osteo-arthritis and rheumatoid arthritis and has also been used as primary procedure for displaced fractures of the femoral neck.¹¹ The major drawback has been the fear of dislocation, reported to occur in 11% (0 to 18). There have been few randomised controlled trials which have compared internal fixation (IF) with THR. Despite a relatively high dislocation rate, particularly in patients with cognitive impairment,¹² THR is recommended as the primary treatment because of the low rate of reoperation and better immediate function of the hip.

Material and methods

This prospective observational study was carried out in the Department of Orthopaedics, Institute of Medical Sciences, Banaras Hindu University, Varanasi, Uttar Pradesh, India, from November 2016 to January 2018, after taking the approval of the protocol review committee and institutional ethics committee. Total 120 patients were treated with total hip replacement.

Inclusion Criteria

- Displaced Intracapsular Neck of Femur Fracture
- Patients 40-65 years of age
- Non-union Neck of Femur

Exclusion Criteria

- Young patients
- Pathological femur fractures.
- Patients with neuromuscular disorders
- Infections
- failed cancellous screw fixation
- Intertrochantric fractures and associated acetabulum fractures

In our study we have decided to evaluate the radiological outcome of both cemented and uncemented THA. We used Posterior approach in all the cases of THA and we used the second generation cementing techniques for cemented THA. Radiographic evaluation includes Loosening of the acetabulum and femoral components, Inclination of Acetabular cup, Stem position of femoral component, Vertical subsidence, Migration of the Acetabular cup and Heterotopic Ossification. Modified Harris hip score was used for clinical and functional evaluation of patients.¹³ Plain X-ray pelvis with both hips and proximal femur—AP view and X-ray of the operated hip lateral view for radiological evaluation.

Results

Total 120 patients treated with total hip replacement for displaced fracture neck of were included in this study. Regarding clinical and functional evaluation of study subjects using Harris hip score. Out of 120, 86 patients were male and 34 female, most of the patients in were above 50 year and followed by 40-50 year (Table 1). Patients scored 54.17% excellent, 26.67% good, 8.33% fair and 10.83% patients scored poor (Table 2). Observations and measurements were done on the AP radiograph of pelvis and AP/Lateral view of operated hip. The normal acetabular cup inclination is 30° to 45°. In our study 78.33% neutral, 11.67% vertical and 10% horizontal position were seen. The ideal position of stem of femoral component is central. In this study we had 76.67% central, 14.17% each in valgus and 9.16% varus position. Varus position of the stem may lead to complications such as anterior thigh pain and periprosthetic fractures. There were 3.33% subsidence and 1.67% migration seen and Class II heterotopic ossification was noted in 7 hip, i.e., 5.83% incidence who underwent THA. Out of 120, 7 patient with class II heterotrophic ossification seen. The bone marrow and debris escape when uncemented femoral implant is used however there is less chance for this when cemented implant is used. (fig.2) We had 5 case of dislocation (4.17%). The dislocation occurred during the 2nd month of the surgery at home. (Table 3).

Table 1: Demographic profile

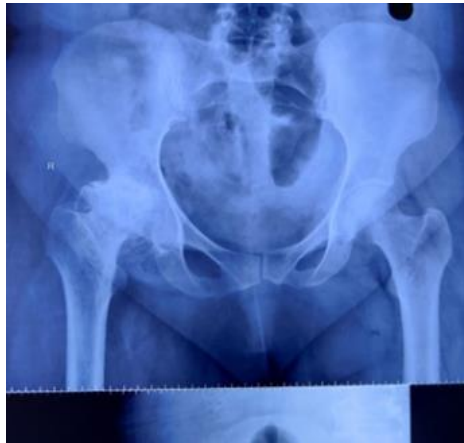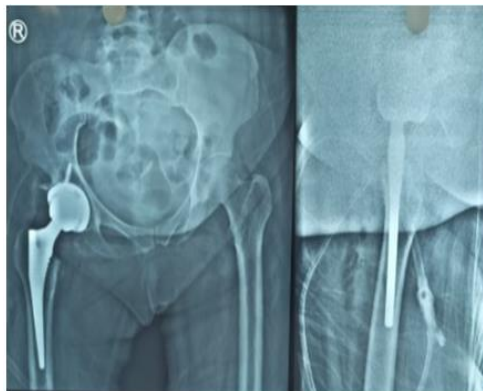
Gender	Number of patients =120	Percentage
Male	86	71.67
Female	34	28.33
Age		
Below 40 years	Nil	Nil
40-50 years	32	26.67
Above 50	88	73.33
Cemented/uncemented		
Cemented	67	55.83
Uncemented	53	44.17
Side		
Right	73	60.83
Left	47	39.17

Table 2: Clinical and functional evaluation of study subjects using Harris hip score

Harris hip score	Number of patients	Percentage
Excellent (90-100)	65	54.17
Good (80-89)	32	26.67
Fair (70-79)	10	8.33
Poor (<70)	13	10.83

Table 3: Complications

Complications	Number of patients	Percentage
Loosening of the acetabulum and femoral components	Absent	%
Acetabular cup inclination		
Normal (30-45 degrees)	94	78.33
Vertical (> 45 degrees)	14	11.67
Horizontal cup (<30 degrees)	12	10
Femoral stem position		
Central	92	76.67
valgus	17	14.17
varus	11	9.16
subsidence	4	3.33
Migration of Acetabular cup	2	1.67
Heterotopic ossification	7	5.83
Dislocation	5	4.17

**Fig.1:****Fig. 2:**

Discussion

Hip fractures in the elderly patient group result in implications in medicine, rehabilitation, psychiatry and healthcare economics. Conservative treatment is fraught with all the complications of prolonged recumbency viz. chest infections, formation of pressure sores and disuse osteoporosis. Non-operative management may be preferable for non-ambulatory, institutionalized patients with marked dementia who experience minimal discomfort within the first few days after the injury.¹ Such patients' "return to pre-injury level of function" is

better accomplished without surgery. However, early mobilization is essential to avoid the associated complications. The number of patients falling into this category is usually quite small.¹ Total hip arthroplasty, or surgical replacement of the hip joint with an artificial prosthesis, is a reconstructive procedure that has improved the management of those diseases of the hip joint that have responded poorly to conventional medical therapy. Current evidence suggests that traditional total hip replacements last more than 10 years in more than 90% of patients. More than 90% of patients report having either no pain or pain that is manageable with use of occasional over-the-counter medications. The large majority of hip replacement patients are able to walk unassisted (i.e. without use of a cane) without any limp for reasonably long distances. Like any major surgical procedure total hip replacement is associated with certain medical and surgical risks. Although major complications are uncommon they may occur.

John C and W.H. Harris¹⁴ (1999) presented a series of 188 Harris-Galante porous coated acetabular components that were followed for an average of 122 months. The hips were evaluated with Judet radiographs as well as anteroposterior and true lateral radiographs. 4% (8hips) had osteolytic lesions of the pelvis and less than 1% (1hip) had an osteolytic lesion that necessitated bone grafting.

Engh C.A. Jr et al¹⁵ (1997) reported in his series, 174 hips were followed for a minimum of 10years. A total of 7 acetabular components, i.e., 4.02% of the 174 hips were radiographically loose. 4 patients of the 174 hips had symptomatic loosening of the acetabular cup, and the cup was revised eight, nine, ten and 12 years after index arthroplasty. The other 3 hips were not revised because they were not causing any symptoms. The average duration between the index operation and the diagnosis of loosening was 7.8years. In our study there were no Loosening of the acetabulum and femoral components.

This procedure is riddled with a large number of long-term complications ranging from dislocations including recurrent dislocations. Primary endoprosthetic replacement has been advocated to improve survival by eliminating fracture fixation and healing problems and by allowing early mobilization. Conventional treatment for fracture neck of femur, grade 1 and 2, is open reduction and internal fixation, whereas, that for grade 3 and 4 is still controversial. Regarding functional outcome, our study showed that hip replacement for patient in non traumatic group had better outcome as indicated by better Harris hip score than the traumatic group. We had 5 case of dislocation (4.17%). The dislocation occurred during the 2nd month of the surgery at home. The patient was treated by open reduction and trochantric osteotomy. Another study observed increased rate of dislocation following posterior approach. His study shows dislocation rate of 2.8% following posterior approach. His findings are in concordance with our observations.¹⁶ Philips studied incidence rates of dislocation along with other parameters after elective total hip replacement and observed dislocation rate of 3.9%.¹⁷ The incidence of dislocation was highest during the immediate post-operative period but remain elevated throughout the first three post operative months. The normal acetabular cup inclination is 30° to 45°. In our study 78.33% neutral, 11.67% vertical and 10% horizontal position were seen. The ideal position of stem of femoral component is central. In this study we had 76.67% central, 14.17% each in valgus and 9.16% varus position. Varus position of the stem may lead to complications such as anterior thigh pain and periprosthetic fractures. Till the most recent review the femoral stem position has not changed in any patients. In this study there were 3.33% subsidence and 1.67% migration seen. It is seen on x-rays only 3 weeks post operatively, following THA and well defined in 6 months.¹⁸⁻²⁰ The incidence of heterotrophic ossification ranges from 5% to 90% in various literatures.^{21,22} In our study Class II heterotopic ossification was noted in 7 hip, i.e., 5.83 % incidence who underwent THA. The bone marrow and debris escape when uncemented femoral implant is used however there is less chance for this when cemented implant is used. The increased distribution of bone

debris or marrow elements locally could lead to the stimulation. In a study by William J. Maloney and William H. Harris (1991) the incidence of heterotopic ossification in an uncemented group and a hybrid group were compared. 53 uncemented and 82 hybrid (uncemented acetabular component and cemented femoral component) total hip replacements with minimum follow up of 1 year were reviewed. In the group who had uncemented hip replacement, there was a statistically significant increase in the incidence of heterotopic ossification. No relationship between the age of patient and formation of new bone was established. In our study we had 2 case of heterotopic ossification who underwent uncemented conversion THR. In a study by Ravikumar et al²³ they reviewed a total of 134 uncemented hips with average follow up of 83 months. Based on Brooker classification Heterotopic ossification was rated as Brooker Class I in 68 hips, Class II in 17 hips, Class III in 3 hips and Class IV in 2 hips, i.e., 50.7% in Class I, 12.7% in Class II, 2.2% in Class III and 1.5% in Class IV. In our study Class II heterotopic ossification was noted in 7 hip, i.e., 5.83% incidence who underwent THA.

Conclusion

We concluded that the total hip arthroplasty gave better results in displaced Intracapsular Neck of femur Fracture radiologically.

Reference

1. Holmberg S, Kalen R, Thorngren KG. Treatment and outcome of femoral neck fractures: An analysis of 2418 patients admitted from their own homes. *ClinOrthopRelat Res.* 1987;218:42–52.
2. Barnes R, Brown JT, Garden RS, Nicoll EA. Subcapital fractures of the femur: A prospective review. *J Bone Joint Surg Br.* 1976;58:2–24.
3. Parker MJ. Prediction of fracture union after internal fixation of intracapsular femoral neck fractures. *Injury.* 1994;25:3–6.
4. Parker MJ. The management of intracapsular fractures of the proximal femur. *J Bone Joint Surg Br.* 2000;82:937–41.
5. Skinner P, Riley D, Ellery J, Beaumont A, Coumine R, Shafiqhian B. Displaced subcapital fractures of the femur: A prospective randomized comparison of internal fixation, hemiarthroplasty and total hip replacement. *Injury.* 1989;20:291–3.
6. van Vugt AB, Oosterwijk WM, Goris RJ. Osteosynthesis versus endoprotheses in the treatment of unstable intracapsular hip fractures in the elderly: A randomized clinical trial. *Arch Orthop Trauma Surg.* 1993;113:39–45.
7. Davison JN, Calder SJ, Anderson GH, Ward G, Jagger C, Harper WM, et al. Treatment for displaced intracapsular fracture of the proximal femur: A prospective, randomized trial in patients aged 65 to 79 years. *J Bone Joint Surg Br.* 2001;83:206–12.
8. Rogmark C, Carlsson Å, Johnell O, Sernbo I. A prospective randomized trial of internal fixation versus arthroplasty for displaced fractures of the neck of the femur: Functional outcome for 450 patients at two years. *J Bone Joint Surg Br.* 2002;84:183–8.
9. Søreide O, Mølster A, Raugstad TS. Internal fixation versus primary prosthetic replacement in acute femoral neck fractures: A prospective, randomized clinical study. *Br J Surg.* 1979;66:56–60.
10. Sikorski JM, Barrington R. Internal fixation versus hemiarthroplasty for the displaced subcapital fracture of the femur: A prospective randomized study. *J Bone Joint Surg Br.* 1981;63:357–61.
11. Skinner P, Riley D, Ellery J, et al. Displaced subcapital fractures of the femur: a prospective randomised comparison of internal fixation, hemiarthroplasty and total hip replacement. *Injury* 1989;20:291-3

12. Johansson T, Jacobsson SA, Ivarsson I, Knutsson A, Wahlström O. Internal fixation versus total hip arthroplasty in the treatment of displaced femoral neck fractures: a prospective randomised study of 100 hips. *ActaOrthopScand* 2000;71:597-602.
13. Harris WH. Traumatic arthritis of the hip after dislocation and acetabular fractures: Treatment by mold arthroplasty. An end-result study using a new method of result evaluation. *J Bone Joint Surg Am.* 1969;51:737-55.
14. William H. Harris, John. The Harris Galante porous coated acetabular component with screw fixation. *J Bone J Surg* 1999;81-A:66-73.
15. Engh C. AJR Culpepper, W.J H and Engh. CA long term results of use of anatomic medullary locking prosthesis in total hip arthroplasty. *J Bone Joint Surg* 1997;79-A177-84
16. Goldstein WM, Gleans TF. Prevalence of dislocation after total hip arthroplasty through a poster lateral approach with partial capsulotomy and capsulorrhaphy. *J Bone Joint Surg.* 2001;83(2 suppl 1):S2 -7.
17. Phillips CB, Barrett JA, Losina E, Mahomed NN, Lingard EA, Guadagnoli E, et al. Incidence rates of dislocation, pulmonary embolism, and deep infection during the first six months after elective total hip replacement. *J Bone Joint Surg.* 2003;85- A(1):20-6.
18. Delee Jesse, Ferrari, Antonio and Charnley. John ectopic bone formation following low friction arthroplasty of hip. *ClinOrthop* 1976;121:53-7.
19. Ritter MA and Gioe. The effect of indomethacin on periarticular ectopic ossification following THA. *ClinOrthop* 1982;167:113-7.
20. Hamblen D. Ectopic ossification in complications of THR. Edited by R.S.M ling London, Churchill Livingstone 1984.
21. Chapman's orthopaedic surgery-4 th edition.
22. Rosendahl S, Christofferson J.K and Norgaaid M. Para articular ossification following hip replacement. 70 arthroplasties ad modummoore using mc Farland approach. *ActaOrthopScand* 1977;48:400-4
23. Ravikumar J Kasetti A. Shetty and C. Rand Heterotropic ossification after uncemented hydroxy appatite coated THR. *J Arthroplasty* 2001;16(8):1038-42.

Received: 07-05-2020 || Revised: 20-05-2020 || Accepted: 22-06-2020