

COMPARATIVE CHARACTERISTIC OF THE EFFECTIVENESS OF TREATMENT METHODS FOR III CLASS ANOMALIES WITH SKELETAL OPEN BITE.

S.S. Murtazaev, G.E. Aripova, J.M.Kadirov, S.R. Rasulova.

Orthodontics and Prosthetics Department of Tashkent State Dental Institute, Uzbekistan

Abstract: Edward H. Angle described III class of bite anomalies where the lower first molar is located mesially relative to the upper first molar [4,7]. This ratio may be the result of the normal location of the upper jaw and mesial skeletal location of the lower jaw or develop due to a combination of the upper jaw in retrusion and the lower jaw in protrusion. Dental relations of class III are found in persons with normal jaw relations [1,3,6]. Patients with class III anomalies usually have a concave facial profile, their lower lip often protrudes concerning the upper lip. Sometimes, the class III anomaly ratios are formed by shifting the lower jaw forward to avoid incision. This is a false form of class III anomalies. Undoubtedly, the etiological factors of class III bite disorder and oral cavity functions are influenced by environmental factors, but the causes of this phenomenon are not fully known ([1,2,5,8].

Keywords. Mesial open bite, class III anomaly, mesial occlusion, microimplant, intermaxillary rubber traction, teeth injections.

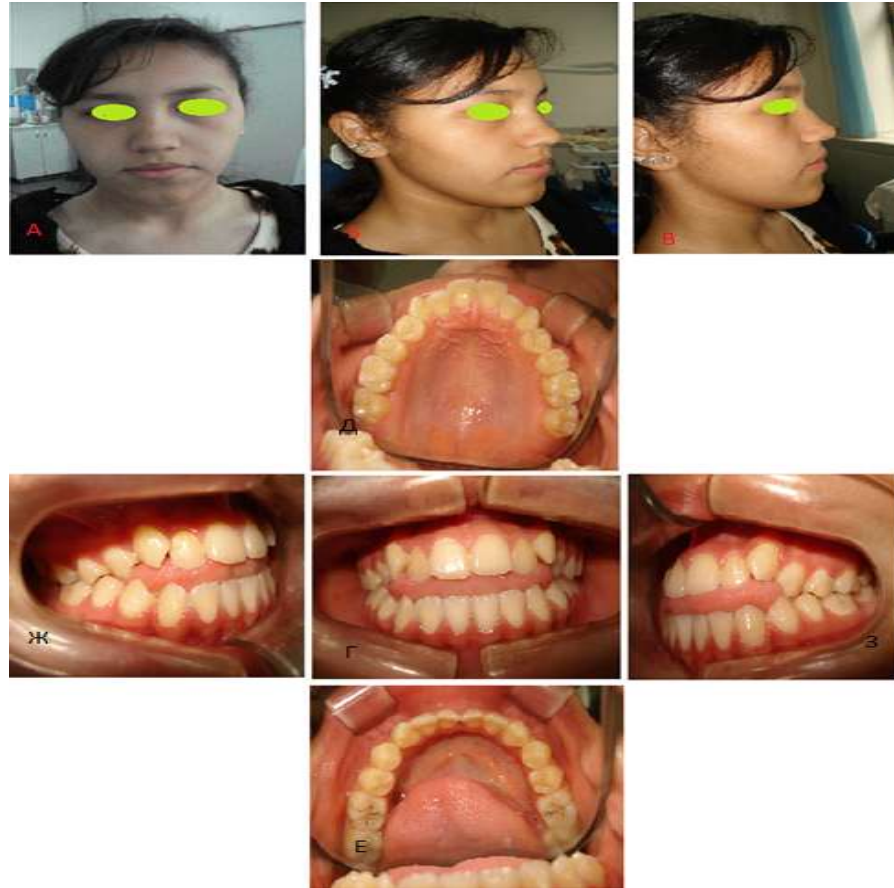Introduction.

Skeletal open bite is a complex and multifactorial anomaly. The size of such people in the vertical direction of the face also increases. Among the many causes of the open bite is pathological growth, finger sucking, airway obstruction, posture and tongue function. The open bite is a rather complex anomaly [1,6,8]. Morphological signs of an open bite are the excessively large mandibular angle and the increased height of the front part of the face, which mainly reflects the rotation of the lower jaw and excessively vertical increase in the upper jaw. All this leads to a significant disturbance of facial harmony and usually requires non-surgical treatment [1,2,8].

Materials and methods of research

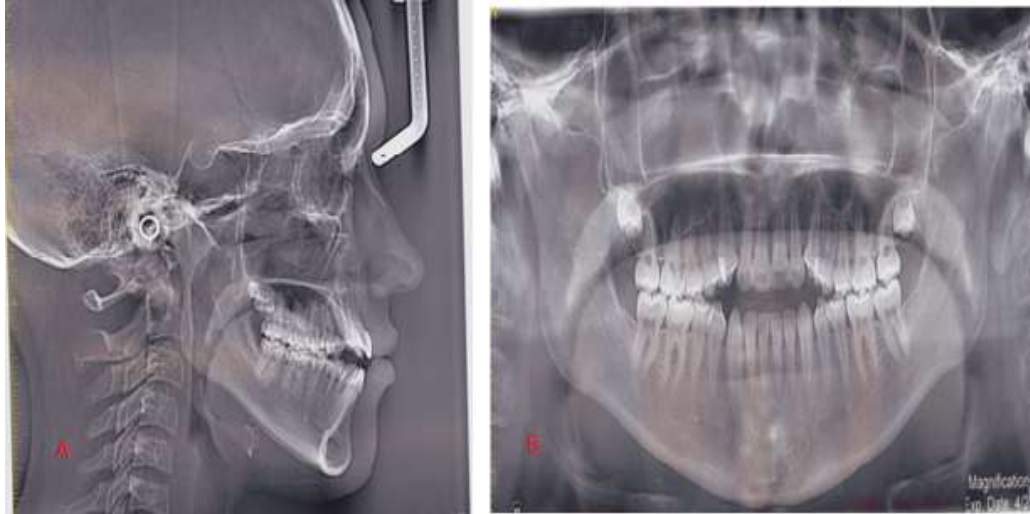
In the outpatient clinic and the Department of Orthodontics and Dental Prosthetics of the TGSI from 2005 to 2018, 39 children aged 13 to 18 years old were undergoing outpatient treatment with open-bite mesial bites, to determine the effectiveness of treatment it was decided to treat by two methods, Namely, the traditional method - brace system with intermaxillary elastics to close the vertical slit (19 children) and the proposed method - injection of extruded chewing teeth with support on microimplants (20 children).

During anamnesis collection, children complained about not closing front teeth, biting difficulties, slurred speech, and lengthening of the lower face. The facial examination revealed they had a straight profile, an elongated face, and a protruding chin, with the lower lip in front of the upper lip, and a "thimble symptom" when the lips closed on the chin. (Picture 1).



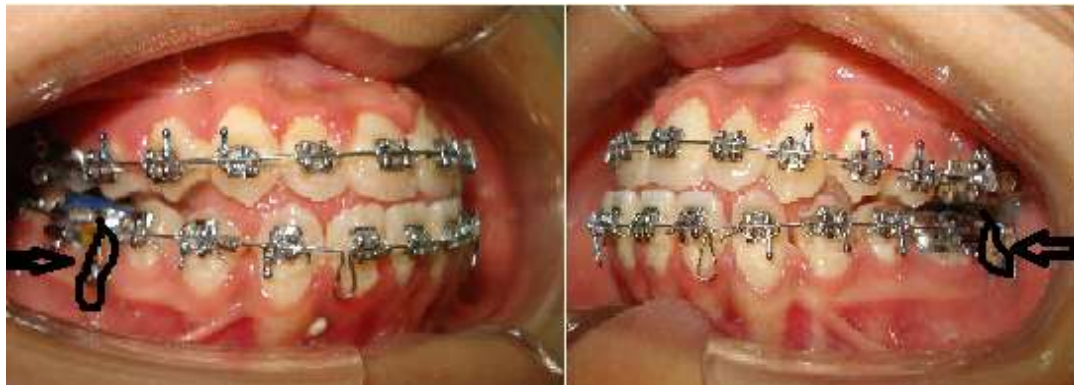Pic. 1. Pictures of the patient's face: front view (a), side view (b), in profile (c), front view of the tooth rows (d), vertical slit between the front teeth, when swallowing you can see infantile swallowing; a dystopia of canines, extrusion of chewing teeth (w, z), top and bottom view of the upper and lower rows of teeth (e, f, g), crowding of the front teeth.

When examining the face, no displacement from the median-sagittal line of the face was revealed, there were no symptoms of temporomandibular joint disorder. During the examination of the oral cavity - pale pink mucosa, the transitional fold and pulls do not have any deviations from the norm, the frenulums of the tongue and lips are normal length, cheek bumps of chewing teeth of the upper arch overlap the cheek bumps of lower chewing teeth, the ratio of the first molars and tusks to Class III Engle. In the frontal area, there is a vertical slit from 1.5 to 5 mm, as well as a reverse sagittal slit from -0.5 to -3 mm. The upper front teeth were normal or in protrusion, the lower front teeth - in retrusion. The cephalometric analysis revealed that children had a hyperdivergent facial shape with moderate skeletal anomaly class III with a small ANB angle. The lower jaw incisors were moderately lingual to compensate for skeletal sagittal divergence (Picture 2).

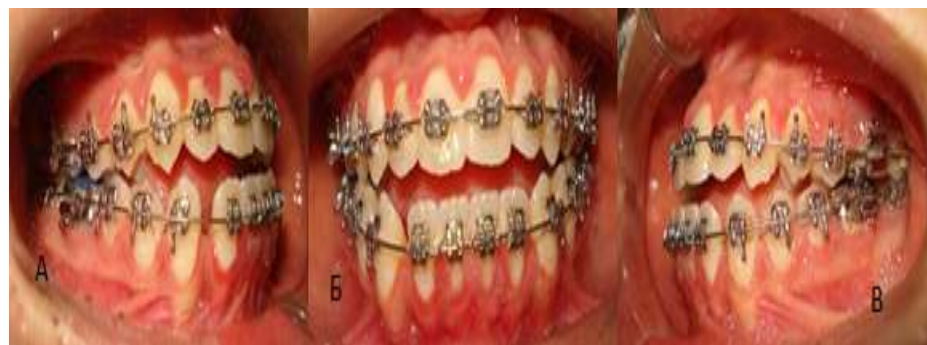

Pic. 2. Teleradiographic image of the patient with a mesial frontal open bite before treatment: chewing teeth aesthesia, vertical slit in the frontal teeth area (a), an orthopantomographic image before treatment of patient B., chewing teeth extrusion, vertical slit between the front teeth (b).

We decided to implement morphological changes, in particular the dentoalveolar compensation with an injection of upper and lower jaw molars, by placing microimplants between the first and second molars of the upper and lower jaw (creation of stationary support) and thus reducing the vertical gap between the front teeth (Picture 3a, b).



Pic. .3 a. Patient B. with a mesial frontal open bite at the stage of brace system treatment. The black arrow indicates the direction of the vertical gum from arc to microimplants.



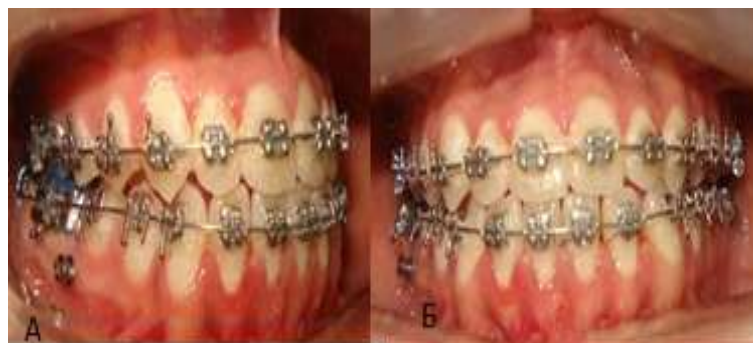Pic. 3 b. Intra-rotary pictures at the leveling stage: front view, vertical slit between the front teeth (b); on the sides, tremors between the lateral incisors and fangs, vertical slit between the front teeth (a, c).

With the traditional method of treatment, all 19 children, after thoroughly brushing their teeth, were placed in a brace system Roth, slot 0.22 x 0.25, which was fixed on both jaws.

To achieve leveling, they installed a 0.14 mm Niti arch, a 0.18 mm Niti arch after 1-2 months, and a 0.17 x 0.22 m Niti arch after 1-2 months. For the toothalveolar extension of the upper front teeth, the lower tooth arc is installed wire arc cross-section 0.18 X 0.22 SS arc, the braces on the upper tooth row are installed arc diameter 0.16 Niti. This distribution of arcs is carried out to create stationary support (steel arch mounted on the lower tooth arc is support for pulling the upper front teeth, as the upper tooth arc is installed more elastic arc) to eliminate the frontal open bite is installed intermaxillary rubber elastomers force 3/16 "6 - oz from the upper second premolar to the lower canine on the same side, it was recommended to wear rubber rings around the clock. After achieving a natural incisor overlap and achieving a molar and canine ratio of class I, elastic rubber continued to be used to secure the result. The use time of elastic rubbers was gradually reduced, and during the last three months their wearing was completely stopped. After that, orthodontic devices were removed and Hauley's retention devices were installed. Children were recommended to wear it during the whole day, the first 6 months and the next 18 months at night. The length of treatment lasted 22-24 months.

The treatment method with an infusion of chewing teeth with support on microimplants. Patients initially tried on orthodontic rings as standard on the first molars of the upper and lower jaw. In their absence, second premolars and molars were used. After achieving a good fixation of the rings, impressions were taken from both jaws to make celestial and lingual arches. When making the palatine arc, the technician left a space of 2.5 mm between the arc and the mucous membrane of the sky. The orthodontic constructions made by the technician, rings with the sky and lingual arc were fixed on the glass ionomer cement, and then the braces of Roth system were fixed on both jaws by 0,22x0,25 slot.

To achieve levelling, a 0.14 mm Niti arc was installed, a 0.18 mm Niti arc was installed after 1-2 months, a 0.17 x 0.22 mm Niti arc and a 0.18 x 0.22 mm SS arc were installed after 1-2 months. At the end of the leveling stage, having determined the location of microimplants, four microscopic screws were installed in the alveolar process between the first and second molars perpendicular to the cortical plate of the alveolar process. In the levelling stage, small forces were applied directly to the molars on both sides of the upper jaw, connecting an elastic chain between the molar cheek tubes and microimplants (the elastic chain took the form of a V) (Picture 4a, b). The palatine and lingual arcs prevented the cheek bend of chewing teeth.



Pic.4. Intra-oral pictures during 15 months of treatment, insignificant incisal overlapping (a, b) was achieved.

Results and discussions.

The angle (SNA) determining the position of the upper jaw with the front part of the base of the skull in the control group before the treatment was $83.7 \pm 2.11^\circ$, after the therapy, it was $84.2 \pm 2.93^\circ$, also, in our group with the proposed method of treatment, the same indicator before the treatment was $84.0 \pm 1.39^\circ$, after the therapy, it was $84.7 \pm 2.27^\circ$, from the results it can be seen that there was a slight movement of the upper jaw with the front part of the base of the skull. The angle (SNB), indicating the location of the lower jaw with the front part of the base of the skull in the control group of children before the treatment was $81.9 \pm 1.91^\circ$, and after the therapy was $83.1 \pm 0.94^\circ$, there was a significant increase in the values (lower jaw movement) during the treatment - ($P < 0.05$), also, in the group treated according to our method, the index before the treatment was $82.4 \pm 0.29^\circ$ after the therapy was $85.1 \pm 4.31^\circ$. From clinical observations and measurement results, it was revealed reliably lower jaw movement in the group of children, where micro-implants ($P < 0,05$) were used for treatment. Changes between the front contours of apical jaw bases, in children in the control group at the beginning of treatment the index was $1.8 \pm 0.09^\circ$, after therapy the same index was $1.1 \pm 0.02^\circ$, there was a significant decrease in the difference between the front contours of apical jaw bases - ($P > 0.05$). The same tendency was observed in the group with the proposed treatment, before the treatment, it was $1,6 \pm 0,42^\circ$, after the treatment, it was $0,6 \pm 0,012^\circ$. The reliable decrease of values ($P > 0,05$) was revealed, when comparing the results of treatment between the groups, there was more movement in the group with micro-implants than in the traditional group ($P < 0,05$). The distance on the occlusal plane between points AO-BO in the control group before treatment was 1.9 ± 0.02 mm, after treatment was -0.9 ± 0.02 mm, in the group with micro-implants, before treatment the distance between points AO-BO was 2.7 ± 0.44 mm, after treatment -1.4 ± 0.06 mm. The revealed negative value after the treatment indicates an anticlockwise turn of the lower jaw. The angle between the spinal and occlusal planes is denoted as FMA, at the beginning of treatment in children in the traditional group this index was $32.4 \pm 1.61^\circ$, after the therapy it was $31.3 \pm 0.82^\circ$, this indicates a tendency to reduce the distance between the planes by 3.3%, also in the treatment group on the proposed angle decreased by 4.6%. UOP is the upper occlusal plane, it is a plane formed from the top of the mesial cheek bump of the upper first primary tooth to the cutting edges of the upper central incisors. In the traditional group before the treatment, this index was $6,4 \pm 0,14^\circ$, after the treatment it was $7,7 \pm 0,21^\circ$, the distance between occlusal planes increased by 16,8%, in the group with microimplants the value before the treatment was $7,2 \pm 0,40^\circ$, after $9.2 \pm 0.61^\circ$, there was an increase in the distance between occlusal planes by 21.7%, analyzing these values we can see that the distance between the planes in the group of treated according to the proposed method, which is effective by 4.9%.

The total front facial height, this is the distance from N point to Me point, in children with the traditional method, before the treatment, this Picture was 121.4 ± 2.41 mm after the treatment was 120.7 ± 3.2 mm, the change was 0.5%, and with the use of micro-implants, the positive change was 1.5%, because, before the treatment, the Picture was 120.9 ± 2.1 mm, after the treatment was 119.2 ± 1.43 mm. The lower front facial height, this is the distance from ANS point to Me point, in children with traditional treatment, the pre-treatment rate was 67.8 ± 0.29 mm after the value was 66.9 ± 0.81 mm, there was a decrease of 0.9 mm between points, in the group with microimplants, the distance between ANS-Me points before treatment was 66.1 ± 0.21 mm, after the treatment 63.6 ± 0.35 mm, the distance between ANS-Me points was reduced by 2.5 mm, this means 1.6 mm, the distance was reduced more than in the group with traditional treatment. U1 to FH is the angle of inclination of the upper central incisor to the horizontal plane, in the group with the traditional treatment method the initial data were $114,3 \pm 2,8^\circ$, after moving $119,6 \pm 4,6^\circ$, there was an increase in the incisor inclination by 5, 3°, and in children with the method of treatment offered by us, the index before treatment was $113.2 \pm 1.90^\circ$, after the therapy it was $117.5 \pm 0.83^\circ$, the upper front teeth were inclined towards the lip by 4.3°, the reliability was $P < 0.05$. The angle of inclination of the lower central incisors to the plane of the lower jaw base in children with the

traditional method of treatment before the treatment was $87.2 \pm 2.1^\circ$, after the treatment it became $88.6 \pm 0.41^\circ$, there was a restoration of the angle of inclination of the lower central incisors by $1,4^\circ$, with the method of treatment with the use of micro-implants, the inclination angle of the lower central incisors was $86.3 \pm 0.45^\circ$, after the therapy, the value was $89.5 \pm 0.30^\circ$, the inclination angle of the lower central incisors was restored by 3.2° . Aesthetics angle according to "McNamara" in children with the traditional method of treatment before the treatment was $71,4 \pm 0,82^\circ$, after the treatment it was $72,2 \pm 1,21^\circ$, there was a reliable change in soft tissues of the lower jaw ($P < 0,05$) (Table 1).

Table 1

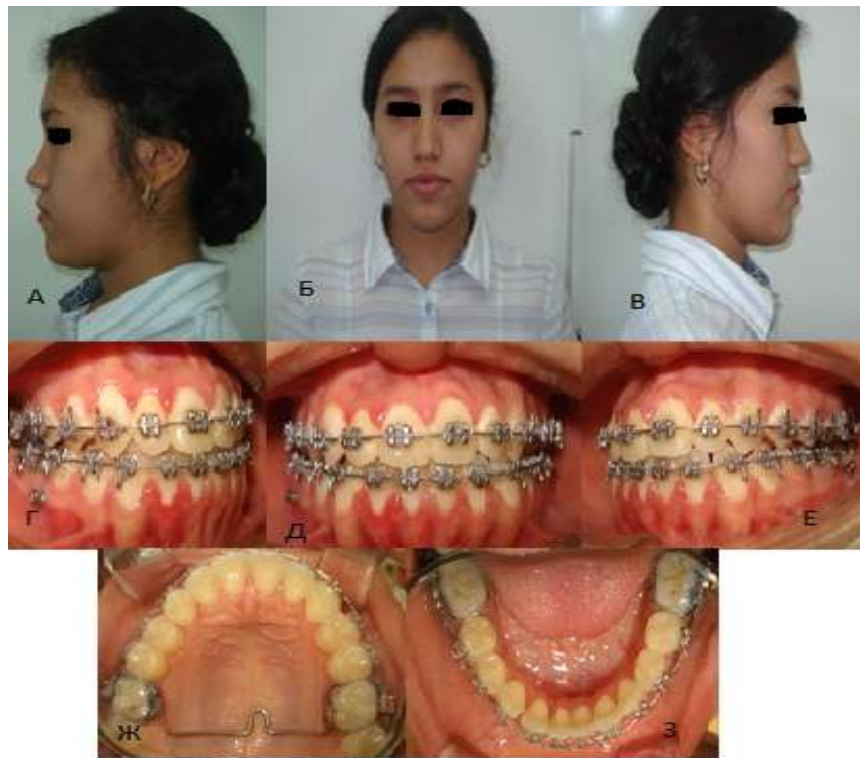Comparative X-raycephalometric indicators of the effectiveness of treatment methods for children with mesial open bite (M±m).

Indicators	Traditional method (intermandibular elastics) n-19 before treatment	Traditional method (intermandibular elastics) n-19 after treatment	The proposed method (microimplant support) n- 20 before treatment	The proposed method (microimplant support) n- 20 after treatment
SNA ^o	83,7±2.11	84,2±2.93	84,0±1,39	84,7±2,27
SNB ^o	81,9±1.91	83,1±0.94*	82,4±0,29	85,1±4,31^
ANB ^o	1,8±0.09	1,1±0.02*	1,6±0,42	0,6±0,012*^
AO-BO, MM	1,9±0.02	-0,9±0.02*	2,7±0,44^	-1,4±0,06*^
FMA ^o	32,4±1.61	31,3±0.82	34,4±1,76	32,8±1,32
UOP ^o	6,4±0.14	7,7±0.21*	7,2±0,40^	9,2±0,61*^
POP ^o	15,8±0.82	14,6±0.66	15,5±0,43	14,7±0,38
U1 toFH ^o	114,3±2.8	119,6±4.6*	113,2±1,90	117,5±0,83*
L1 toMP ^o	87,2±2.1	88,6±0.41	86,3±0,45	89,5±0,30
Z angle ^o	71,4±0.82	72,2±1.21*	71,6±0,48	73,3±0,27
Facialangle ^o	85,4±2.21	85,9±1.46	86,3±0,29	88,8±0,23
Angleofconvexity ^o	2,8±0.14	1,2±0.02*	3,2±0,13^	0,1±0,01*^
A-B plane to facial plane ^o	1,4±0.08	1,8±0.04*	1,5±0,06	2,2±0,11*^
Y axisangle ^o	61,8±0.82	60,9±1.41	62,4±0,18	61,5±0,25
Occlusal plane to F.H. plane	11,9±0.62	10,4±0.19	11,2±0,30	8,7±0,19*^
Na-perp to point A (mm)	-1,9±0.04	-1,4±0.06	-2,1±0,14	-1,6±0,08*
ANS-Me (mm)	67,8±0.29	66,9±0.81	66,1±0,21	63,6±0,35
N-Me (mm)	121,4±2.41	120,7±3.2	120,9±2.1	119,2±1.43

Note: * - $P < 0,05$ reliability of differences in comparison with data before treatment; ^ - $P < 0,05$ reliability of differences in the comparison between groups

In treated children, according to the method we propose, the pre-treatment parameters were $71.6 \pm 0.48^\circ$; after the therapy they were $73.3 \pm 0.27^\circ$. In class III anomalies with mesial frontal open bite, in the removal of frontal open bite with extrusion of chewing teeth is a reduction in the distance between the points ANS-Me, N-Me and the angle of the FMA, due to this occurs anticlockwise rotation of the lower jaw and chin extension.

After 16 months of intrusion of molars with intermandibular elastics and total distalization of the lower jaw with elastics of class III, an orthognatic bite with normal overlap of the front teeth was obtained (Picture 4 a, b).

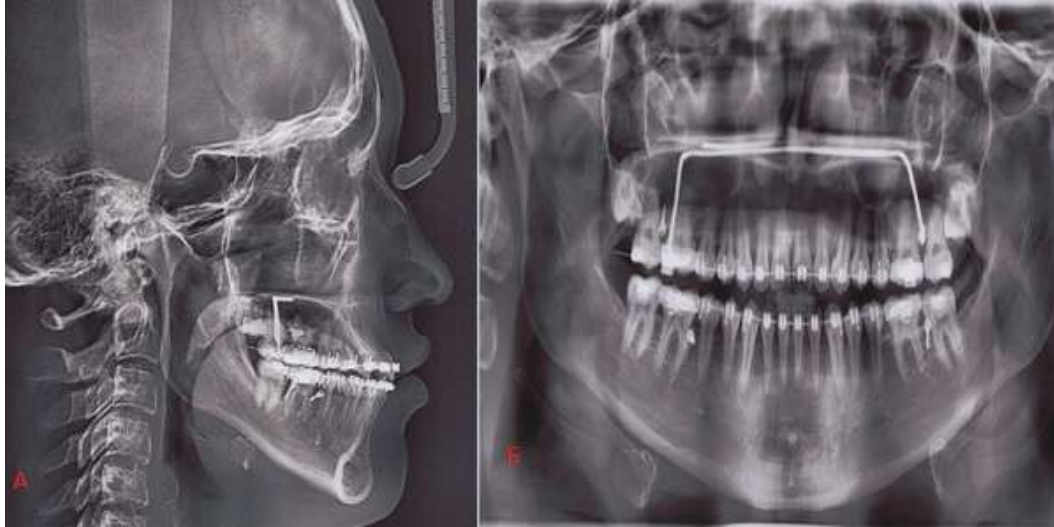


Pic. 5. Patient's front view after the treatment (a), face view on the sides after the treatment (b, c), incisal overlap reached (e), the view of the occlusion on the sides, the ratio of tusks in class I (d, f), the view from above the upper and lower arch of the tooth, crowding between the front teeth is eliminated (w, z).

The final stages included a 0.18 round stainless steel arc on the lower jaw and a 0.19x0.22 rectangular TMA arc on the upper jaw; elastic rubber was used to deepen the bite and fix the improved anterior to the rear ratio. The use time of the elastic bands has been gradually reduced and they have been completely discontinued during the last three months. The duration of active treatment was 18-20 months (Picture 5 a-z). After the removal of orthodontic apparatuses, fixed retainers were installed on the upper and lower jaws from canine to canine, and a removable Hawley retainer plate was installed on the upper tooth row.

The intraoral images show a good tooth row and class I for tusks and molars. The orthopantomogram shows good parallelism of the roots of the teeth and no root resorption.

Cephalometric images taken before and after treatment showed that children's maxillary and mandibular molars were intruded (Picture 6).



Pic. 6. Teleradiographic image after treatment, lipstick closure normalized, incisal overlapping achieved (a), orthopantomographic image after treatment, chewing teeth extrusion occurred, tooth roots in natural state (b).

Thus, the angle (SNB), indicating the location of the lower jaw with the front part of the base of the skull in children in the control group before the treatment was $81.9 \pm 1.9^\circ$, and after the therapy was $83.1 \pm 0.94^\circ$, there was a significant increase in the values (lower jaw movement) during the treatment - ($P < 0.05$), also, with the proposed treatment method, the index before the treatment was $82.4 \pm 0.29^\circ$ after the treatment was $85.1 \pm 4.31^\circ$.

From clinical observations and measurement results, we have revealed a reliably bigger movement of the lower dental arch during the treatment of the methods offered by us ($P < 0.05$). Changes between the front contours of apical jaw bases, in children in the control group at the beginning of treatment the index was $1.8 \pm 0.09^\circ$, after the therapy the same index was $1.1 \pm 0.02^\circ$, there was a reliable decrease in the difference between the front contours of apical jaw bases - ($P > 0.05$). The same tendency was observed in the group with micro-implants, before treatment it made $1.6 \pm 0.42^\circ$, after therapy, it became $0.6 \pm 0.012^\circ$, a reliable decrease of values ($P > 0.05$) was revealed, at the comparison of results of treatment between groups they revealed reliably greater movement in the group with micro-implants, than in the traditional group ($P < 0.05$). The angle between the spinal and occlusal planes is designated as FMA, at the beginning of treatment in children in the traditional group this index was $32.4 \pm 1.61^\circ$, after treatment it was $31.3 \pm 0.82^\circ$, it can be argued about the tendency to reduce the distance between the planes by 3.3%, also in the group of treatment proposed by our method the angle decreased by 4.6%. UOP is the upper occlusal plane, it is a plane formed from the top of the mesial cheek knuckle of the upper first root to the cutting edges of the upper central incisors. In the traditional group before the treatment this index was $6.4 \pm 0.14^\circ$, after the treatment it was $7.7 \pm 0.21^\circ$, the distance between occlusal planes increased by 16.8%, in the group according to the proposed method of microimplant treatment the value before the treatment was $7.2 \pm 0.40^\circ$, after the treatment was $9.2 \pm 0.61^\circ$, there was an increase of the distance between the occlusal planes by 21.7%, analyzing these values we can see that the distance between the planes in the group according to the proposed treatment method is reduced effectively by 4.9%.

The total front facial height, this is the distance from N point to Me point, in children with the traditional method, before the treatment, the Picture was 121.4 ± 2.41 mm after the treatment was 120.7 ± 3.2 mm, the change was 0.5%, and the treatment using our method with micro-implants, the

positive change was 1.5%, before the treatment the Picture was 120.9 ± 2 mm after the treatment was 119.2 ± 1.43 mm. The lower front facial height, this is the distance from ANS point to Me point, in children with traditional treatment method, the index before the treatment was 67.8 ± 0.29 mm after the treatment was 66.9 ± 0.81 mm, there was a reduction of 0.9 mm distance between the points, in the group of treatment with micro-implants, In children, the distance between ANS-Me points before treatment was 66.1 ± 0.21 mm, after treatment it was 63.6 ± 0.35 mm, the distance between ANS-Me points decreased by 2.5 mm, this means 1.6 mm, more distance was reduced than in the group with the traditional method of treatment. The duration of treatment in the group with the traditional method of treatment was 20-22 months, in the group with the method we offer was 18-21 months.

Conclusions

The application of the method of treatment we have offered has allowed us to improve:

1. The location of the lower jaw with the front part of the skull base;
2. Reduce the angle between the spinal and mandibular planes;
3. Restore the rear occlusal plane to its natural position;
4. Significantly reduce the front face height;
5. Shorten the duration of treatment and improve facial aesthetics.

Summary

In the outpatient clinic and the Orthodontics and Dental Prosthetics Department, there were 39 children aged 13 to 18 years old with mesial open bite using two methods, the traditional method - brace system with intermaxillary elastics and the proposed method - injection of extruded chewing teeth with support on micro implants (20 children). At the end of treatment, the FMA angle decreased by 1.3% more in the group of children treated by our method. The total front facial height in children treated according to our method was 1.0% more effective. The duration of treatment was reduced and facial aesthetics were improved.

References

1. Anikienko A.A., Kamysheva L.I. Comparative characteristics of the intensity of age-related changes in the upper and lower jaws in distal and mesial occlusion // *New in dentistry*. - 1997. - No. 1, special issue - pp. 12-16.
2. Arutyunov S.D. Correlation of radio-cephalometric parameters of the gnathic part of the skull with anthropometric indices of dental rows and data of functional examination in persons with physiological occlusion of dental rows // *Dentistry*. - 2001. - №5. - pp. 40-46.
3. Vodolatskiy M.P. Elimination of lower macrognathicity in children and teenagers // *Dentistry 2001: Ros. scientific forum with international participation*. - M., 2001. - pp. 311-317.
4. Pankratova N.V., Slabkovskaya A.B. Sagittal dimensions and interposition of apical jaw bases in patients with distal and mesial occlusion // *Dentistry 2000: Collection of the thesis of the international scientific conference* - M., 2000. - pp. 44-45.
5. Katsaros C., Berg R. Anterior open bite malocclusion: a follow-up study of orthodontic treatment effects // *Europ. J. Orthod.* - 1993. - Vol. 15. - P. 273-280.

6. Janson G., Valarelli F.P., Henriques J.F.C. et al. Stability of anterior open bite nonextraction treatment in the permanent dentition // *Amer. J. Orthod. Dentofacial. Orthop.* – 2003. – Vol. 124. – P. 265-276.
7. Kuroda S., Sakai Y., Tamamura N. et al. Treatment of severe open bite with skeletal anchorage in adults: comparison with orthognathic surgery outcomes // *Amer. J. Orthod. Dentofacial. Orthop.* – 2007. – Vol. 132. – P. 599-605.
8. Kuroda S., Katayama A., Takano-Yamamoto T. Severe anterioropen-bite case treated using titanium screw anchorage // *Angle Orthod.* – 2004. – Vol. 74. – P. 817-824.