

## **Protective effects of Celery extracts on hepatic tissues in rats consumed a concentrated feed**

**Ali A. Tala'a<sup>1</sup>, Yousif R. Jumaah<sup>1</sup>, Lubna Dhari Mohammed<sup>2</sup>, Marwa Raad Jead<sup>3</sup>, P. Saranraj<sup>4</sup>**

<sup>1</sup> University of Fallujah, college of veterinary Medicine

<sup>2</sup> Gilgamesh Ahliya University

<sup>3</sup> University of Baghdad

<sup>4</sup>Department of Microbiology, Sacred Heart College (Autonomous), Tirupattur, Tamil Nadu, India.

### **Abstract:**

**The purpose of this work was to investigate the celery extract's safety impact on liver rats' tissues feeding concentrated diet. A total of 40 rats, randomly divided into 4 groups, each group consists of 10 rats, G1 given normal diet, G2 given concentrated feed diet only for 30 days, G3 given Celery extract 20% of the diet only for 30 days, G4 given concentrated feed diet plus celery extract 20 % of the diet for 30 days. Data from G1, G3 shows that analysis of regular (negative control -ve) livers of rats fed with basal diet or celery 20 per cent provide a normal histologic representation of the liver lobules and normal hepatocytes, whereas the rat's liver fed with a concentrated diet displaying a hepatocyte vacuolar degeneration and hepatocyte fatty degeneration. Furthermore, the testing of rat livers fed with celery-added diet at 20% shows only moderate fatty hepatocyte degeneration. In conclusion, receiving of celery at 20% can lowered the cases of fatty liver and can protect the liver from hydropic degeneration.**

**Key words:** Liver, celery, rat, concentrated feed

### **Introduction:**

The celery is an essential salad plant composed of bulbous roots, green leaves and the stem, leaves which are sprouting directly from the flesh roots (Dobelis ,1986). Celery is a really fine simple food. It is one of the better mineral salts sources of sodium, chlorine and vitamins (Blish, 1972).

A study of celery leaves indicates 88 percent of moisture and 3-6 percent of protein (Blish, 1972). The traditional celery taste is induced mainly by the two lactones (Claus and Hoppen ,1979) 3-butyl- 4,5 dihydrophthalide and 3-butylphthalide 1.5-3% , volatile oil that containing the limonene, terpenes, phthalides b- and selinene; coumarins (seselin , celerin, osthencl , umbelliferone and apigravin) ; furanocoumarins ( bergapten ) ; tannin , flavonoides , fixed oil , cholin , steriod , fatty acid, ascorbate , and un identified alkaloids, also contain phenolic composite in a different kinds and concentrated concentration , it's also contain alpha-linolenic acid , beta – eudesmol , boron , magnesium ,calcium , iron , chlorophyll , siliat-N-butyl-phthalide , gualacol , vitamins (A,B,C) (Zobel and Wang, 1991 ) .

Celery is beneficial for lowering blood cholesterol level as a consequence of lipase hepatic triacylglycerol ( HL) inhibition and increasing bile acid secretion. (Tsi, 1995; Tsi and Tan, 1997). Due to its concentrated sodium, the organic sodium helps to resist or alleviate the alkaline part, and celery eliminates the acidic weight, the sodium is useful in the treatment of arthritis. Therefore, acidity, toxemia, rheumatism and gout disorders are very successful (Hoppe, 1975).

This work was planned to determine the cellular extract safety impact of rat's liver feeding a concentrated diet.

### **Materials and Methods:**

A total of 40 rats were divided randomly into 4 groups, 10 rats per group:

G1 given normal diet

G2 given concentrated feed diet only for 30 days

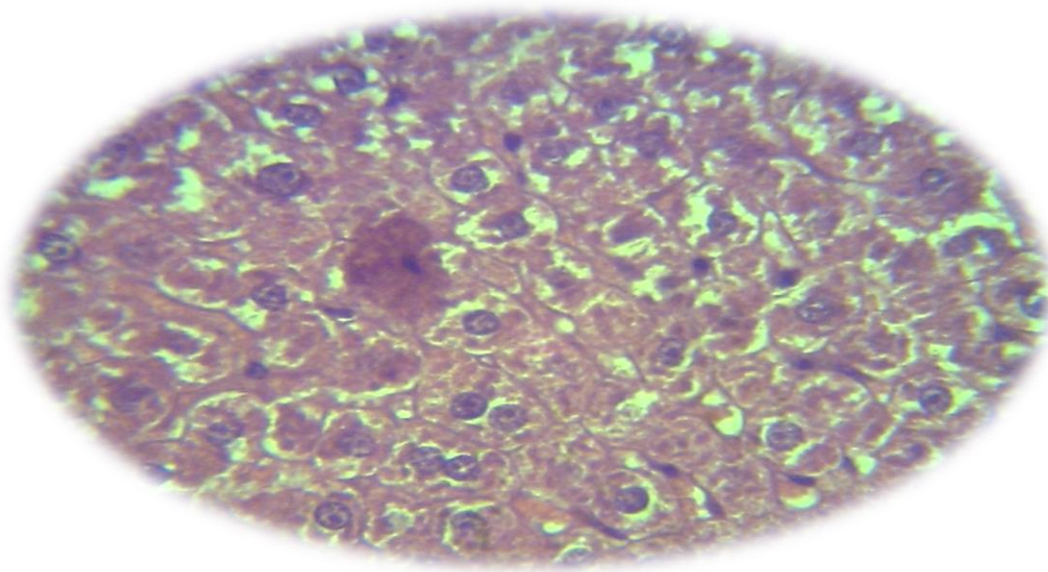
G3 given Celery extract 20% of the diet only for 30 days

G4 given concentrated feed diet plus celery extract 20 % of the diet for 30 days

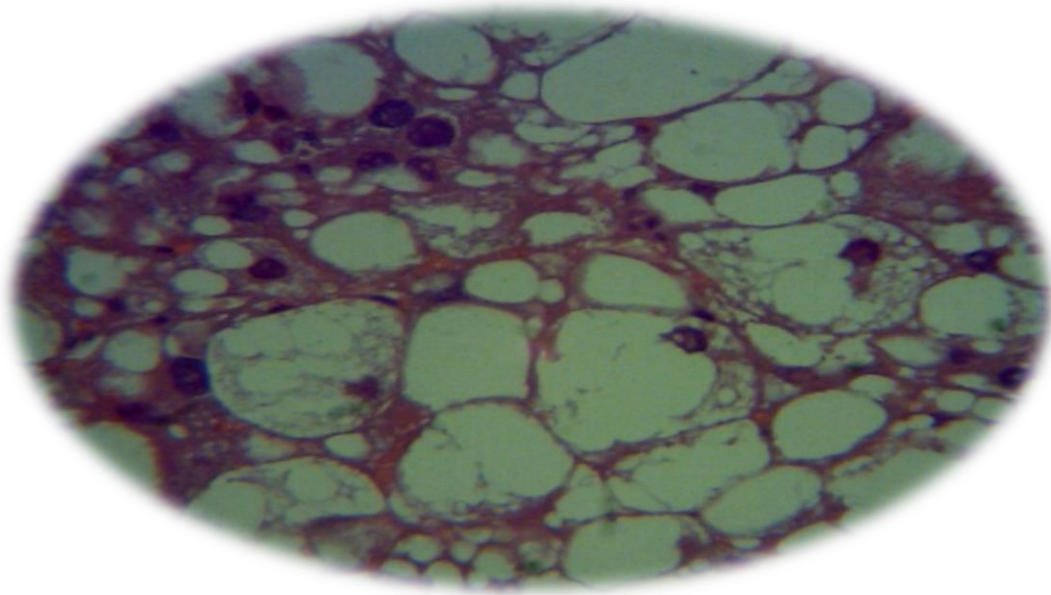
The preparation of the crude extracted of celery leaves was done according to the method of (Harborne, 1984).

### **Results:**

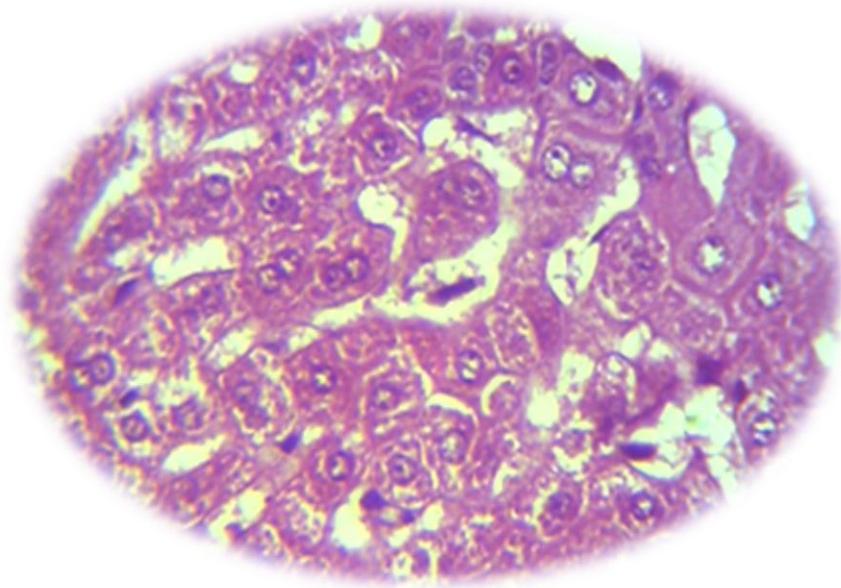
Examination of regular (negative control -ve) rats feeding on basal diets, or celery 20% shows the normal histological image of hepatic lobules and normal hepatocytes in G1 and G3. (Figure 1, 3). Livers of rats fed on concentrated diet showed a hepatocytes with vacuolar degeneration and fatty degeneration of hepatocytes (figure 2). Examination of livers of rats fed on concentrated diet with celery 20 % presented the hepatocytes with a slight fatty degeneration (figure 4).



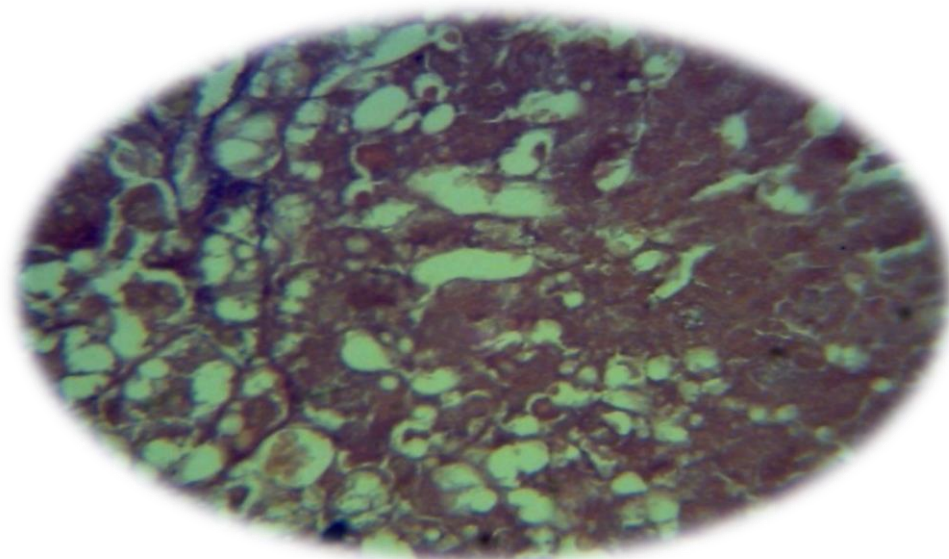
**Figure 1. Histological section in the liver of showed normal architecture in G1 (H&E 40X)**



**Figure 2. Histological section in the liver of G2 received concentrated feed diet for 30 days, showed fatty changes (H & E 40 X)**



**Figure 3. Histological section in the liver of G3 received celery extract for 30 days, showed Kupffer cell proliferation (H & E 40 X)**



**Figure 4. Histological section in the liver of G4 received concentrated feed diet plus celery extract for 30 days, showed moderate vacuolation (H & E 40 X)**

#### **Discussion:**

celery containing a high source of vitamin C. The dietary fibre, potassium, folate, manganese and vitamin B6 come from a really strong source. Celery is also contains calcium, B1, phosphorus, magnesium, iron, vitamin A, vitamin B2 (Mitra *et al.*, 2001).

A drinking of 8 weeks of aqueous celery extract induced a substantial decrease in the amount of total serum cholesterol (TC) in rats; the various celery extracts effectively decreased the high serum levels of enzymes ALT, AST and ALP. Celery also provides vitamin C that is a well-known promoter of immune systems and lowers the body's free radicals. The risk of asthma, inflammation and rheumatoid arthritis is also decreased (Tsi and Tan, 2000).

The current work results about the efficiency of celery was agreed with Kim and Shin, (1998) who has been shown that this natural product can mediate its lipid-lowering effect through inhibition of biosynthesis of the hepatic cholesterol, rising excretion of faecal bile acids and improved plasma lecithin: cholesterol acyltransferase activity and lowered lipid absorption into the gut. (Mansi *et al.*, 2009).

A strong liver-protective effect for the celery seed methanol extract in a single dose of paracetamine or thioacetamide that had been documented to cause liver damage (Singh and Handa , 1995)

Biochemical parameter affected by celery root and leaf juices and exhibited antioxidant effects in Wistar rats when they were applied with doxorubicin. Serum lipid peroxidases (LPx) have been minimized by celery leaf juice alone or doxorubicin alone, whereas celery root and leaf juices have improved xanthinum oxidase activities (XOD), CAT and GPx (Kolarovic *et al.*, 2008).

An animal model was used to investigate the probable effect of celery juice in the reduction of oxidative stress and hepatotoxic symptoms produced by lead-acetate and gamma-radiation toxicity. The intake of celery juice has encouraged a substantial decrease in TBARs and PCCs as well as a spike in CAT, GSH, and SOD, suggesting that antioxidant safety functions in rats have been improved (Osman, 2013)

In addition to this, a dry powder celery leaf diet decreased the hypercholesterolemia, liver enzymes and blood lipids in rats. The lesions of rats' liver have also been reduced. This study indicates that celery diet can be useful for hypercholesterolemia and hepatic disease patients (Belal, 2011).

### Conclusion:

Receiving of celery at 20% can lowered the cases of fatty liver and can protect the liver from hydropic degeneration.

### References:

- Belal NM. (2011) Hepatoprotective effect of feeding celery leaves mixed with chicory leaves and barley grains to hypercholesterolemic rats. *Asian Journal of Clinical Nutrition*, 3, 14-24.
- Blish , J. ( 1972 ) Dictionary of health Foods .Los Angeles : Nash publishing .
- Claus, R. and Hoppen, H.O.( 1979 ) .The Boar-pheromone Steroid Identified in vegetables . *Experientia* . , 35(12):1674 .
- Dobelis ,I.N.(1986). *Magic and Medicine of plants*, Pleasantville , NY : Readers Digest Assoc .INC.
- Harborne, J. B. ( 1984 ) . *Phytochemical methods . A guide to modern techniques of plant analysis* . Chapman and Hal Ltd. London ., : 116 – 117 .
- Hoppe,H.A.(1975) . *Drogen Kunde , Band 1, Angiosperm an ,8. Auflage* . walter de Gruyter and Co ., Berlin , Germany .56.
- Kolarovic J, Popovic M, Mikov M, Mitic R, Gvozdenovic Lj. (2009) Protective effects of celery juice in treatments with doxorubicin. *Molecules*, 14, 1627-1638.
- Mansi, K., Abushoffa, A. M., Disi, A., & Aburjai, T. (2009). Hypolipidemic effects of seed extract of celery (*Apium graveolens*) in rats. *Pharmacognosy magazine*, 5(20), 301.
- Mitra, S. K., Venkataranganna, M. V., Gopumadhavan, S., Anturlikar, S. D., Seshadri, S. J., & Venkatesha Udupa, U. (2001). The protective effect of HD-03 in CCl4-induced hepatic encephalopathy in rats. *Phytotherapy Research*, 15(6), 493-496.
- Osman N. (2013) The role of antioxidant properties of celery against lead acetate induced hepatotoxicity and oxidative stress in irradiated rats. *Arab Journal of Nuclear Sciences and Application*, 46, 339-346.
- Singh A, Handa SS. (1995) Hepatoprotective activity of *Apium graveolens* and *Hygrophila auriculata* against paracetamol and thioacetamide intoxication in rats. *Journal of Ethnopharmacology*, 49, 119-126
- Tsi, D. (1995) . Effects of aqueous celery (*Apium graveolens* ) extract on lipid parameters of rats fed ahigh fat diet . *Plant Med* ., 61:18-21 .
- Tsi, D. and Tan, B.K.H. (1997) . Lipid-lowering activity of aqueous celery extract and its fractions in hypercholesterolaemic rats and mice . *Medical science Research* ., 25(10) :673-675 .
- Tsi, D., & Tan, B. K. (2000). The mechanism underling the hypocholesterolemic activity of celery extracts (aqueous and butanol extracts) in genetically hypercholesterolemic (RICO) rats. *Life Sci*, 14, 755-767.
- Zobel,A.M. and Wang,J.(1991).Identification of eight coumarins occurring with psoralen , xanthotoxin , and bergapten of leaf surface. *Journal of Chemical Ecology* ,17:1859-1870.