

Perosseous osteosynthesis and bone plasty in the patient treatment with an open fracture of the femur with an extensive bone defect. (CASE FROM PRACTICE)

Davirov Sharof Madjidovich¹, Urinboev Payzulla Urinboevich²

¹orthopedic traumatologist, Samarkand branch of Republican specialized scientific-practical medical center of traumatology and orthopedics, Samarkand, Uzbekistan.

²Doctor of medical sciences, professor of “Traumatology and orthopedics” department, SSMI.

e-mail: sharofd1976@mail.ru

Introduction. The treatment complexity and patients' rehabilitation with an open comminuted femoral fracture, with an extensive bone defect, is due to an increased risk combination of developing infectious complications due to the wound openness, with the need to restore a significant volume of bone tissue, for the proximal and distal fragments of the femur connection.

Open extramedullary or intramedullary osteosynthesis of bone fragments using metal implants is impossible in such cases due to the lack of the required bone tissue volume necessary to restore the normal bone length. In cases of open reduction, immediately after injury, there is a high probability of developing soft tissue necrosis, infectious complications, inflammatory and purulent-septic processes, as a result of the negative effect of early reduction on the blood supply of an already severely damaged limb. Difficulties arise with maintaining the limb length.

The article describes a patient treating experience with an open femur fracture with an extensive defect in bone tissue, using external fixation in the early period with delayed plasty defect with autologous bone.

The aim is to demonstrate a successful treatment case of a patient with an open femur fracture with an extensive defect in bone tissue, while maintaining the limb length.

Results and discussion. A 22 cm long fibula was taken, two fragments were formed and they were installed in pairs. The periosteum and muscle segments are preserved on the graft surface. It was performed femur perosseous osteosynthesis with a wire-rod apparatus with femur bone defect replacement of paired autologous bone. The limb function was restored satisfactorily, the anatomical segment length was preserved, all fixation structures were removed, and the limb did not contain foreign bodies.

Conclusion. The various techniques and technical combination facilities, external fixation, autotransplantation according to the classical technique, made it possible to

completely restore the injured limb, reduce the complications risk, and obtain a good clinical result.

Key words: femur injury, open fractures, bone tissue defect, autologous bone, perosseous osteosynthesis, combination of techniques.

1. INTRODUCTION.

The replacing extensive defects problem of long bones is relevant for reconstructive surgery due to the increasing severe injuries frequency, due to an increase in the number of road accidents, local military conflicts, emergencies, oncological lesions of bone tissue, congenital pathologies of the musculoskeletal system. When replacing extensive bone defects larger than 8-10 cm, with an open wound, there is a high complications possibility due to the fact that the post-traumatic defects treatment of long bones sometimes proceeds with soft tissues inflammation and even with the transition to bones osteomyelitis [1; 2]. The restoration of the required femur length is hampered by anatomical features.

The treatment complexity and patients' rehabilitation with an open comminuted femoral fracture, with an extensive bone defect, is due to an increased risk combination of developing infectious complications due to the wound openness, with the need to restore a significant volume of bone tissue, for the connection of the proximal and distal fragments of the femur.

Open extramedullary or intramedullary osteosynthesis of bone fragments using metal implants is impossible in such cases due to the lack of the required bone tissue volume necessary to restore the bone normal length. In open reduction cases, immediately after injury, there is a high probability of developing soft tissue necrosis, infectious complications, inflammatory and purulent-septic processes, as the negative effect result of early reduction on the blood supply of an already severely damaged limb. Difficulties arise with maintaining the limb length.

In disturbances conditions in the hemocirculation, lymph drainage and osteogenesis processes, the nonunions frequency increases, false joints formation of the femur is, which in patients with significant bone tissue defects reaches 39.6-55.7% [3].

According to the available data, at the current technology level, osteomyelitis as an open fractures consequence develops in 5.3-75.4% cases, as a gunshot fractures consequence in 34.2-82.3% and as a planned orthopedic and traumatological operations consequence in 1, 5-33.2% cases [4]. At the same time, the patients' treatment with chronic osteomyelitis remains a difficult task until now, with a high percentage of unsatisfactory outcomes, from 22 to 65% cases.

In addition to infection with traumatic injuries of long bones, nonunions, false joints are often formed. The frequency of nonunited fractures and pseudoarthrosis in traumatic injuries of the long bones of the extremities reaches 27% [5].

Modern traumatology and orthopedics has huge arsenal methods for replacing extensive post-traumatic defects in long bone tissue. Currently, four areas can be distinguished: free transplantation of bone tissue and bones, the defect replacement with bone-substituting and osteoinductive materials, non-free bone tissue transplant according to G.A. Ilizarov and

combined methods [6]. Non-free bone grafting according to G.A. Ilizarov and vascularized replantation or free autograft into a defect [7] and various types of free bone auto- and alloplasty [8] can be considered relatively effective. As prosthesis, autografts can be used, which perform a bioprosthesis function, as well as artificial prostheses, implants with biocompatibility and a strength sufficient level. Autobone is an osteogenous, osteoconductive and osteoinductive plastic material [9], but autobone harvesting is associated with additional, sometimes significant trauma and blood loss, and a lack of available plastic material.

The purpose: a successful treatment case demonstration of a patient with an open fracture of the femur with an extensive defect in bone tissue, while maintaining the limb length, using a spoke-rod device with an extensive defect in bone tissue, replaced using the fibula.

2. MATERIALS AND METHODS.

Patient born in 1983 07/01/2015 received concomitant mechanical injuries as a result of an accident. In the acute trauma period, the patient received first aid, aseptic dressings were applied, the injuries sites were immobilized, and anti-tetanus serum was administered. In the post-shock period, the patient's condition was stabilized, for 12 days; complex treatment was carried out in the CDH.

In 2015.07.13 the patient was admitted to the traumatology and orthopedics department of the medical center, in Samarkand. Diagnosis: Closed craniocerebral injury (CCCI). Brain concussion. An open comminuted fracture of the femur, with an extensive defect in the bone tissue of the diaphysis in the middle-lower third. Type II is according to the classification of open fractures according to Gustilio-Anderson [10]. A diagnostic radiograph of the left femur was performed, anteroposterior and lateral projections (Fig. 1).

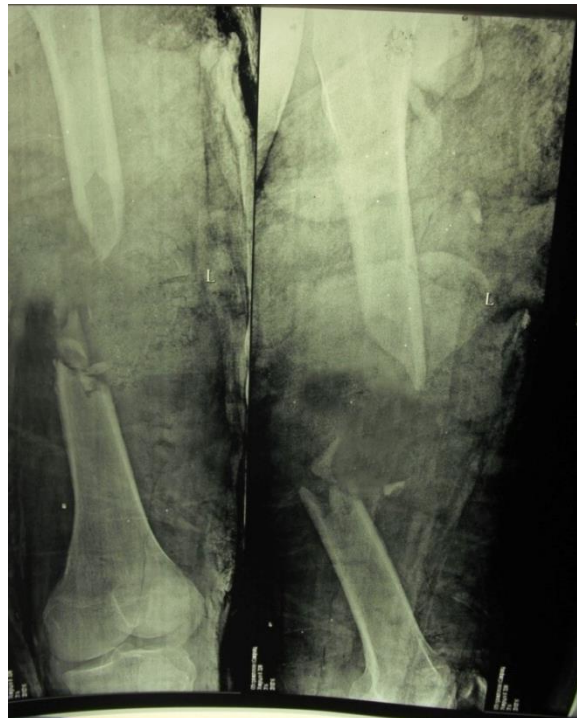

Figure: 1.13.07.2015y. Patient was born in 1983. diagnostic radiograph of the left femur.

Before the operation, it was performed a bacteriological study, antibiotic therapy, blood biochemistry were performed, and preoperative preparation.

Surgical treatment of a femoral fracture was performed. Under spinal anesthesia, an incision was made along the lateral surface of the thigh in the middle and lower thirds. It was found a defect in the diaphysis bone tissue with 11 cm length of the femur and multiple fragments of the femur (Fig. 1). To take the autograft under spinal anesthesia, an incision was made along the lateral surface of the left leg. The fibula is exposed in a blunt way, protecting the vessels and muscles. The autograft was isolated by minimally invasive osteotomy; transverse canals were sequentially drilled in the fibula along the osteotomy line. The autograft length was determined depending on the defect longitudinal size (length) in the femur diaphysis, taking into account the need to form two longitudinal autografts, a fibula with 22 cm length was isolated. The need for a paired autograft is due to a discrepancy between the cross-sectional area of the femur and the fibula. During the autograft collection, the periosteum and muscle segments attached to the fibula shaft were preserved. We believe that the preserved periosteum and segments of the muscles attached to the autograft contribute to the improvement and restoration of the graft nutrition, improve new bone tissue formation and vascularization process.

On the femur, the seat mechanical treatment for the autograft was carried out. The surfaces of the femoral bone fragments in contact with the autograft were cleaned. To replace the femur defect, a paired autograft was formed, dividing the taken the fibula fragment into two fragments 11 cm long each. Autografts were installed at the femoral diaphysis defect site. Before installing the autograft, the medullary canal was partially reamed and cleaned in the femur fragments. The autograft was mechanically processed by adjusting the geometric shape of the ends for contact with the femur fragments, shaped to ensure placement in the medullary canal. After the autograft was installed, the bone position was fixed and compression was created with an external fixation device, providing osseointegration. A spoke-rod apparatus was used containing rings, with four rods-screws and four needles. Intraoperative radiography of the left thigh was performed (Fig. 2). The wound was sutured in layers with drainage.

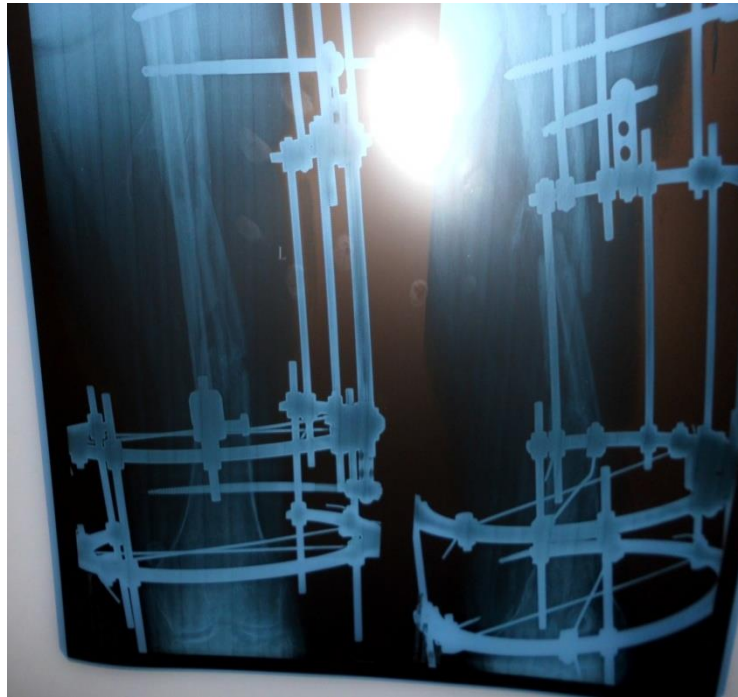

Fig. 2. 21.07.2015y. Patient was born in 1983. Radiograph of the left femur, after surgery, anteroposterior and lateral views.

In the stationary period, the patient underwent detoxification, antibacterial and restorative therapy, antiplatelet agents, antispasmodics, anticoagulants, as well as local treatment of wounds after surgery. The patient was activated on the 5th day and was under observation. 6 weeks after the operation, a course of early functional loading was started by passive movements of the knee and hip joints with a gradual increase in the range of motion in the adjacent joints. Fixation with the apparatus was carried out for 12 months with supportive compression. Then the device was dismantled.

3. RESULTS AND DISCUSSION.

Replacement of the femoral shaft defect is carried out by the patient's own tissues from the fibula. At the same time, the lack of a safety autograft margin is compensated by installing a pair of fibula fragments.

12 months after the operation, the control X-ray (Fig. 3) showed restoration of the femur integrity, autograft fusion with the femur fragments. The patient is able to use the limb with full load.

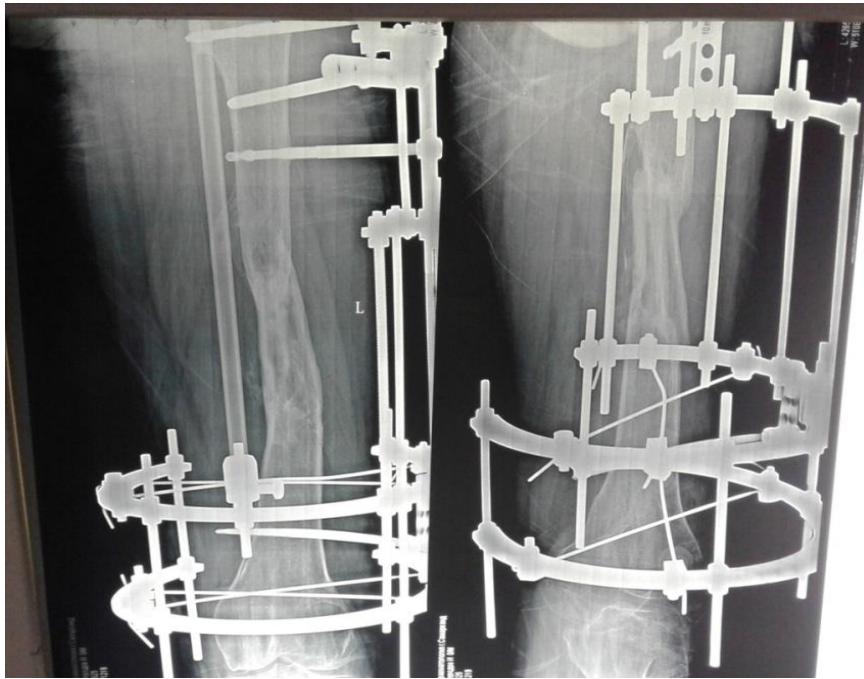


Figure: 3.A patient. Control X-ray of the left femur, 12 months after surgery.

The treatment used a combination of external fixation and bone grafting.

There is no single standard definition of a critical size defect. Defects can be assessed in both relative and absolute terms and can vary. In general, a “critical size” defect is considered a defect that does not heal spontaneously despite surgical stabilization and requires further surgical intervention [11].

Achieved union of free paired each autografts 11 cm long, from the side of the central and peripheral fragments of the femur. The defect was filled; the thigh length, shape, and support function of the limb were restored.

4. CONCLUSIONS.

The combination of external fixation and autotransplantation made it possible to completely restore the injured limb, reduce the risk of complications, and obtain a good clinical result. The limb function was restored satisfactorily, the anatomical segment length was preserved, all fixation structures were removed, and the limb did not contain foreign bodies. The treatments combination in this case was simple and effective in treating the patient.

5. REFERENCES

- [1] A. V. Bondarenko Primary osteosynthesis according to Ilizarov is the main factor in the prevention and relief of purulent complications in open fractures /A.V. Bondarenko, S.A. Pechenin // Genius of Orthopedics. - 2004. - No.4. - p. 30-36.
- [2] Djunusov E.T. Outcomes of treatment of patients with open fractures of long bones / E.T. Zhunusov // The genius of orthopedics. - 2005. - No. 3. - p. 15-19. (keywords: extraosseous and perosseous osteosynthesis, Ilizarov apparatus)

- [3] Nikitin G.D., Rak A.V., Linnik S.A., Nikolaev V.F., Nikitin D.G. Bone and musculoskeletal grafting in the treatment of chronic osteomyelitis and purulent false joints. SPb., 2002.192 p.
- [4] N.M. Klyushin. Ilizarov method in purulent osteology. Kurgan. 2019.-7-9 pages.
- [5] Tashpulatov A.G., Isroilov R., Yakhshimuratov K.Kh. Morphological assessment of reactive tissue regeneration in the area of pseudoarthrosis and long bone defects in conditions of purulent infection//Genius of Orthopedics. 2010. No4. P.51-54.
- [6] Shastov A. L., Kononovich N. A., Gorbach E. N. The problem of replacing post-traumatic long bone defects in domestic traumatological and orthopedic practice. Genius of Orthopedics. 2018.Vol. 24. No. 2.P.252-257.
- [7] Shevsov V.I., Borzunov D.Yu. Rehabilitation of patients with defects and false joints of long bones, the current state of the problem // Genius of Orthopedics. 2008.No. 4.p.48-54.
- [8] Nikolenko V.K., Babich M.I., Gritsyuk A.A., Brizkhan L.K., Lukomsky M.I. Treatment of gunshot defects in the long bones of the lower extremities // Priorov Bulletin of Traumatology and Orthopedics. 2007.No.2.P.64-70.
- [9] Finkemeier C.G. Bone-Grafting and Bone-Graft Substitues // J.Bone. Joint Surg. Am.-2002.- 84.- P.454-464.
- [10] Paul H. Kim MD, Seth S. Leopold MD. Gustilo-Anderson Classification. ClinOrthopRelat Res(2012) 470: 3270-3274.
- [11] Keating JF, Simpson AH, Robinson CM.The management of fractures with bone loss. J Bone Joint Surg Br.2005;87:142-150.